



Microvascular Decompression for Trigeminal Neuralgia

Last Updated: June 22, 2021

Microvascular Decompression Surgery for Trigeminal Neuralgia: Classical Intraoperative Findings

Trigeminal neuralgia is considered one of the worst pains that can affect a human being. The severity of this disabling pain and its relief through successful operative intervention have caused microvascular decompression (MVD) surgery to be recognized as one of the most satisfying operations in neurosurgery.

The typical pain of trigeminal neuralgia is relatively easy to diagnose. **The character of the pain is typically unilateral, episodic, severe, stabbing, shock-like, or lancinating, and exacerbated by cutaneous stimuli such as tactile pressure, chewing, brushing, a breeze of air, or shaving.** At first, it is often mistaken as a tooth problem because of its presentation in the two lower branches of the trigeminal nerve. Patients may undergo unnecessary, and sometimes irreversible, dental treatment before the correct diagnosis is made.

A crude annual incidence of trigeminal neuralgia is approximately 5.7 per 100 000 women and 2.5 per 100 000 men. Peak incidence lies in people between ages 50 and 60 years, with prevalence increasing with age. Initially, a small dose of an antiepileptic/antineuralgic drug (such as carbamazepine), rather than an analgesic drug, can provide excellent pain relief. However, up to 10% of patients will not respond to these drugs and will still qualify as candidates for MVD surgery if no other underlying etiology is found.

History

In 1773, John Fothergill was the first to fully describe trigeminal neuralgia in an article presented to the Medical Society of London titled *On a Painful Affliction of the Face*. In 1829, Charles Bell distinguished the specific functions of the trigeminal and facial nerves and introduced the idea that the paroxysmal pain in trigeminal neuralgia is directly related to nerve dysfunction.

In 1934, Walter Dandy, who routinely used a lateral suboccipital craniectomy (or “cerebellar approach”) to perform retrogasserian trigeminal neurectomies for treatment of trigeminal neuralgia, made the seminal observation that in many patients who suffer from this pain, the nerve is compressed by an overlying blood vessel. Later, in 1967, Peter Jannetta popularized the MVD procedure for trigeminal neuralgia.

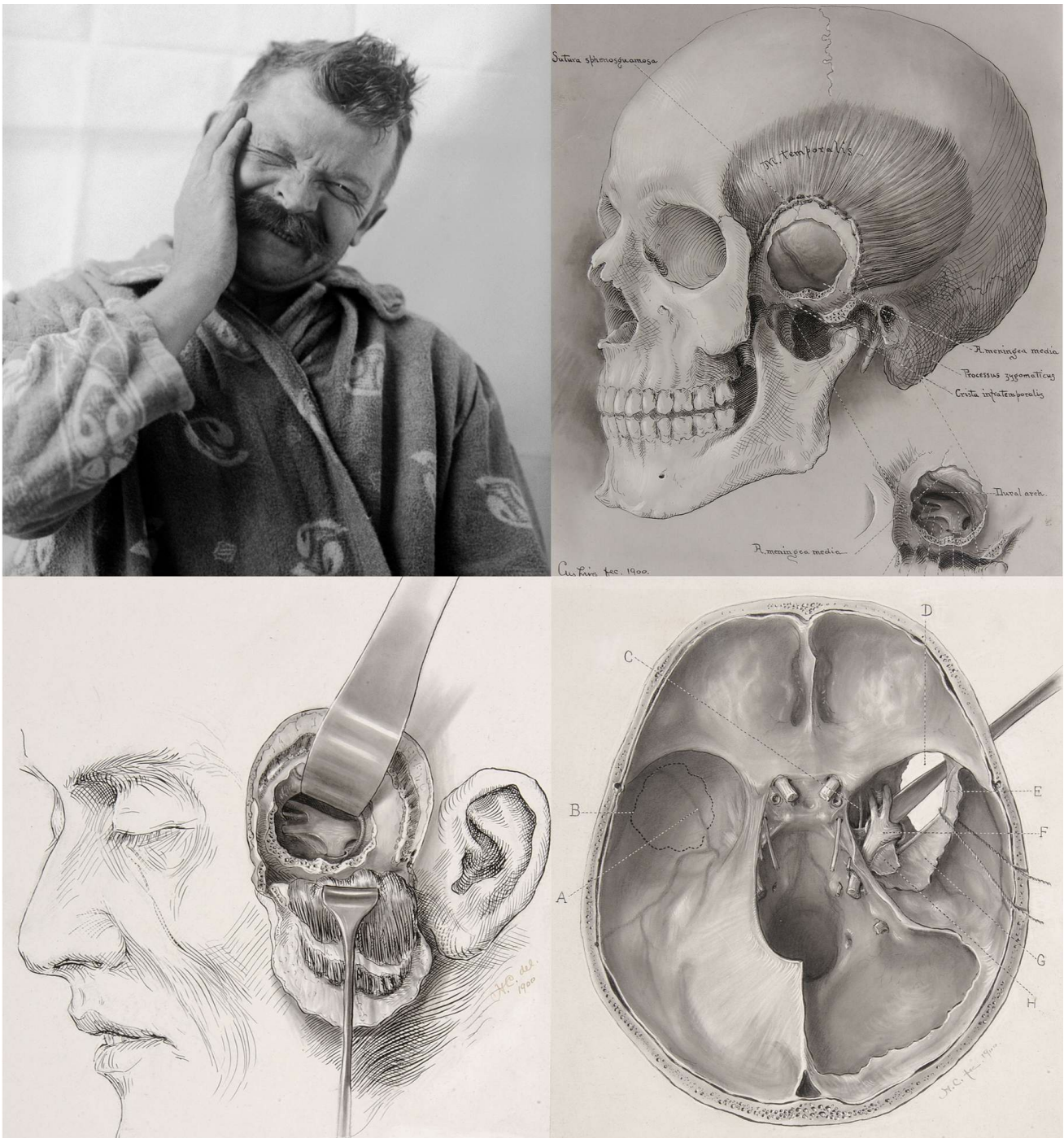


Figure 1: One of the first patients of Harvey Cushing suffering from an attack of trigeminal neuralgia. This image is most likely one of the earliest photographs of a patient with this disease (top image). Cushing's original sketches demonstrate his technique of subtemporal sensory nerve avulsion (middle and bottom images)(Courtesy of Cushing Center at Yale University).

Pathogenesis

The pathogenesis of cranial nerve hyperactivity syndromes, such as trigeminal neuralgia, hemifacial spasm, geniculate neuralgia, paroxysmal positional vertigo, and glossopharyngeal neuralgia, has remained elusive.

Vascular compression of the respective nerves at the brainstem (neurovascular conflict-peripheral hypothesis) has been proposed as the principal factor involved in the genesis of cranial nerve hyperactivity through demyelination of the root entry/exit zone of the nerve (ephaptic transmission).

However, in some patients, no compressive artery can be found during detailed exploratory posterior fossa surgery. **In addition, cadaveric studies have revealed an intimate relationship between the cranial nerves in the posterior fossa and the neighboring vessels, but these cadavers had no history of cranial hyperactivity syndrome before their death.** Recently, investigators have implicated other factors (central hypothesis: hyperactivity of the trigeminal and facial nuclei), in addition to peripheral vascular conflict, as causes for the disorder.

The offending vessel is most often the superior cerebellar artery (75%) or the anterior inferior cerebellar artery (10%). In addition, a vein may contribute to the compression (68%), and sometimes it is the only compressing vessel (12%). Because of the lamination pattern of fibers within the nerve root, medial compression tends to cause V2 (the maxillary division) symptoms. Lateral or caudal compression may cause V3 (mandibular division) symptoms, and rarely, cranial compression causes V1 (ophthalmic division) symptoms.

Regardless of the responsible etiology in the pathogenesis of this pain, MVD surgery, through mobilizing the offending vessel or performing a rhizotomy, provides an effective and durable palliative option for symptomatic relief. Although percutaneous procedures offer a less invasive route to the Gasserian ganglion for rhizotomy, **posterior fossa exploration offers the only opportunity to identify an offending vessel through a nondestructive procedure with a more lasting result.**

The patient's age and medical comorbidities are important factors that can limit the application of an MVD operation. **I offer MVD surgery to my patients who are younger than 70 years and who have no prohibitive medical comorbidities, if their pain is consistent with trigeminal neuralgia.**

In this chapter, I describe the details and key steps in maximizing safety and efficiency while minimizing complications during MVD operations for trigeminal neuralgia. My technique has evolved from a combination of pearls from multiple schools of neurosurgical teaching.

Diagnosis and Evaluation

The diagnosis of trigeminal neuralgia is based nearly entirely on the patient's history. As mentioned above, *the character of the pain in trigeminal neuralgia is typically unilateral, episodic, severe, stabbing, shock-like or lancinating, and exacerbated by cutaneous stimuli such as tactile pressure, chewing, brushing, a breeze of air, or shaving.* This character is considered neuralgic in contrast to neuropathic pain: A burning pain associated with numbness.

Periods of remission tend to get shorter over time and attacks of pain often get longer. Patients may have as few as three to four or as many as 70 attacks per day. There is often a refractory period when the pain cannot be triggered. Pain occurs at night in a third of patients. It is unusual to have neuralgia only in the first ophthalmic division of the trigeminal nerve.

A positive response to neuropathic pain medications, such as carbamazepine or gabapentin, often supports the diagnosis of typical trigeminal neuralgia and potentially predicts a good outcome for MVD surgery. **The character of the pain may change with the use of neuropathic pain medications or previous percutaneous procedures, and the pain may become more constant.** Therefore, *the clinician should inquire about the character of the pain at its inception* before any treatment was rendered.

Patients with burning pain, facial numbness, or (only) constant pain without triggering stimuli are suffering from atypical or neuropathic pain, not neuralgic facial pain. They are not ideal candidates for a posterior fossa exploratory operation. It is important to carefully examine the face and oral cavity along with the cranial nerves. A detailed neurologic examination of these patients is usually unremarkable; minor sensory

changes in the corresponding distribution of the trigeminal nerve are not uncommon and not a contraindication for considering MVD surgery.

All patients who are planning to undergo an MVD operation should have brain magnetic resonance imaging (MRI) or a computed tomography (CT) scan to exclude structural pathologies such as a meningioma, acoustic neuroma, and epidermoid tumors. On high-resolution T2W imaging, a vascular loop is often evident compressing the trigeminal nerve.

Even if a high-resolution MRI does not identify an offending vascular loop, the consideration for a posterior fossa exploration is appropriate if the patient's pain is consistent with typical trigeminal neuralgia. I have routinely offered MVD to patients who do not harbor an "MRI evident" vascular loop, and I have often found compressive arterial loops during their surgery with desirable operative results.

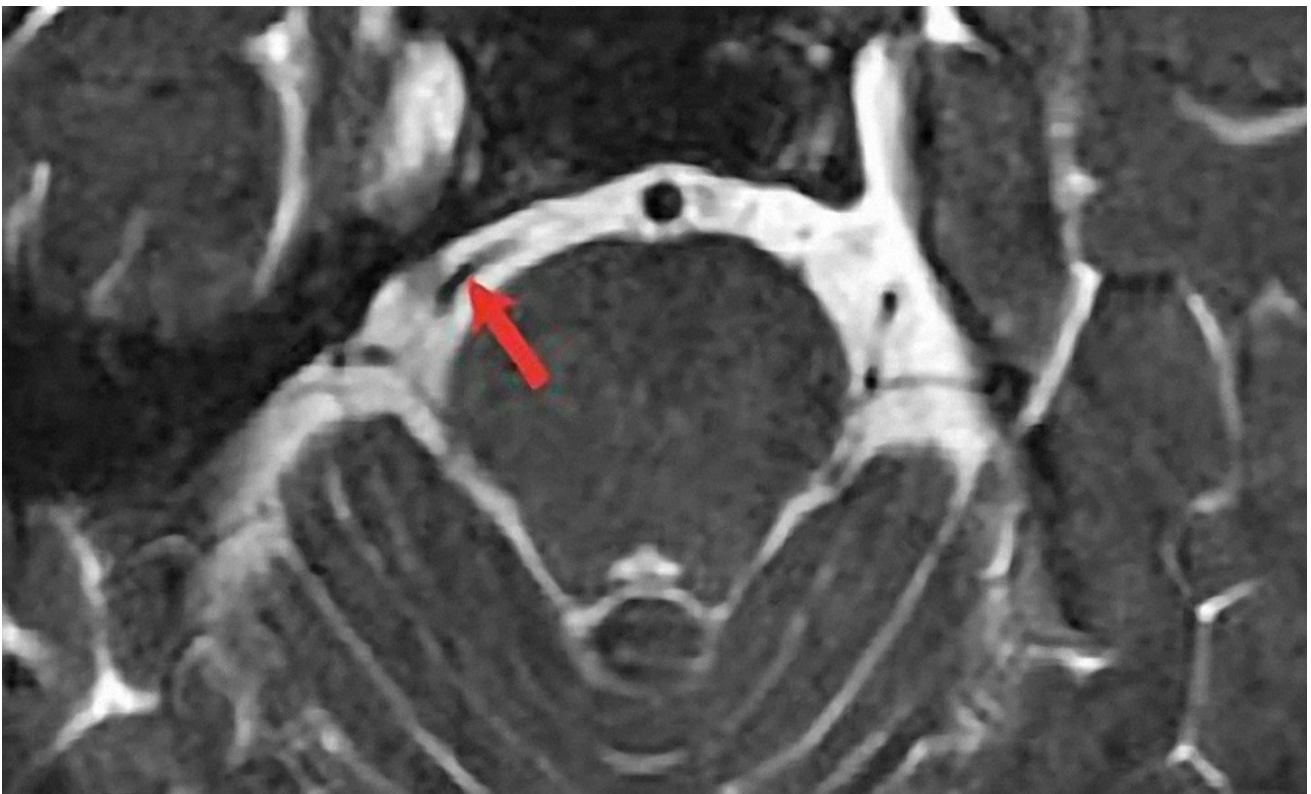


Figure 2: An axial T2W MRI demonstrates a vascular loop (red arrow) causing compression of the right trigeminal nerve at its cisternal segment.

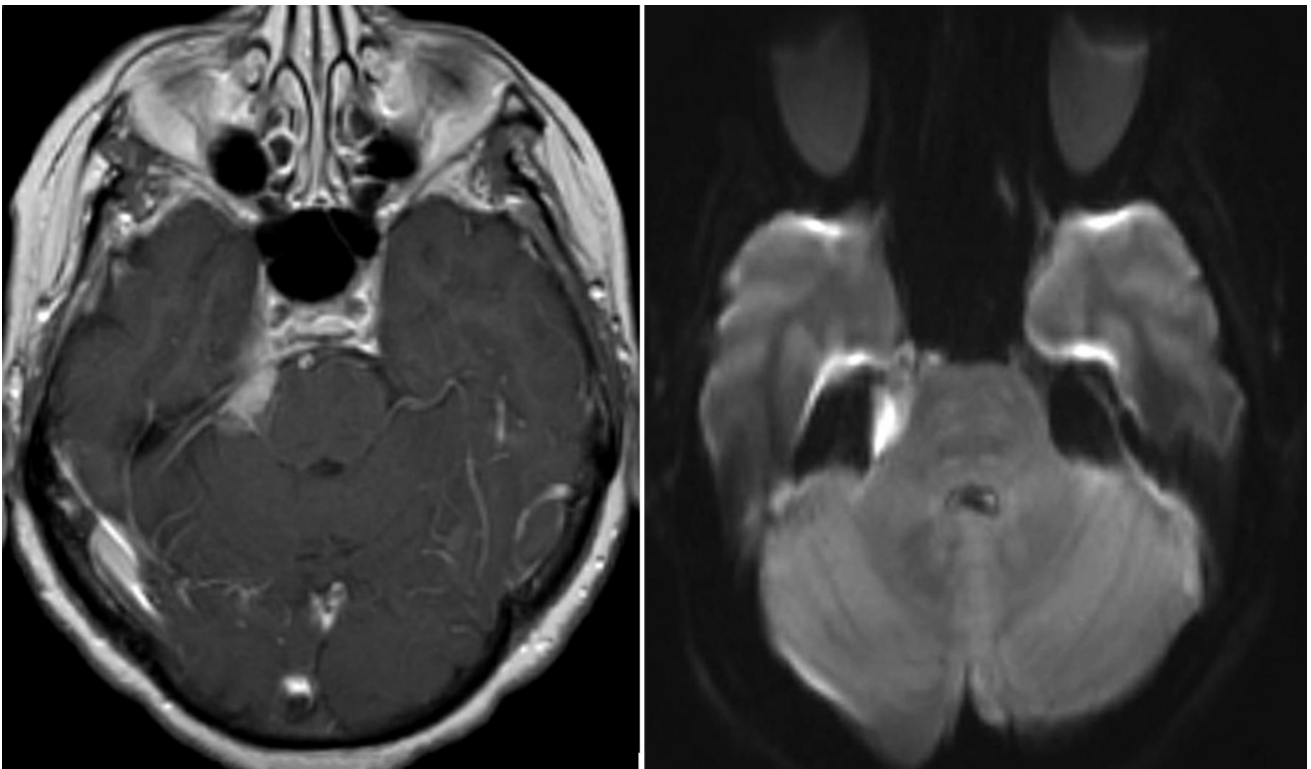


Figure 3: A small right tentorial meningioma (left image) and CP angle epidermoid (right image-diffusion) causing TN. Both patients underwent resection.

Differential Diagnosis

There is an extensive differential diagnosis for facial pain, and several elements from the patient's history and examination are critical to confirming the diagnosis of trigeminal neuralgia.

Dental pathologies, temporomandibular joint pain, eye pain (including glaucoma, orbital cellulitis, and trauma), facial trauma and bony fractures, tumor of the facial bones or the trigeminal nerve, giant cell arteritis, Tolosa-Hunt syndrome (idiopathic inflammation in or around the cavernous sinus), trigeminal autonomic cephalgias (such as cluster headache and paroxysmal hemicrania) and other primary headache syndromes (including migraine and tension-type headache) can cause facial pain and are not amenable to MVD. Other cranial nerve hyperactivity disorders such as glossopharyngeal neuralgia and nervus intermedius neuralgia rarely co-exist with trigeminal neuralgia.

Structural pathologies such as tumors or cysts of the cerebellopontine angle, and demyelination or ischemic lesions of the brainstem should also

be considered in the differential diagnosis.

Secondary causes of trigeminal neuralgia should be sought if any of the following red flags are present: significant sensory changes, deafness or other ear problems, difficulty achieving pain control, poor response to carbamazepine therapy, history of skin lesions or oral lesions that could lead to perineural spread, isolated ophthalmic trigeminal neuralgia, or bilateral trigeminal neuralgia. These manifestations are suggestive of benign and malignant lesions or multiple sclerosis.

Importantly, I question the diagnosis of typical trigeminal neuralgia in patients younger than <40 years. These patients should undergo a careful investigation to exclude other underlying causes for their pain including multiple sclerosis. Furthermore, bilateral trigeminal neuralgia and a history of sinus trauma or surgery should alarm the surgeon regarding the suitability of offering MVD to the patient.

Medical Therapy

The preferred drug for medical treatment of trigeminal neuralgia is carbamazepine, an anticonvulsant medication. It initially provides 100% pain relief for 70% of patients. However, many patients have side effects to this drug, mainly affecting the central nervous system—such as fatigue and poor concentration—and there is a high risk of drug interactions.

The second drug of choice is oxcarbazepine, a keto derivative of carbamazepine that has shown similar efficacy as carbamazepine, but better tolerability and fewer drug interactions. If a patient develops an allergy to these drugs, international recommendations suggest the use of baclofen and lamotrigine.

Indications for Surgery

Despite the use of neuropathic pain medications, some patients' pain becomes refractory and they seek more durable surgical treatment. Acute facial pain is not amenable to MVD, and, in my opinion, the patient's symptoms should at least last 1 year with aggressive medical intervention before surgery is considered. This philosophy is justified since the pain

may be short-lived in some patients. Indications for surgery include, but are not limited to, failure of or adverse side effects from medical treatment.

Patients older than 70 years or with associated prohibitive medical morbidity should seek less invasive percutaneous procedures such as Gasserian ganglion balloon compression, radiofrequency, or glycerol rhizotomy. Radiosurgery is also an option but the chance of pain freedom without medications is less. **Younger patients (<40 years) should be carefully evaluated before intervention because disappointing recurrence of pain in this group after any procedure is common.**

Atypical pain associated with burning neuropathic, rather than neuralgic pain, is not amenable to MVD surgery, and may actually worsen after surgery. Occasionally patients suffer from both trigeminal neuralgia and hemifacial spasm, known as *tic convulsif*.

Surgical Options

Surgical options for trigeminal neuralgia fall into two categories:

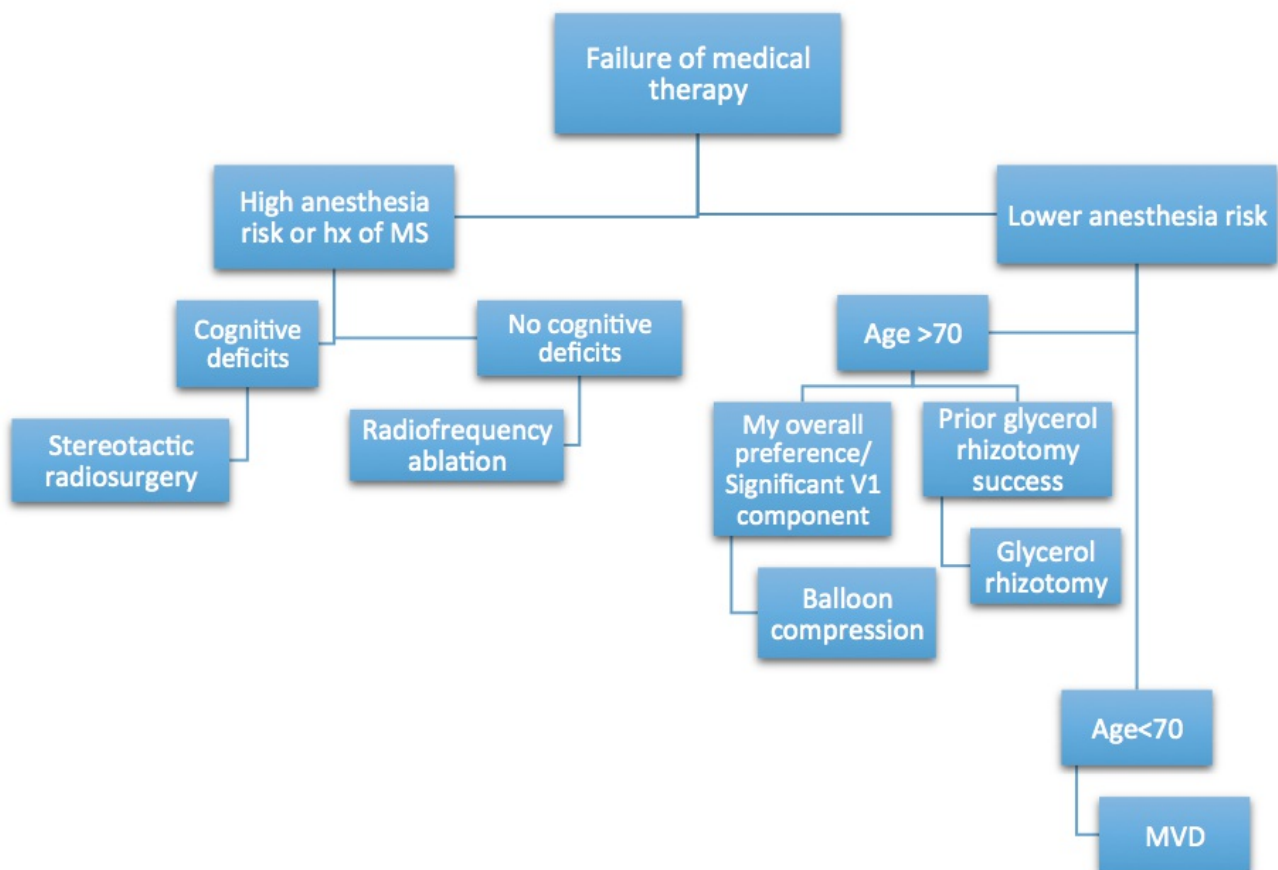
1. Palliative destructive procedures (one of three percutaneous procedures or radiosurgery), and
2. Physiologic nondestructive MVD

Palliative destructive procedures involve controlled damage to the trigeminal nerve root with the aim of pain relief. These procedures include *radiofrequency lesioning, glycerol rhizolysis, gasserian ganglion balloon compression rhizotomy, and stereotactic radiosurgery rhizotomy*. These palliative destructive procedures have a recurrence rate of about 50% after 3 to 5 years. In contrast, MVD surgery is associated with an approximately 80% chance of pain freedom among carefully selected patients. This effect lasts for more than 10-20 years with a recurrence rate of 10%.

For patients who cannot undergo an MVD operation, I generally prefer balloon compression rhizotomy because it is easy to perform and

immediately effective. If the patient harbors comorbidities that preclude the use of general anesthesia and immediate pain relief is not a concern, I offer radiosurgery as a reasonable option. Radiosurgery often does not offer an immediate pain relief and many patients continue to require neuralgic medications for their pain control.

I use the following algorithmic approach for selection of operative intervention.

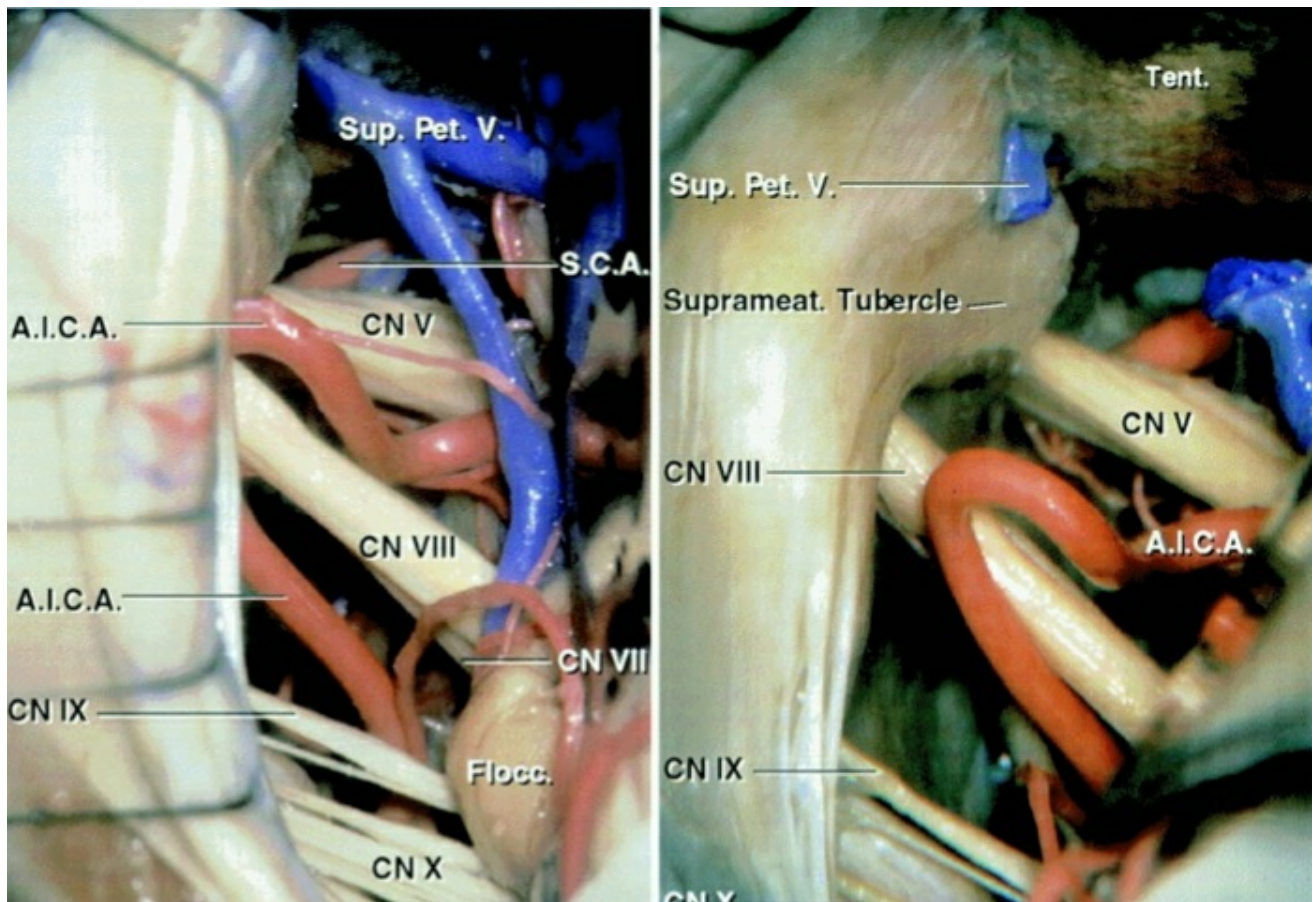


Preoperative Considerations

Neuralgic pain medications should be continued in the perioperative period and tapered off if the patient remains pain free for 1 week after surgery. I do not routinely monitor brainstem auditory evoked responses during MVD operations aimed at trigeminal neuralgia, but a novice surgeon may use this mode of monitoring during his or her early learning curve. Some patients may suffer from severe acute exacerbation of their trigeminal neuralgia (status trigeminus) and may require urgent surgery due to an inability to eat or drink.

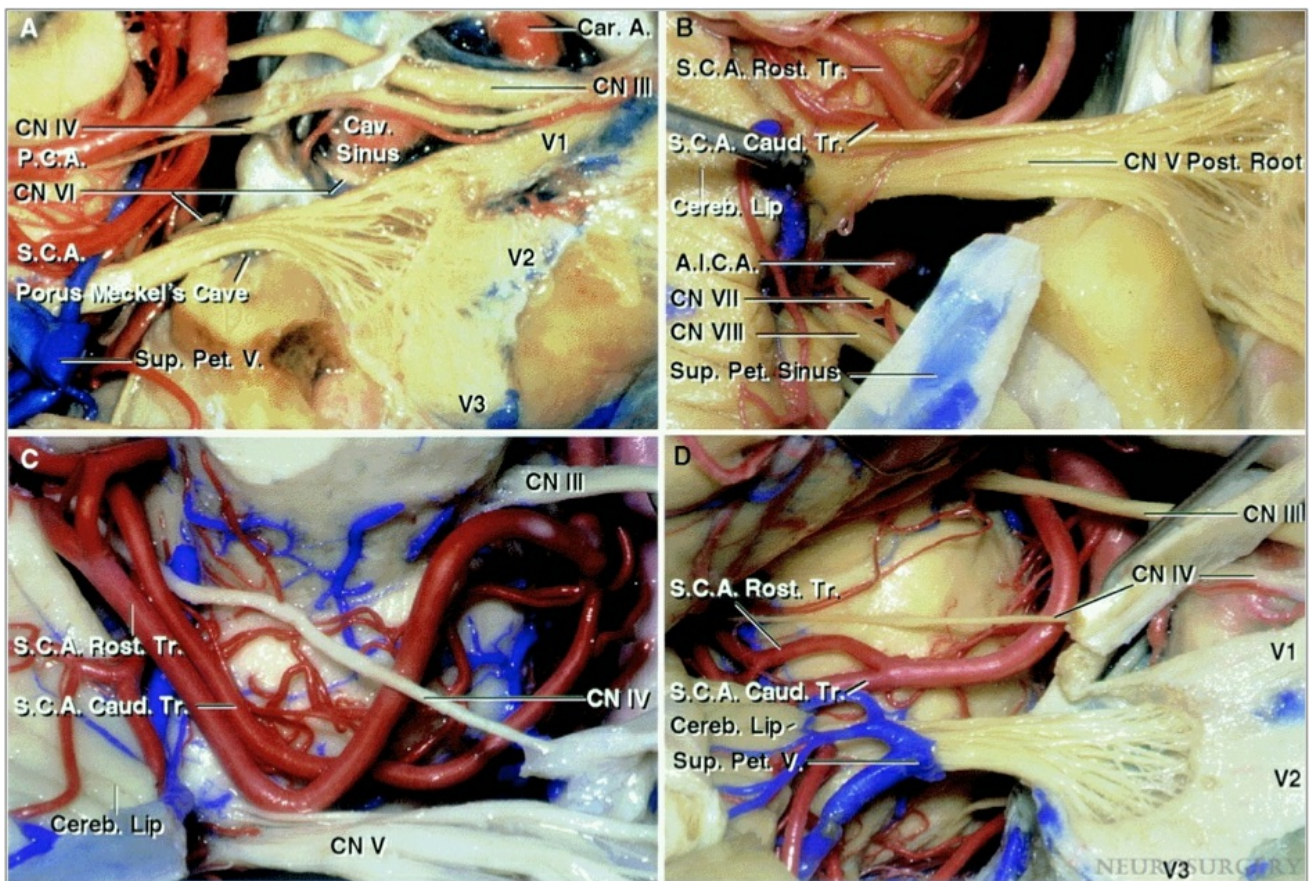
Operative Anatomy

The following images demonstrate the relevant operative anatomy.



[Click here](#) to view the interactive module and related content for this image.

Figure 4: Exposure of cerebrovascular structures within the left cerebellopontine angle through the retromastoid approach. Please note that CN V is deeper within the operative field and further away from the surgeon, whereas **the CN VII/VIII complex is more superficial and follows an oblique inferior to a superior trajectory.** This anatomical information should readily allow identification of these nerves (Images Courtesy of AL Rhoton, Jr).



[Click here](#) to view the interactive module and related content for this image.

Figure 5: Relationship between the trigeminal nerve and the superior cerebellar artery (S.C.A.). The posterior root enters the midpons below the S.C.A. (A). The S.C.A. loops downward and contacts the posterior trigeminal root at the pontine junction (B). The rostral trunk loops downward after early bifurcation and indents the upper surface of the trigeminal nerve (C). The S.C.A. bifurcates above and away from the trigeminal nerve (D)(Images Courtesy of AL Rhoton, Jr).

MVD for TRIGEMINAL NEURALGIA

The operative anatomy exposed during MVD surgery is pristine and pleasing to the surgeon. Neurovascular structures are microsurgically handled and preserved in a bloodless dissection field, and this surgery should be associated with minimal side effects. I routinely employ the **supralateral cerebellar approach** for MVD aimed at trigeminal neuralgia.

Please refer to the chapter on [extended retromastoid craniotomy](#) for a

detailed description of the approach to the root entry zone of CN V.

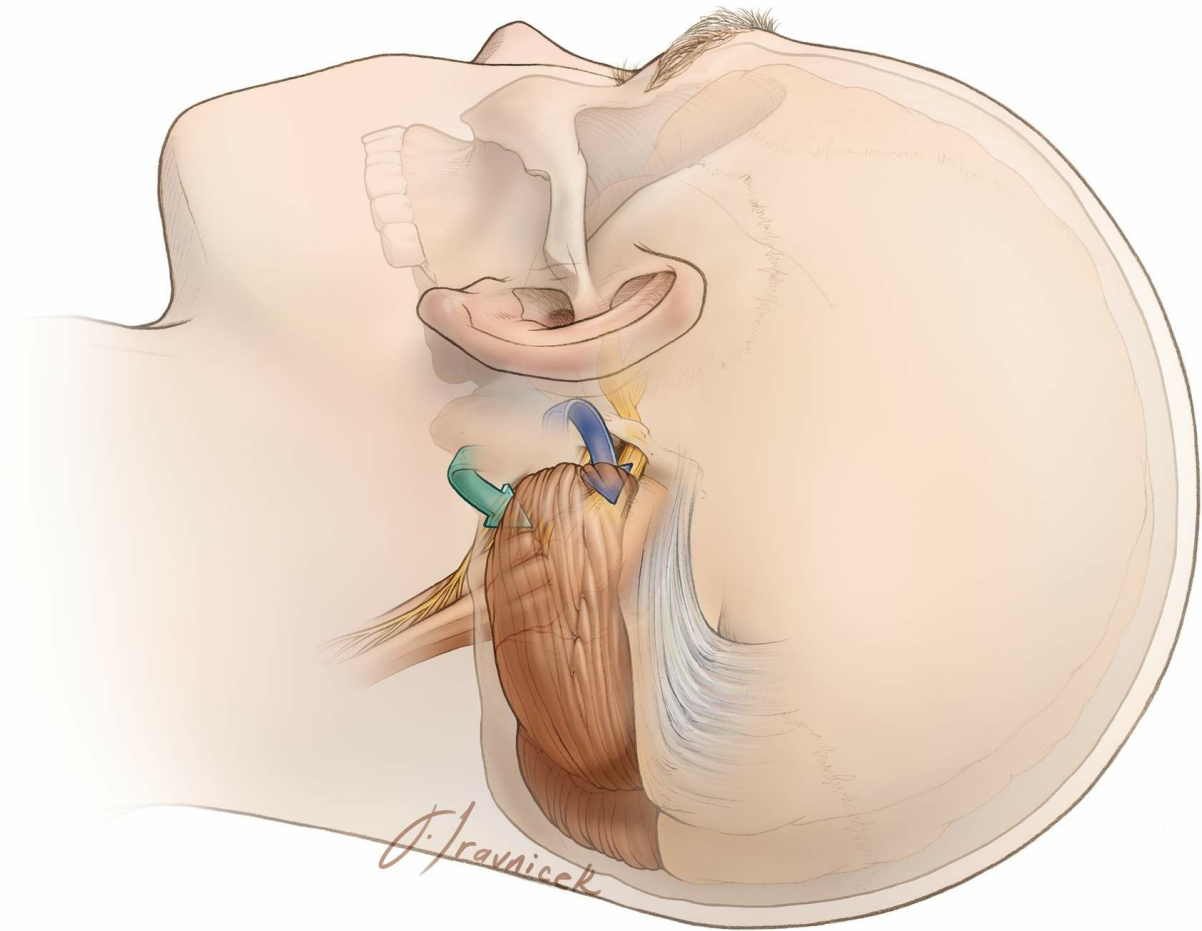


Figure 6: The operative corridors and trajectories for accessing the cerebellopontine angle: The surgical corridors for microvascular decompression for trigeminal neuralgia (supralateral cerebellar approach-blue arrow) and hemifacial spasm, and glossopharyngeal neuralgia (infralateral cerebellar or infrafloccular approach-green arrow) are illustrated. Mobilization of the cerebellum in a purely medial direction must be avoided since this vector of retraction will be parallel to the sensitive CN VIII, increasing the risk of hearing loss.

INTRADURAL PROCEDURE

The intradural microsurgery should be executed in a blood less manner.

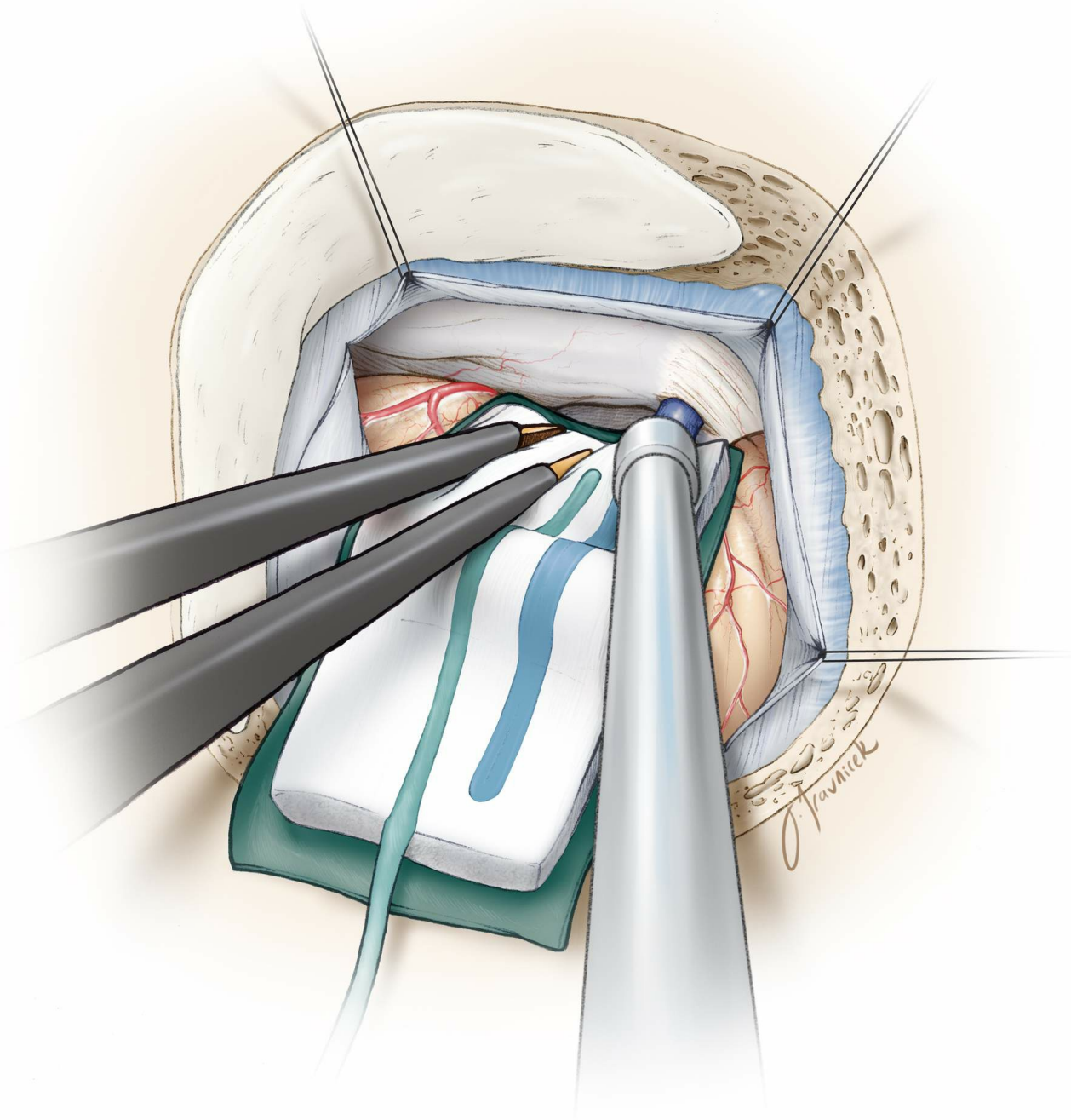


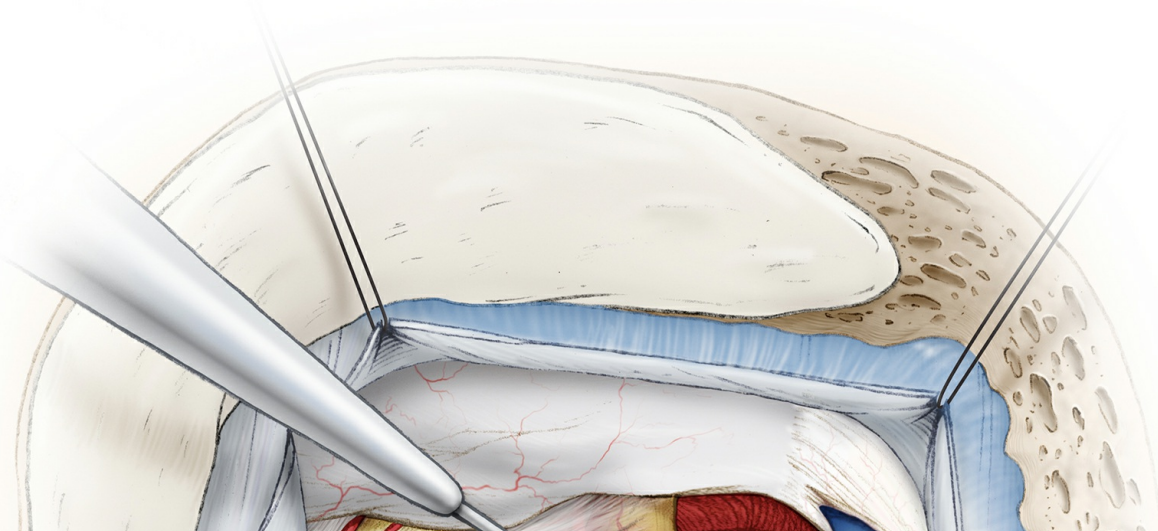
Figure 7: Inframedial cerebellar mobilization just below the petrous-tentorial junction

A piece of glove (cut slightly larger than the cottonoid) acts as a rubber dam and protects the cerebellar hemisphere from potential injury caused by friction from the cottonoid's surface. I advance the cottonoid parallel and just inferior to the junction (groove) of the tentorium and petrous apex, toward the petrous side. Identification of these landmarks prevents 1) the unintentional exposure (and resultant tear) of the supracerebellar bridging veins superiorly, and 2) placement of retraction directly against the CN VII/VIII complex inferiorly.

Gentle inferomedial retraction of the cerebellar hemisphere exposes the superior petrosal vein. The arachnoid membranes just inferior to the vein are sharply opened and additional cerebrospinal fluid (CSF) is released. However, the arachnoid membrane over the petrosal vein and CN VII/VIII are left intact to protect these structures.

Gentle dynamic retraction, using suction apparatus, is exerted over the lateral cerebellum just inferior to the superior petrosal vein, placing this vein under slight tension. Often this maneuver provides all the working space needed caudal to the vein. I exceedingly rarely need to sacrifice the superior petrosal vein. **Strategic placement of the suction apparatus will facilitate selective exposure of the necessary operative view and working angles at the level of CN V's root entry zone, obviating a need for fixed rigid retractors and the sacrifice of the superior petrosal vein.**

If I encounter bleeding from the superior petrosal vein, I coagulate the vein as far away from the dura and tentorium as possible and as close as possible to the cerebellar surface. This maneuver avoids retraction and avulsion of the vein from its pedicle at the dura due to its shrinkage by coagulation. If excessive venous bleeding occurs, the patient's head should be gently elevated; a sudden cessation of bleeding could be a sign of venous air embolism. A piece of Gelfoam covered by a piece of cottonoid supplemented with gentle pressure will control bleeding from an avulsed end of the superior petrosal sinus at the level of the tentorial-petrous junction.



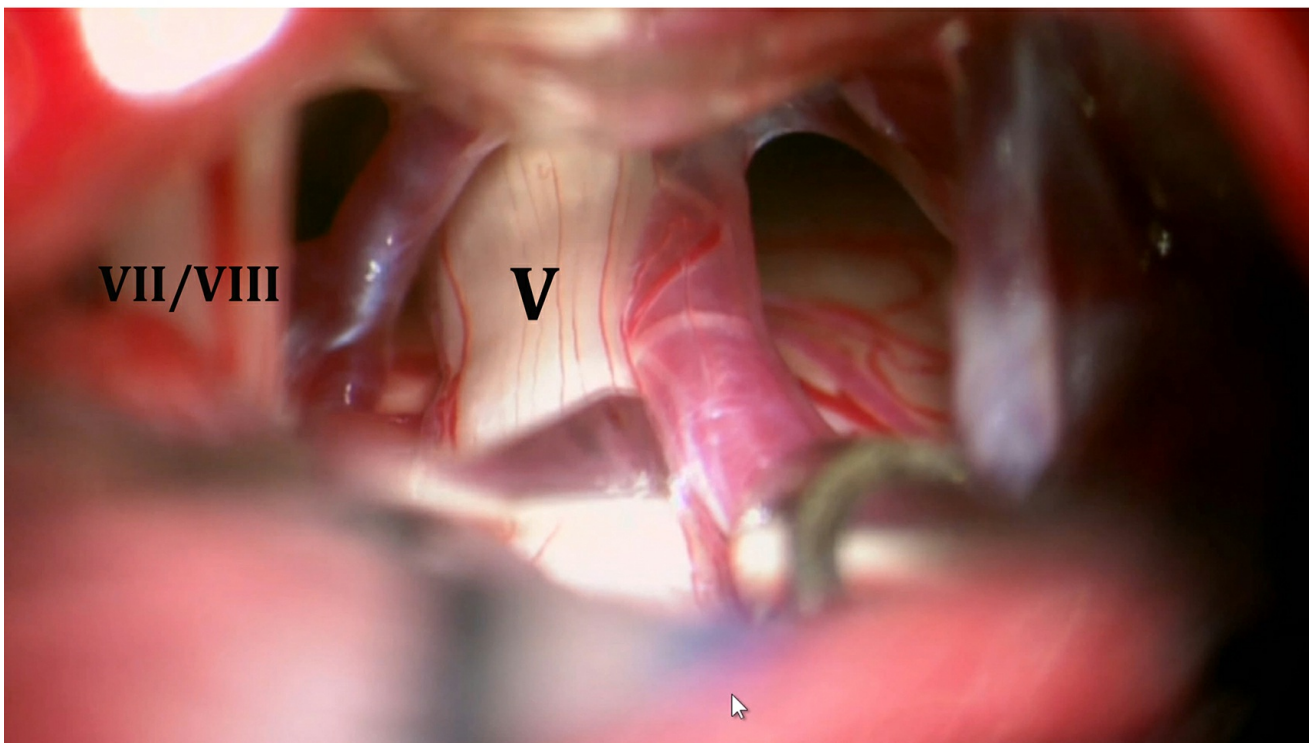
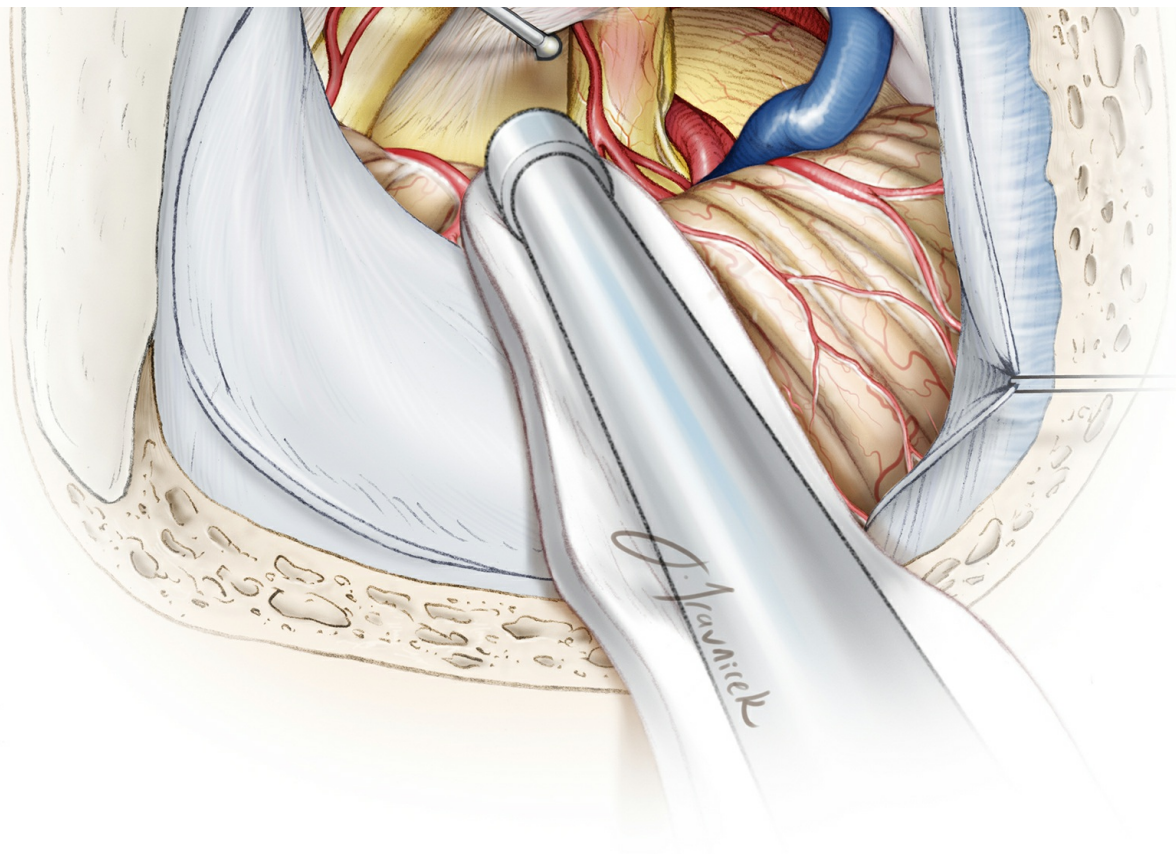


Figure 8: Careful arachnoid dissection and correct CN identification are paramount. Care must be taken to preserve all of the vessels around the brainstem. Deeper arachnoid membranes should be cut with caution and first dissected free of their entangled vessels with a fine ball-tip probe (top image). The trigeminal nerve is located deeper and more medial than the CN VII/VIII complex. *CN VII/VIII complex has a more superficial oblique*

inferior or superior trajectory and should not be mistaken for CN V (bottom image).

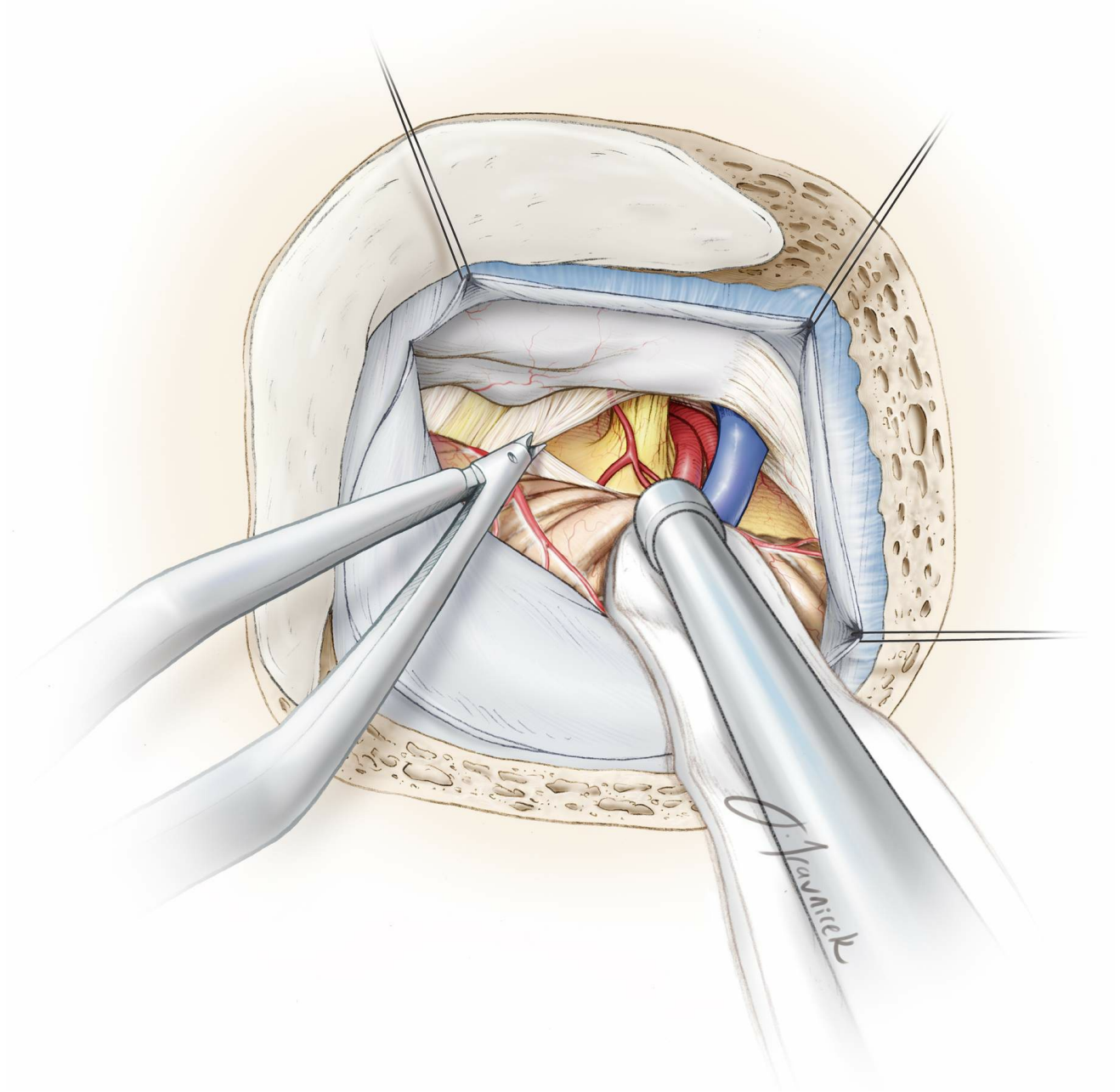


Figure 9: Careful sharp arachnoid dissection exposes the trigeminal nerve root entry zone.

The most common pattern of vascular compression by the superior cerebellar artery is along the superior shoulder of the root entry zone. The patterns of neurovascular conflict in the order of their incidence are illustrated in the following sketches:

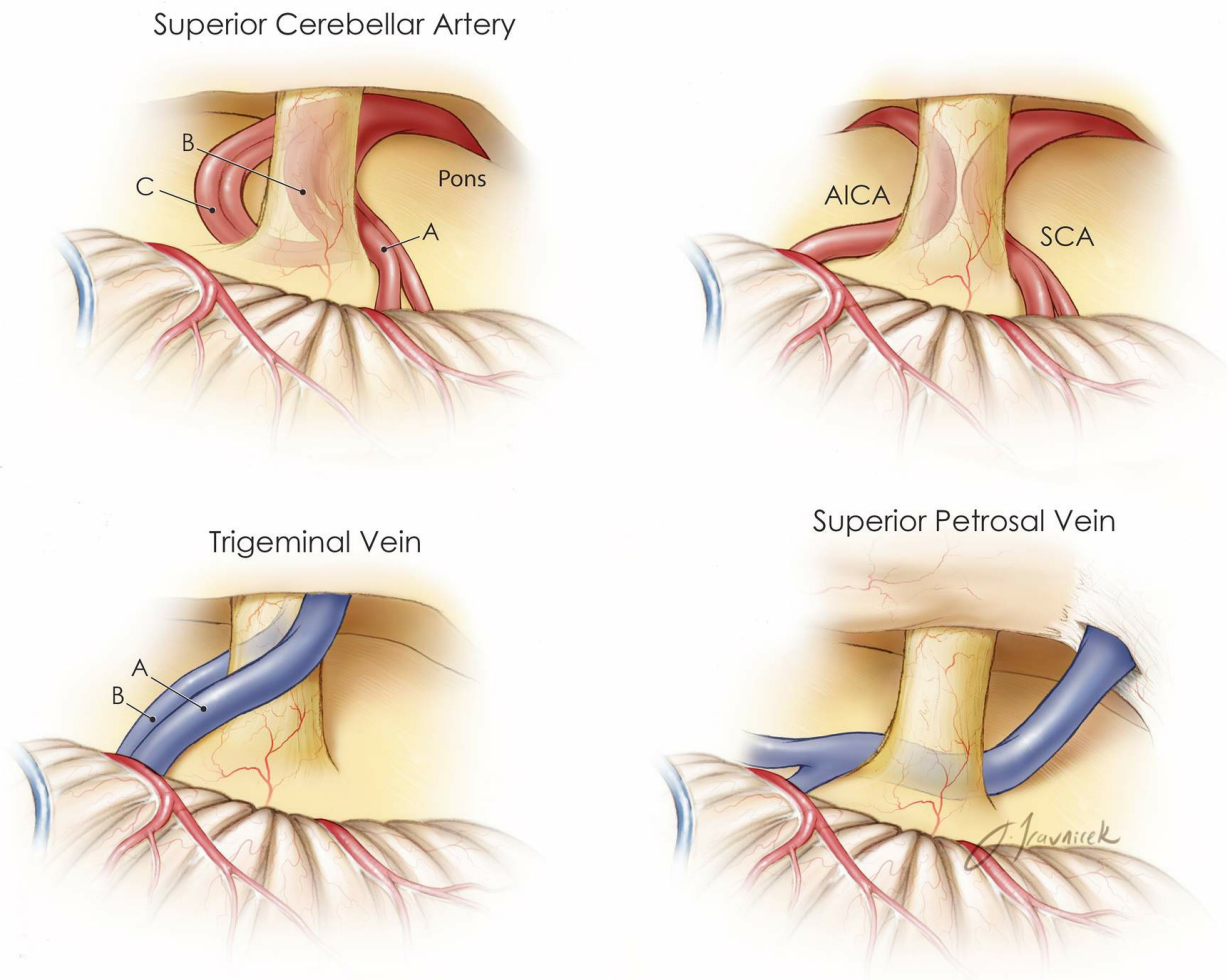


Figure 10: Variations of neurovascular conflict leading to trigeminal neuralgia: The nerve is compressed by the main trunk of the SCA (A) and its branches (B and C)(left upper); combined compression by the SCA and AICA (right upper). The nerve is sandwiched between the trigeminal (A) and petrosal (B) veins (left lower). The nerve is compressed by the superior petrosal vein (right lower). SCA: superior cerebellar artery, AICA: anterior inferior cerebellar artery.

The arachnoid membranes covering the region of neurovascular conflict are often thickened. **A lack of adequate visualization and inspection around these membranes may lead to inadequate decompression.** Therefore, wide careful opening of these membranes is paramount to allow circumferential visualization of any neurovascular conflict along the CN V entry zone.

The small working space along the shoulder of the nerve covered by the motor roots of CN V can prevent sufficient dissection and exposure,

leading to an incomplete decompression. Gentle mobilization of the nerve will allow a thorough circumferential inspection along the medial and anterior aspects of the root entry zone.

It is critical to emphasize that many patients have multiple offending vessels, and identification of one offending vessel does not preclude the search for another one. The root entry zone must be thoroughly and circumferentially inspected before placement of the implant.

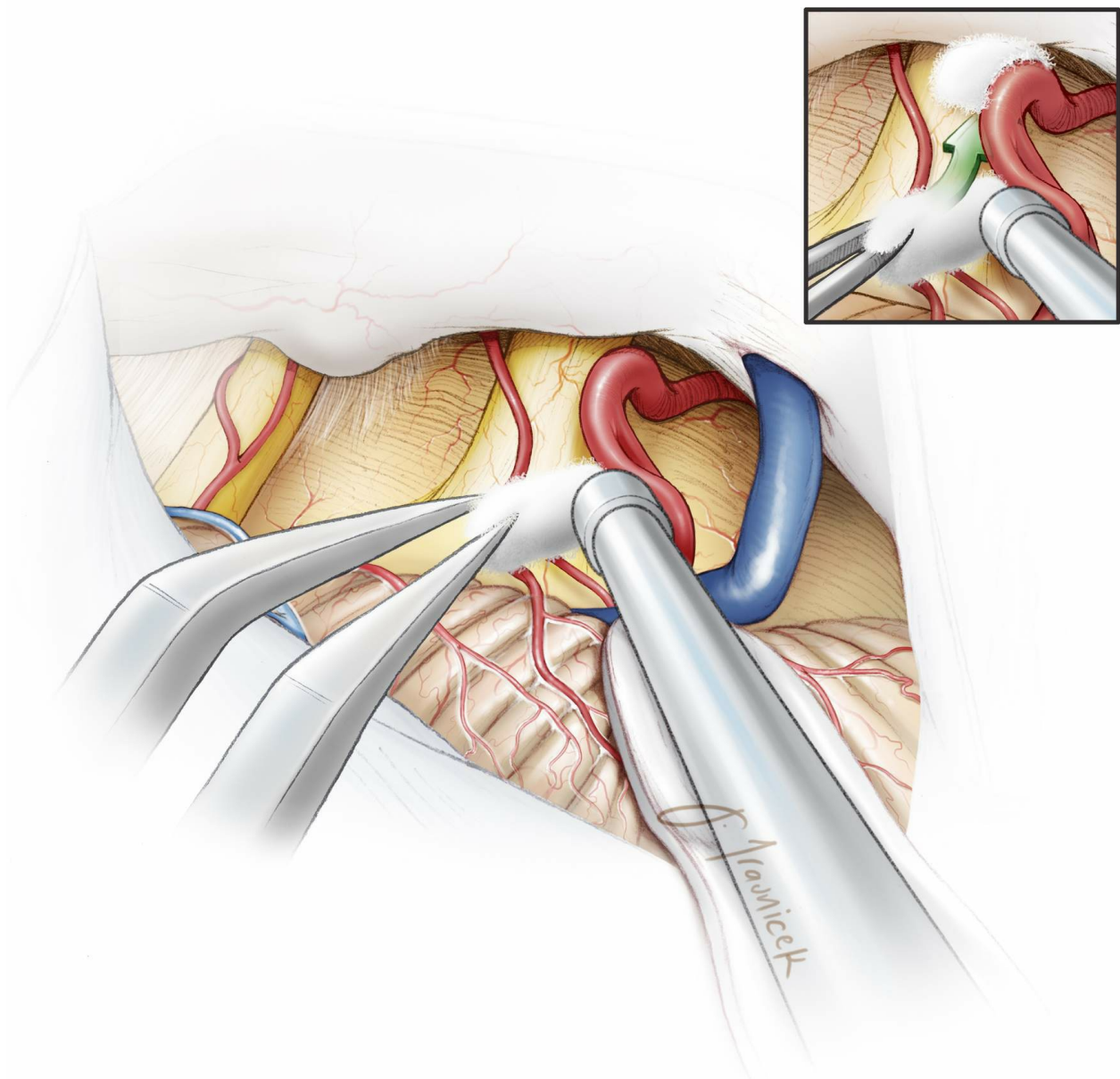


Figure 11: Implanting pieces of shredded Teflon between the nerve and the offending vessel: The artery is generously mobilized and a series of small pieces of shredded Teflon are placed along the root entry zone and pushed ahead parallel to the nerve (inset) to prevent any vascular conflict along the root entry zone and entire cisternal segment of the nerve.

Pieces of shredded Teflon implant are used to prevent contact between the nerve and surrounding vessels. The use of unshredded Teflon should be avoided because of the risk of implant displacement later. Pieces of Teflon are inserted and pushed ahead, along the nerve. This maneuver allows the small pieces of implant to conform to the shape of the artery, minimizing the risk of their delayed displacement.

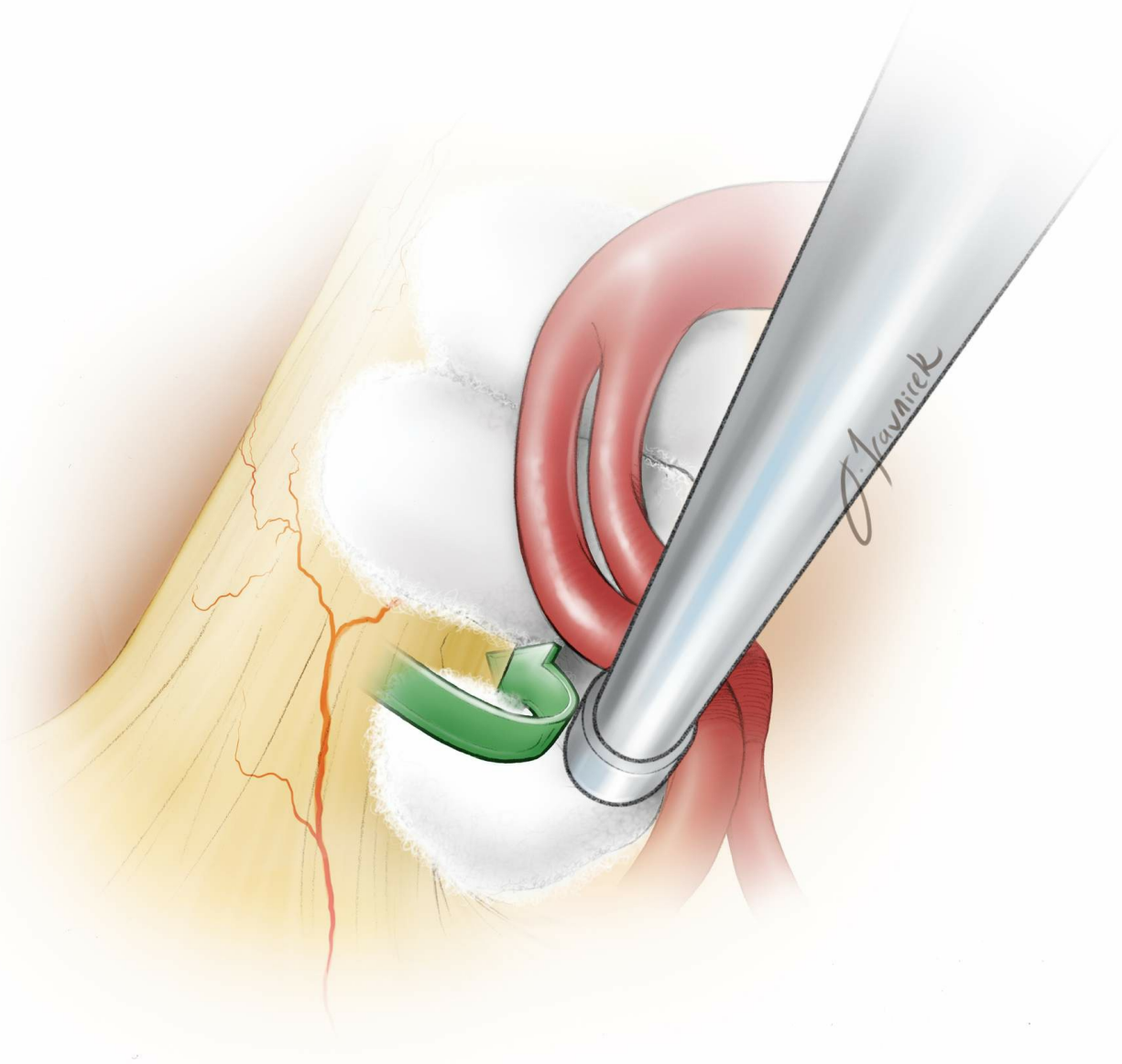


Figure 12: I specifically insert a piece of shredded Teflon along the shoulder and medial axilla of the nerve to prevent any contact between the vessel and the root entry zone or brainstem.

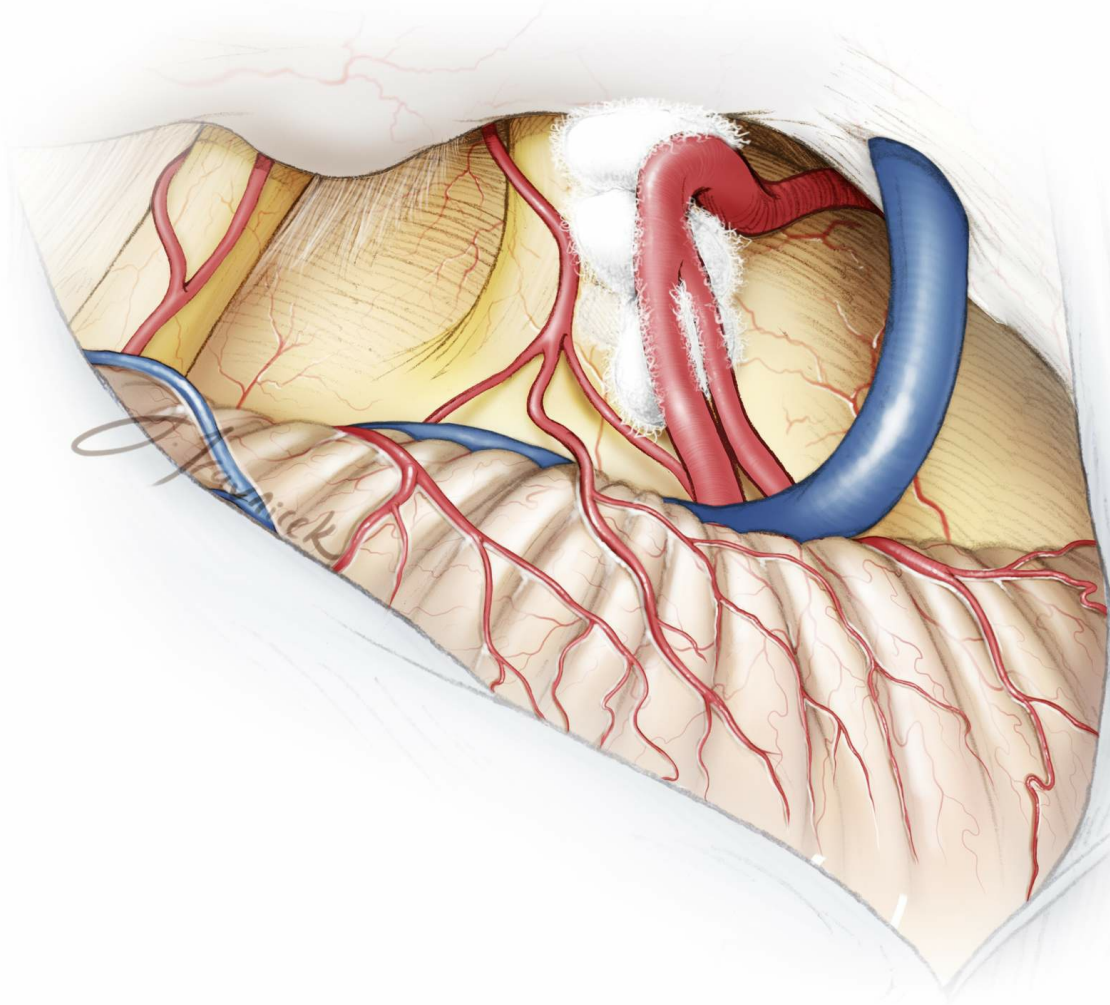


Figure 13: The final construct mobilizes the artery along its entire length. The vessel is mobilized and generously padded away from the nerve to prevent any contact with neural tissue. Fibrin glue may be used to reinforce this construct. I avoid excessive Teflon implantation to prevent Teflon granuloma formation, which may play a role in pain recurrence.

Central myelin may extend far distally along the trigeminal nerve—as far as the Meckel’s cave— and therefore decompression should be completed along the entire length of the nerve. Any bony protuberance along the petrous bone that obstructs the surgeon’s view should be drilled away to allow inspection of the entire length of the nerve. All vessels should be mobilized along the nerve: arteries and large veins should be mobilized and padded and smaller veins coagulated and cut.

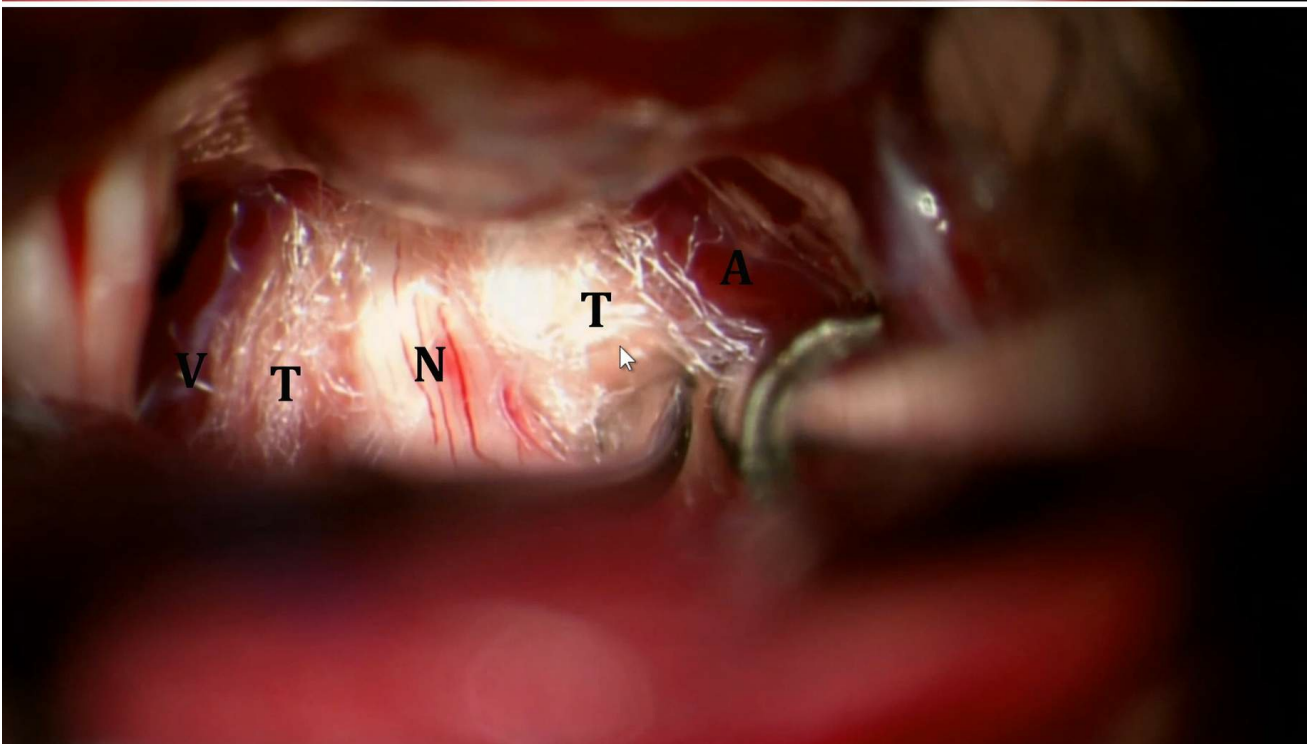
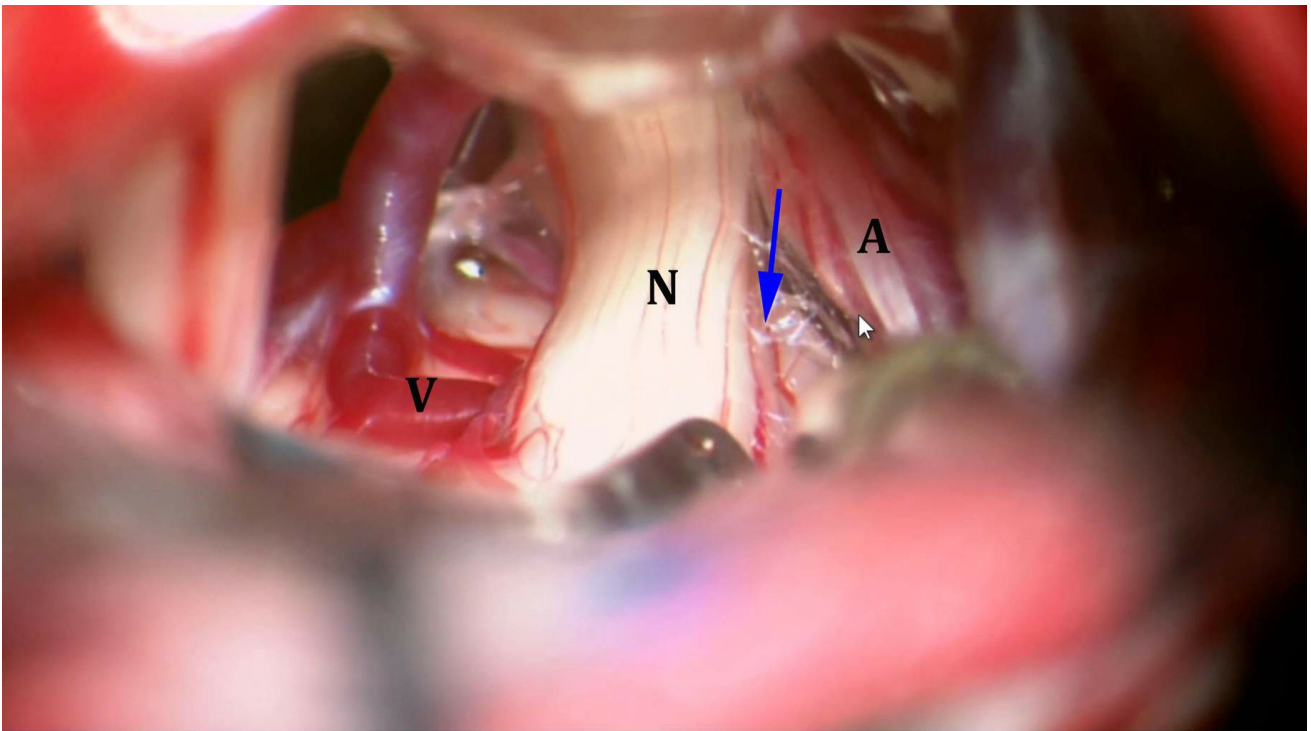


Figure 14: Classic neurovascular conflict through a left retromastoid craniotomy: The blue arrow highlights the site of impression on the nerve (N) (top image). The artery (A) and the potential offending vein (V) were mobilized using pieces of Teflon (T) implant (bottom image).

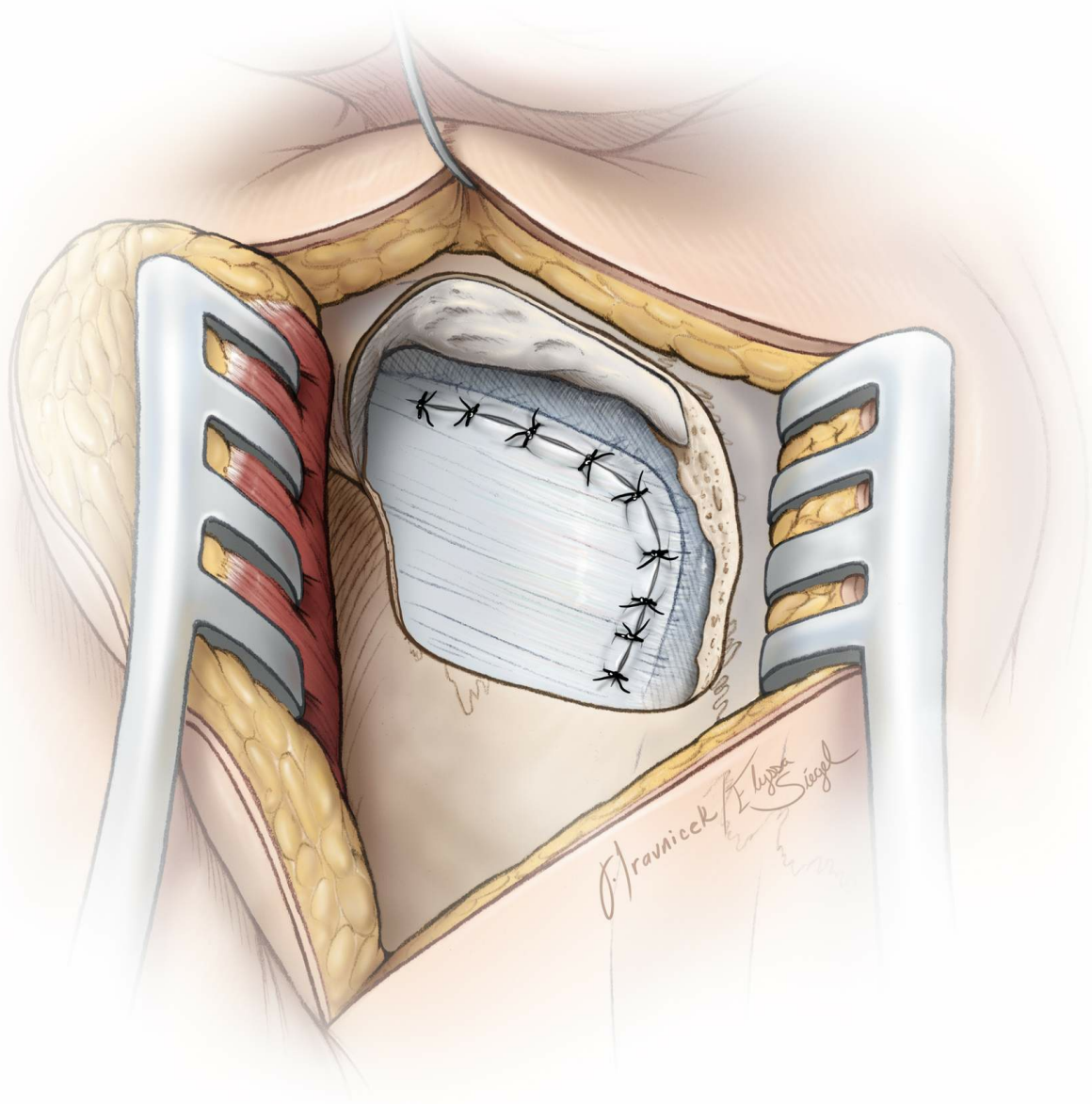


Figure 15: Dural closure

Closure

I attempt a watertight dural closure and may use a piece of muscle to plug small defects not repairable through primary closure. For MVD operations, I do not persist on performing a watertight dural closure because these operations are associated with a very low rate of CSF leak through the incision or the nose. Unlike tumor operations, the MVD procedures are pristine and associated with a small risk of increased CSF pressures postoperatively.

The mastoid air cells are rewaxed thoroughly. I cover the epidural space

with a piece of Gelfoam. The bone flap is replaced or a methyl methacrylate cranioplasty is performed. And finally, the muscle and scalp are closed in anatomical layers.

Neurovascular Conflict: Variations

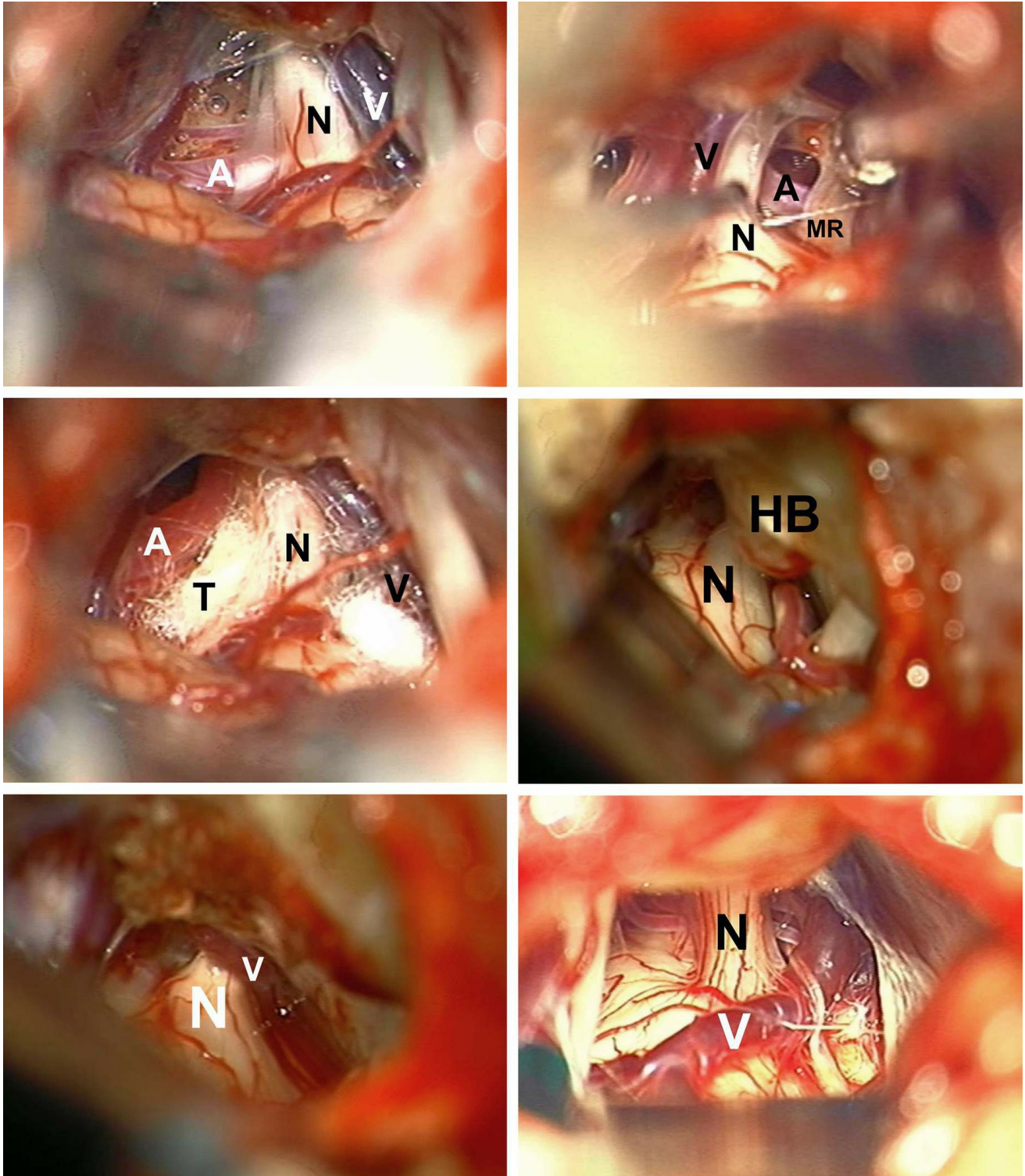


Figure 16: Intraoperative images of findings during MVD procedures: Commonly, there are multiple arterial (A) and venous (V) offending vessels, and one offending artery (A) is hidden behind the motor root (MR) of the trigeminal nerve (V)(upper left and right images). The use of

shredded Teflon (T) can thoroughly mobilize the compressive arterial and venous loops (middle left image). Hypertrophied petrous bone (HB) may hide a vascular loop (middle right image). Following drilling of the hypertrophied petrous bone, a previously hidden vascular loop is visible (lower left image). A venous loop can be the sole source of vascular conflict (lower right image).

Negative Exploratory Surgery

If careful circumferential inspection of the nerve does not disclose an offending vessel, I use fine forceps and gently pinch the trigeminal nerve. This maneuver leads to a rhizotomy and is often effective for providing pain control. I perform this same maneuver in some of my MVD operations when only a venous offending vessel is present.

I have not yet been convinced that venous compression can be the sole pain generator in TN and more often perform a rhizotomy after thorough inspection and implantation of the Teflon around the vein. I do not perform partial nerve transection because of the potential risk of disabling anesthesia dolorosa.

Postoperative Considerations

After surgery, patients are usually admitted to the neuro intensive care unit overnight for observation and then transferred to the regular ward for a couple of days before they can be discharged home. Special attention should be paid to hemodynamic parameters, neurologic examination, and wound care.

Steroids are administered prophylactically to prevent aseptic meningitis and minimize postoperative nausea and headaches. I do not routinely perform a head CT postoperatively. Preoperative neuralgic pain medications are weaned off starting 1 week after surgery if the patient remains pain free. Occasionally, the benefits of surgery may be delayed, and patients should be informed of this possible delayed effect to avoid early disappointment.

Management of Postoperative Complications

Sensorineural hearing loss is an exceedingly rare complication from MVD surgery for trigeminal neuralgia. This hearing loss should be distinguished from middle ear effusion, which is identified as a sense of fullness in the ear caused by fluid accumulation in the middle ear from opening the mastoid air cells during craniotomy. This feeling of ear fullness is temporary.

If the patient suffers from CSF rhinorrhea, we return him or her to the operating room immediately for repacking of the mastoid air cells and inspection of the dural closure. If CSF leaks from the wound, we “oversew” the incision and may use a lumbar drain for 72 hours if the initial incision reinforcement is inadequate. If drainage continues when the lumbar drain is discontinued, we return the patient to the operating room for a watertight dural closure and wound revision.

Repeat MVD

I consider repeat MVD surgery an option for healthy patients who harbored a convincingly offensive arterial loop during their initial surgery. These patients should have experienced a relatively lasting period of pain freedom after their initial MVD operation. If I did not find a convincing offending vascular loop during the first surgery, I offer the patient a percutaneous procedure for their pain recurrence. Teflon granuloma is a relatively under-recognized occurrence and may be causal, so excessive Teflon implantation should be avoided.

Final Thoughts

Percutaneous rhizotomy procedures are reserved for older patients with associated prohibitive medical comorbidities. Intraneural vessels transecting the nerve can cause trigeminal neuralgia. Aggressive manipulations of the nerve to decompress intraneural vessels should be avoided. Such aggressive manipulations may lead to unpleasant postoperative numbness and neuropathic pain.

An offending neurovascular relationship may change during surgery with

the patient's position. Intraoperative retraction and CSF drainage may further alter these relationships. Therefore, the offending vessel may actually be found 1-2 mm away from the true area of neurovascular conflict.

The surgeon should take advantage of microsurgical techniques when performing this operation. In the presence of alternative methods of therapy, including percutaneous procedures that carry relatively minimal risk, MVD operations should be performed with very low risk to the patient.

And finally, there is a learning curve involved with this operation, and the surgeon should remain always critical of his/her performance and aspire for a perfect result. *The patients who have undergone this operation are among the most thankful patients in my practice and have made the practice of neurosurgery a privilege for me.*

Pearls and Pitfalls

- Trigeminal neuralgia is characterized by paroxysmal attacks of unilateral, sharp, stabbing facial pain, within one or more divisions of the trigeminal nerve, lasting <1 second to 2 minutes, and precipitated by stimulation of certain trigger zones.
- Differential diagnosis of trigeminal neuralgia includes disorders of dentition, temporomandibular joint, and certain headache syndromes. These conditions should be ruled out with an extensive patient history and detailed neurologic examination.
- Patients with burning pain, facial numbness, or (only) constant pain without triggering stimuli may be suffering from atypical or neuropathic pain, and not neuralgic facial pain. They may not be candidates for a posterior fossa exploratory operation; judicious patient selection for operative intervention is advised.
- Many patients have multiple offending vessels, and identification of one offending vessel does not preclude the search for another one. The root entry zone must be circumferentially inspected before placement of the implant.

Contributor: Aqueel Pabaney, MD

DOI: <https://doi.org/10.18791/nsatlas.v6.ch01.1>

REFERENCES

Amador N, Pollock BE. Repeat posterior fossa exploration for patients with persistent or recurrent idiopathic trigeminal neuralgia. *J Neurosurg.* 2008;108:916-920

Barker FG 2nd, Jannetta PJ, Bissonette DJ, Larkins MV, Jho HD. The long-term outcome of microvascular decompression for trigeminal neuralgia. *N Engl J Med.* 1996;334:1077-1083.

[Cohen-Gadol AA](#). Microvascular decompression surgery for trigeminal neuralgia and hemifacial spasm; nuances of the technique based on experiences with 100 patients and review of the literature. *Clin Neurol Neurosurg.* 2011;113:844-853.

Granit R, Leksell L, Skoglund CR. Fibre interaction in injured or compressed region of nerve. *Brain.* 1944;67:125-140

Hitotsumatsu T, Matsushima T, Inoue T. Microvascular decompression for treatment of trigeminal neuralgia, hemifacial spasm, and glossopharyngeal neuralgia: three surgical approach variations: technical note. *Neurosurgery.* 2003;53(6):1436-1441

Howe JF, Calvin WH, Loeser JD. Impulses reflected from dorsal root ganglia. *Brain Res.* 1976;116:139-144

Jannetta PJ. Hemifacial spasm, in: Samii M, Jannetta PJ (eds): *The Cranial Nerves: Anatomy, Pathology, Pathophysiology, Diagnosis, Treatment.* Berlin: Springer-Verlag; 1981.

Matsushima T, Inoue T, Fukui M. Arteries in contact with the cisternal portion of the facial nerve in autopsy cases: Microsurgical anatomy for neurovascular decompression surgery of hemifacial spasm. *Surg*

Neurol. 1990;34:87-93.

Miller JP, Acar F, Burchiel KJ. Classification of trigeminal neuralgia: clinical, therapeutic, and prognostic implications in a series of 144 patients undergoing microvascular decompression. *J Neurosurg.* 2009;111:1231-1234.

Møller AR. Vascular compression of cranial nerves II: Pathophysiology. *Neurol Res.* 1999;21:439-443.

Prasad S, Galetta S. Trigeminal neuralgia: historical notes and current concepts. *Neurologist.* 2009;15(2):87-94

Rhoton A. The cerebellopontine angle and posterior fossa cranial nerves by the retrosigmoid approach. *Neurosurgery.* 47(3):S93-129, 2000

Zakrzewska JM, Linskey ME. *Trigeminal neuralgia.* *Br Med J.* 2014 17;348:g474

Related Materials

Other Atlases



Meyer Atlas: Percutaneous Procedures for Trigeminal Neuralgia

Available Through the Atlas



The long-term outcome of microvascular decompression for trigemin...



Microvascular decompression of cranial nerves: Lessons learned af...



Practice Parameter: The diagnostic evaluation and treatment of tr...



A 10-year experience in the treatment of trigeminal neuralgia. Co...



Mechanism of trigeminal neuralgia: An ultrastructural analysis of...

 AAN-EFNS guidelines on trigeminal neuralgia management

 Evaluation of microvascular decompression and partial sensory rhi...

 Microvascular decompression for trigeminal neuralgia: Comments on...

 Microvascular decompression for trigeminal neuralgia caused by ve...

 Microvascular decompression for primary trigeminal neuralgia: Lon...

 Demonstration of neurovascular compression in trigeminal neuralgi...

 Fully endoscopic microvascular decompression for trigeminal neura...

 A tentorial sling in microvascular decompression for trigeminal n...

 Technique of microvascular decompression: Technical note

 Predictors of outcome in surgically managed patients with typical...

 Bilateral trigeminal neuralgia: A 14-year experience with microva...

 Success of microvascular decompression with and without prior sur...

 Neurovascular compression in trigeminal neuralgia: A clinical and...

 Predictors of long-term success after microvascular decompression...

 Repeat posterior fossa exploration for patients with persistent o...

Unavailable Through the Atlas

 Microvascular decompression surgery in the United States, 1996 to...

 Is the root entry/exit zone important in microvascular compressio...

 Microvascular decompression for trigeminal neuralgia. A five-year...

 Microvascular decompression for trigeminal neuralgia in the elder...

 Repeat operations in failed microvascular decompression for trige...

 Long-term results of microvascular decompression for trigeminal n...

 A comparison of percutaneous radiofrequency trigeminal neurolysis...

 Findings and long-term results of subsequent operations after fai...

 Operative findings and outcomes of microvascular decompression fo...

 Serious complications of microvascular decompression operations f...

 Patient's assessment of outcome after three surgical procedures f...

 Trigeminal neuralgia caused by venous compression

 Adjunctive use of endoscopy during posterior fossa surgery to tre...

 Microvascular decompression for trigeminal neuralgia: The importa...

Other Materials

 MVD for Trigeminal Neuralgia and Hemifacial Spasm-PDF

 Grand Rounds Slides