



Microvascular Decompression for Glossopharyngeal Neuralgia

Last Updated: July 4, 2021

Glossopharyngeal neuralgia (GN) is a very rare pain disorder characterized by severe, lancinating, paroxysmal pain in the areas supplied by the auricular and pharyngeal branches of cranial nerves (CN's) IX and X. **The affected regions can include the external ear canal, base of the tongue, tonsillar pillars, posterior pharynx, and the area beneath the angle of the jaw.**

Common triggers include speaking, swallowing, eating, breathing, cold air, and other cutaneous stimuli of the mouth and pharyngeal region. Occasionally these paroxysmal attacks are accompanied by hemodynamic instability, *syncope*, asystole, and convulsions, leading to the condition called vagoglossopharyngeal neuralgia.

Glossopharyngeal neuralgia is 100 times less common than trigeminal neuralgia, generally affects patients in their 5th decade of life, and most often involves the left side. In 2% of sufferers, it presents bilaterally.

The International Headache Society recently proposed a subclassification of GN that includes classical and symptomatic forms. In the classical type, the pain is only intermittent without any underlying cause or associated neurologic deficit. The symptomatic type resembles the classical form; however, the aching pain can persist between neuralgic episodes and sensory impairment can be found in the distribution of the affected cranial nerves due to structural lesions.

Most GN cases are idiopathic—no abnormality is apparent on clinical exam or imaging studies. Idiopathic forms of GN might possibly be caused by severe demyelination and axon-degeneration of CN's IX and X.

Secondary GN can occur due to compression by vascular structures; a tumor in the cerebellopontine angle, skull base, oropharynx, nasopharynx, or tongue; a calcified stylohyoid ligament; parapharyngeal abscess; direct carotid puncture; trauma; dental extractions; multiple sclerosis; Paget's disease; elongated styloid processes (such as Eagle's syndrome); occipito-cervical malformations; and inflammatory processes such as Sjogren's syndrome.

History

In 1910, Weisenburg described the first case of GN in a young patient who had been erroneously treated for trigeminal neuralgia. The association between vascular compression of CN IX and GN was first reported by Pope in 1889 and later confirmed by Walter Dandy.

Initial attempts to cure GN were directed at extracranial nerve ablation, but soon abandoned because of high morbidity and recurrence rates. Dandy performed the first intracranial rhizotomies of the glossopharyngeal nerve with good short-term results, but long-term pain recurrence was common.

In 1977, Peter Janetta popularized the concept of microvascular decompression for GN after his team reported six cases of GN caused by aberrant loops of the vertebral artery or the posterior inferior cerebellar artery (PICA) causing vascular conflict at the root exit zones of CN's IX and X.

Over time, microvascular decompression became the standard treatment for GN, with or without rhizotomy of CN IX. Rhizotomy of CN X has gradually fallen out of favor because of the high risk of postoperative CN X dysfunction such as swallowing difficulty and hoarseness. Newer drugs such as gabapentin are being used, but with limited success because GN seems to be more refractory to medical treatment than trigeminal neuralgia. More recently the use of stereotactic radiosurgery has been reported.

Personal Perspective

Microvascular decompression (transection of CN IX and decompression of CN X) is my preferred approach to this disorder. This technique is described below.

Diagnosis and Evaluation

Diagnosis of GN is strictly clinical as no imaging or testing modality has been found to reliably establish the diagnosis. Patients complain mostly of “stabbing” or “electric-like shocks” in the throat, base of the tongue, or near the angle of the jaw and external ear.

Glossopharyngeal neuralgia has been divided into two clinical subtypes based on the distribution of pain: the tympanic (affecting the ear) and the oropharyngeal (affecting the oropharyngeal area) subtypes. The pain is usually intermittent and unilateral, with the left side more often affected than the right side. Swallowing, yawning, coughing, talking, and ingestion of certain types of foods can trigger the pain. Also, touching the ear or external ear canal and lateral jaw movements have been implicated as triggers.

Approximately 10% of patients with GN experience excessive vagal effects (output) during a paroxysm (vagoglossopharyngeal neuralgia), which can lead to bradycardia, hypotension, syncope, seizures, and even cardiac arrest. Impulses from CN IX stimulate the dorsal nucleus of CN X, causing bradycardia or asystole. Topical anesthesia may help the physician find the trigger zones.

A detailed history and physical examination is prudent. It is important to document the site, origin, and characteristics of the pain; trigger factors; associated signs and symptoms such as syncope and convulsions; and previously attempted treatments. A neurologic examination should focus on motor and sensory testing of the lower cranial nerves. Sensory function should be tested in regions supplied by CN's V through X, including the face, ears, palate, and tongue.

The position of the uvula during elevation of the palate should be noted. Voice quality should be assessed for hoarseness. Cough and gag reflexes

should also be tested. A thorough examination of the oral cavity, oropharynx, and nasopharynx should be performed through a comprehensive otolaryngologic consultation to rule out an occult neoplastic process.

All patients with suspected GN should undergo dedicated high-definition magnetic resonance imaging (MRI) to evaluate for compressive lesions such as tumors or vascular loops, lengthened styloid processes, occipital-cervical malformations, and pharyngeal and lingual tumors. However, most often, imaging does not definitely demonstrate any mass lesion. A vascular loop may be evident, but an absence of it does not disqualify the patient for posterior fossa exploratory surgery if the diagnosis is relatively certain. **The MRI may warn me of the presence of a large tortuous vertebral artery that will require creative methodology for its mobilization.**

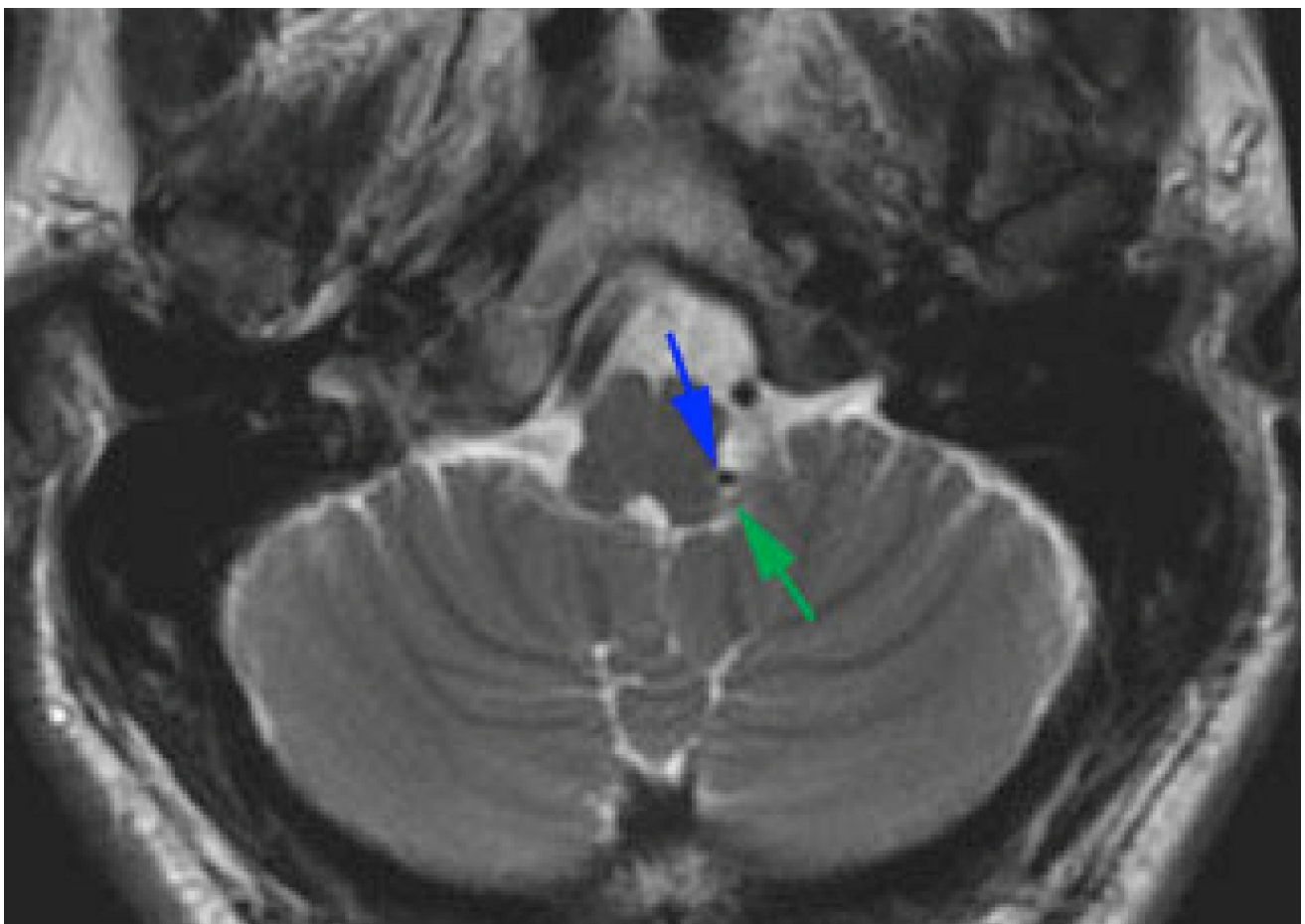


Figure 1: Axial high-resolution MRI demonstrates a vascular loop (blue arrow) at the level of lower cranial nerves near the brainstem (green arrow).

The diagnosis can be facilitated if there is cessation of pain when CN IX is

blocked at the jugular foramen and if administration of topical anesthesia at the pharynx stops the pain. These maneuvers are helpful, but careful history taking is the most accurate way to establish a correct diagnosis.

The clinician must be cognizant of the simultaneous co-existence of GN and other facial pain syndromes. Glossopharyngeal neuralgia syndrome can have significant overlap with three other cranial nerve hyperactivity syndromes:

- Not infrequently, GN is misdiagnosed as *trigeminal neuralgia*, especially if the angle of the jaw is one of the affected sites.
- Moreover, GN can be confused with *nervus intermedius* neuralgia (primary otalgia, Jacobson's neuralgia) when the only affected region is the ear.
- *Superior laryngeal neuralgia* can also mimic GN and create diagnostic confusion.

Temporomandibular joint disorders and temporal arteritis can have the same anatomic locations of pain, but they have different pain characteristics. Multiple sclerosis is an extremely rare cause of GN.

Indications for Surgery

Traditionally, the first line of treatment is pharmacologic. Surgical options may be considered in situations of drug intolerance, inefficacy, allergies, or side effects. Drugs most commonly used for GN include anti-epileptic medications such as carbamazepine, gabapentin, phenytoin, oxcarbazepine, or pregabalin. Some antidepressants can also be helpful, either alone or in conjunction with anti-epileptic drugs.

Unfortunately, medical therapy is almost uniformly ineffective. For this reason, almost all patients eventually consider microvascular decompression because it is an effective procedure for appropriately selected candidates. In the hands of an experienced surgeon, long-term pain freedom is achieved in approximately 90% of patients.

Preoperative Considerations

Intraoperative monitoring is employed during microvascular decompression for GN. Brainstem auditory evoked responses (BAERs) should be used routinely. To reduce any hindrance with monitoring, we use volatile general anesthetic agents at a concentration below 1%.

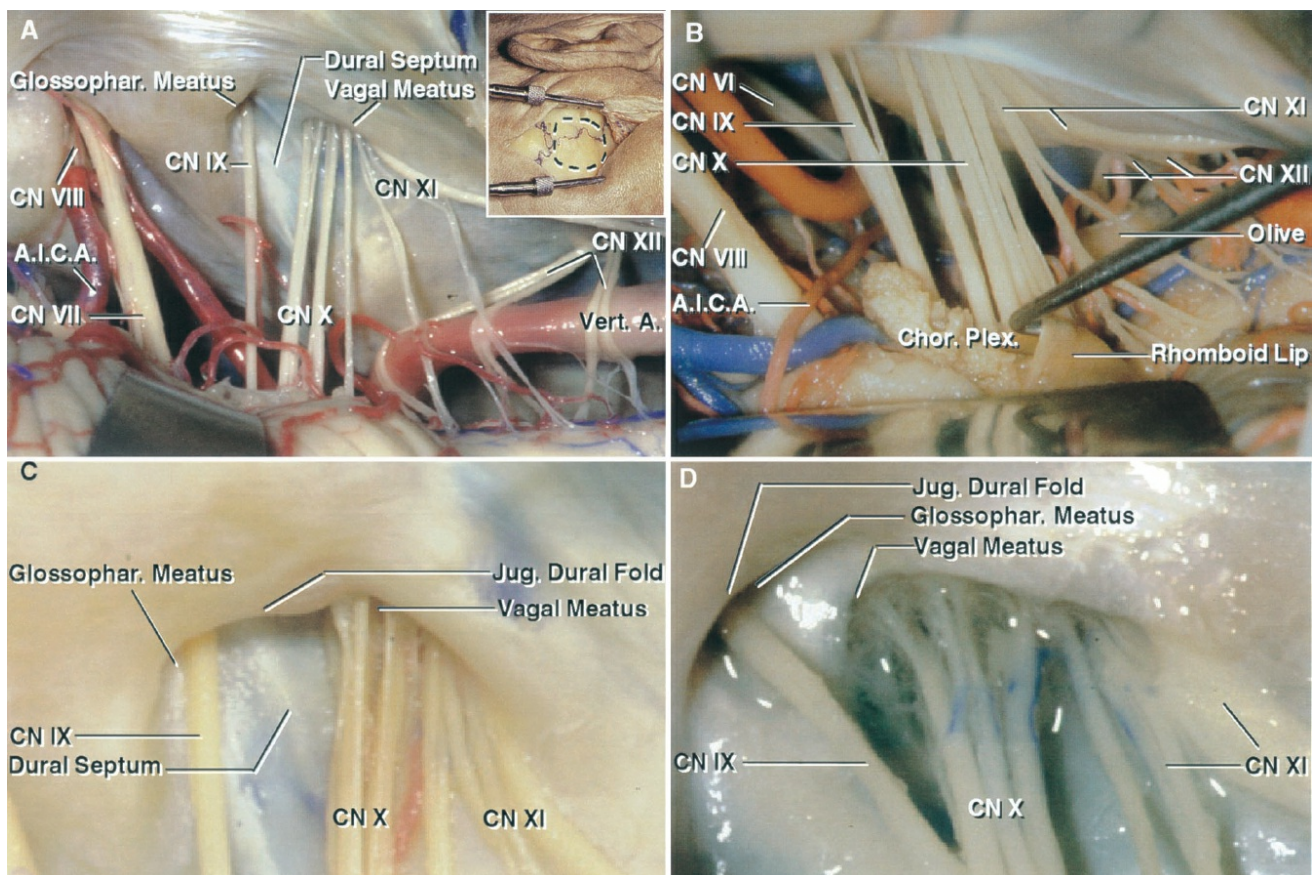
Intraoperatively, these patients are at high risk for hemodynamic instability due to hyperactivity of the vagus nerve. Prophylactic anesthetization of the oropharynx and atropine at the time of intubation will reduce the likelihood of sudden hemodynamic instability. Cardiac pacing should be strongly considered for patients with preoperative syncopal episodes.

Surgical Approach

A few different approaches have been described for microvascular decompression as applied to GN. The two most common approaches are suboccipital infrafloccular and transcondylar. We advocate the former since it does not require drilling of the condyle and is therefore less disruptive while providing excellent exposure. **The following steps describe the retromastoid infrafloccular route to the root exit zones of CN's IX and X.**

Operative Anatomy

The following images illustrate the relevant operative anatomy.



[Click here](#) to view the interactive module and related content for this image.

Figure 2: Right-sided retrosigmoid approach to the jugular foramen. The cerebellum has been elevated to expose the cranial nerves within the cerebellopontine angle and their relationship to the vertebral artery (VA) (A). Note the relationship of the choroid plexus and rhomboid lip to CN IX (B). Enlarged view of the jugular foramen: Note the dural septum that separates CN's IX and X at the level of the jugular foramen (C and D) (Images courtesy of AL Rhoton, Jr).

MVD for GLOSSOPHARYNGEAL NEURALGIA

The *infraflocculus route* is performed through a small retromastoid craniotomy. The general technical nuances for an [extended retromastoid craniotomy](#) are presented in the [Cranial Approaches Volume](#). In the following sections, I will review the specific steps of exposure related to microvascular decompression for GN.

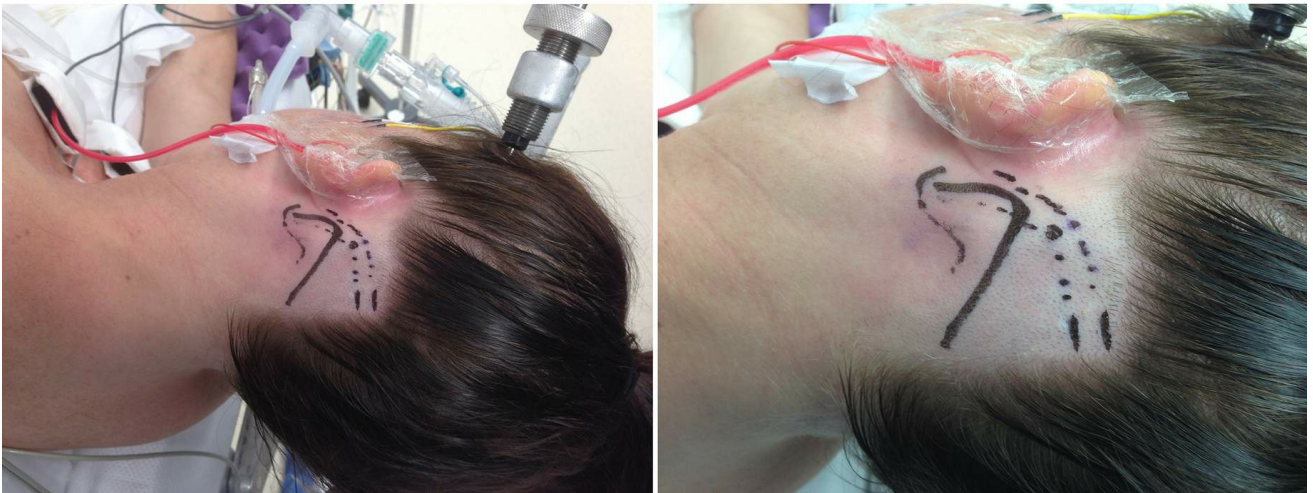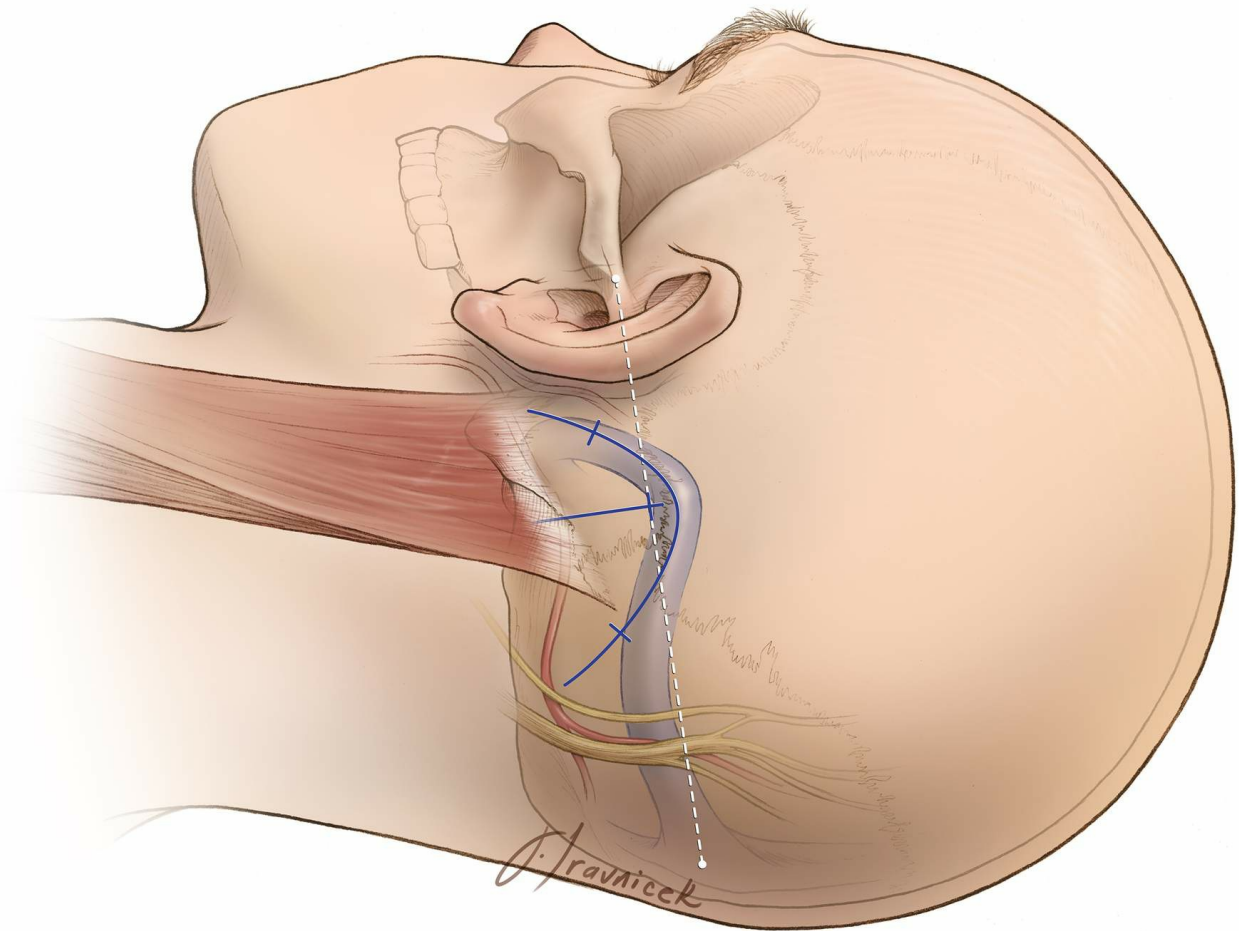


Figure 3: Modified reverse “U” skin incision whose summit is marked 1cm below the presumed junction of the transverse and sigmoid sinuses. Note the position of the head in the skull clamp (bottom left image).

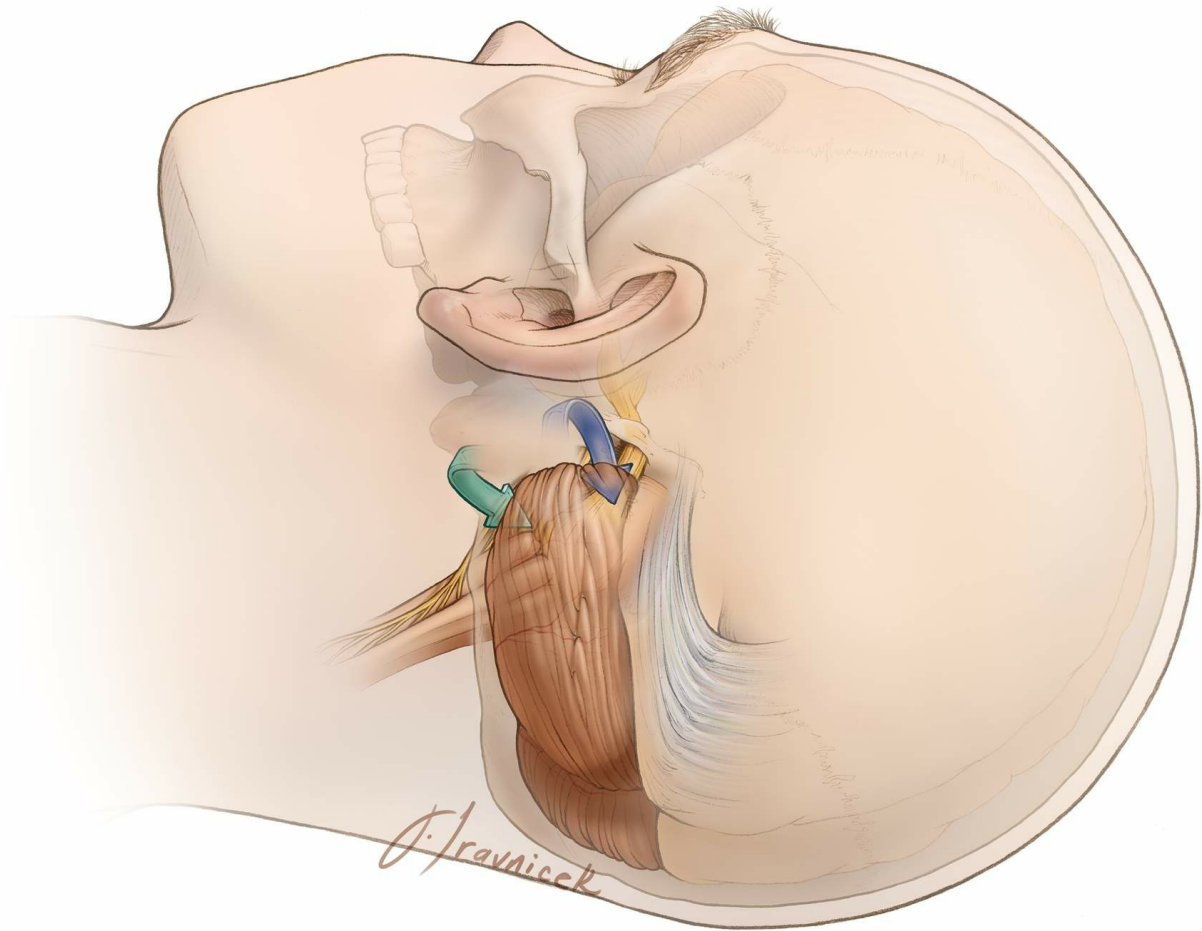


Figure 4: The operative corridors and trajectories for accessing the cerebellopontine angle: The surgical corridors for microvascular decompression for trigeminal neuralgia (supralateral cerebellar approach-blue arrow) and hemifacial spasm, and glossopharyngeal neuralgia (infralateral cerebellar or infrafloccular approach-green arrow) are illustrated.

Mobilization of the cerebellum in a purely medial direction must be avoided since this vector of retraction will be parallel to the sensitive CN VIII, increasing the risk of hearing loss. **I use the infralateral cerebellar corridor through the infraflocculus route to access the root exit zone of CN's IX and X.**

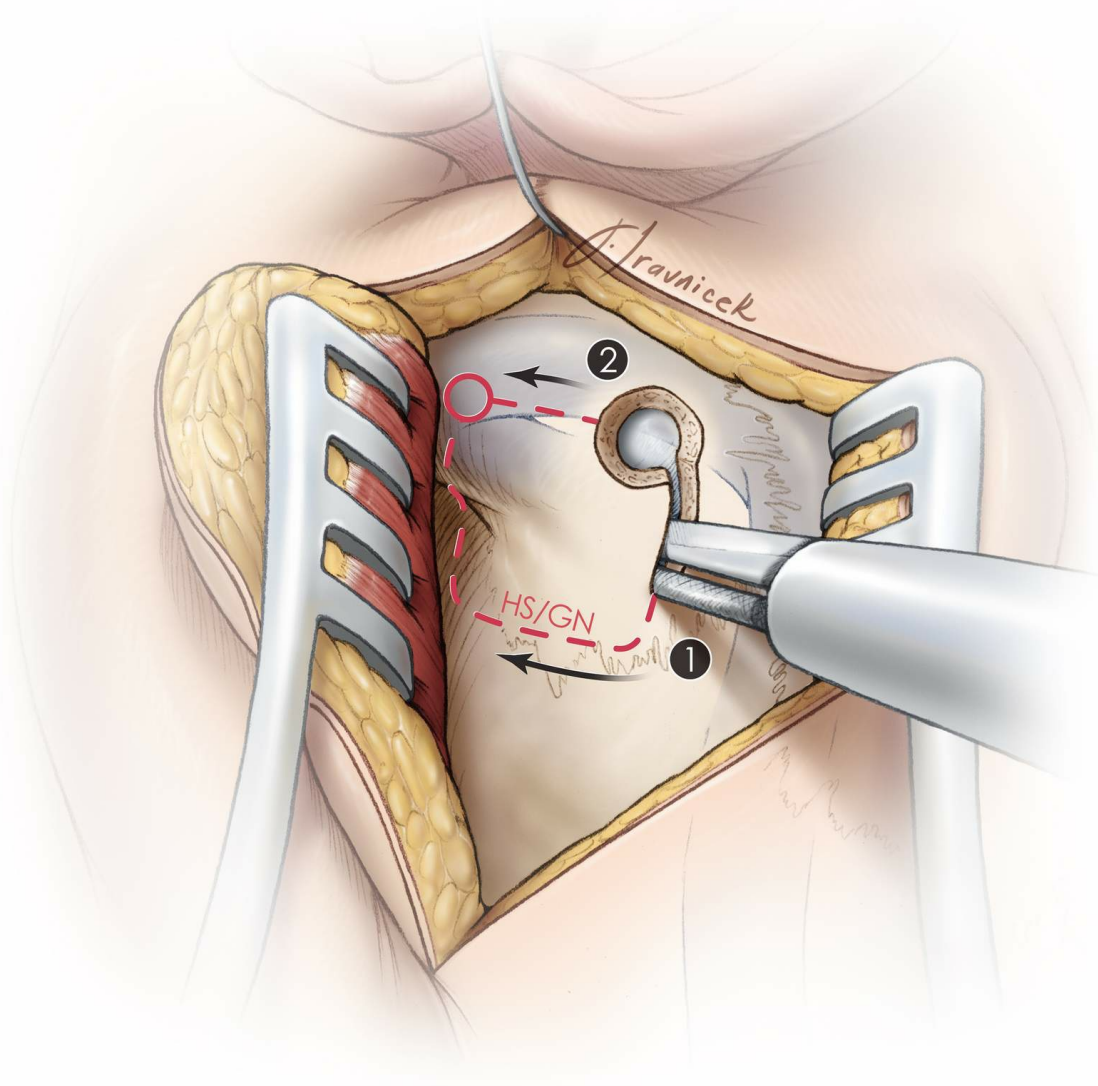


Figure 5: Burr hole and craniotomy (HS: hemifacial spasm, GN: glossopharyngeal neuralgia). A single burr hole is created at the edge of the sigmoid sinus and 1 centimeter below the transverse sinus. The size of the craniotomy or craniectomy is often small, about 1.0-1.5 times the size of a quarter coin.

A craniotomy should be avoided in older patients with adherent venous dural surface. The last osteotomy (2) is near the sigmoid sinus. The bone over the sigmoid sinus is removed during the next step using an air drill.

For additional nuances, please refer to the [extended retromastoid craniotomy chapter](#).

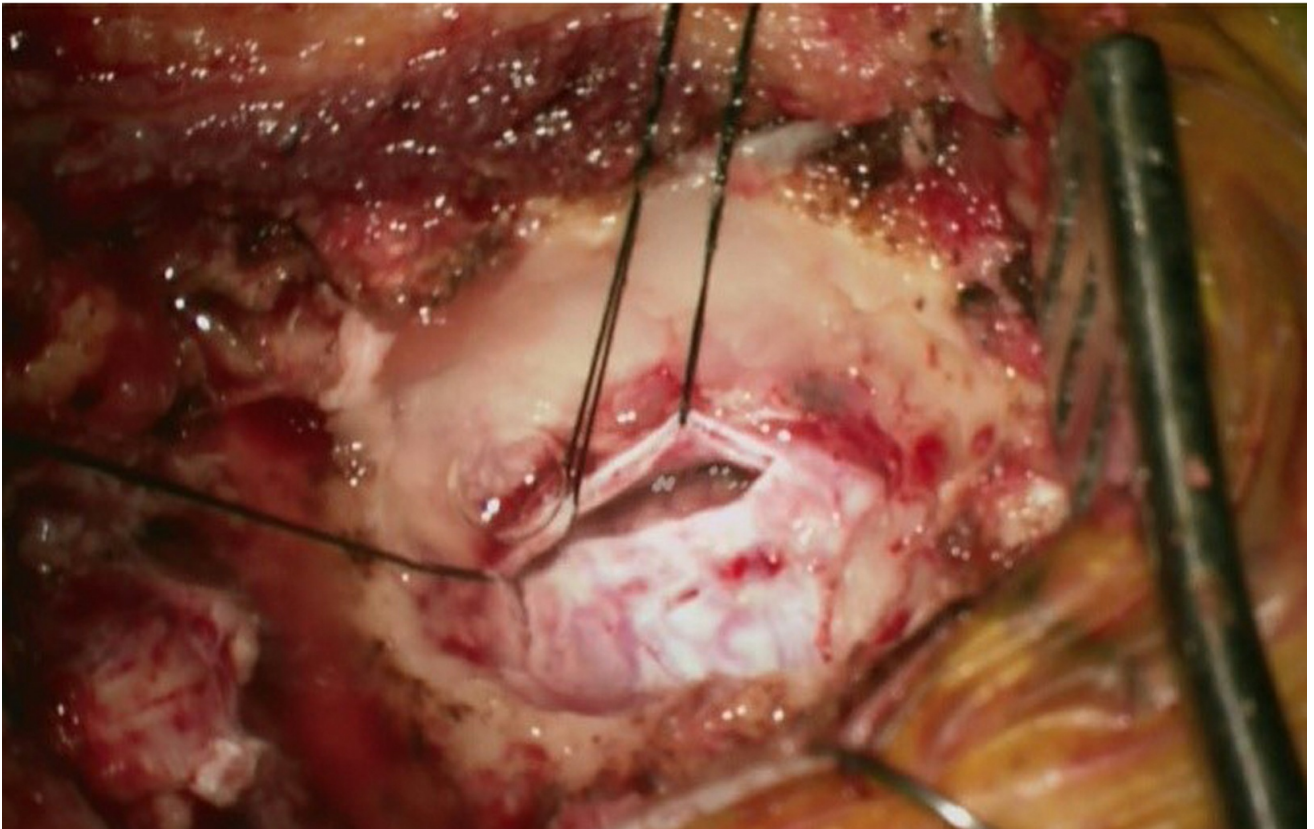
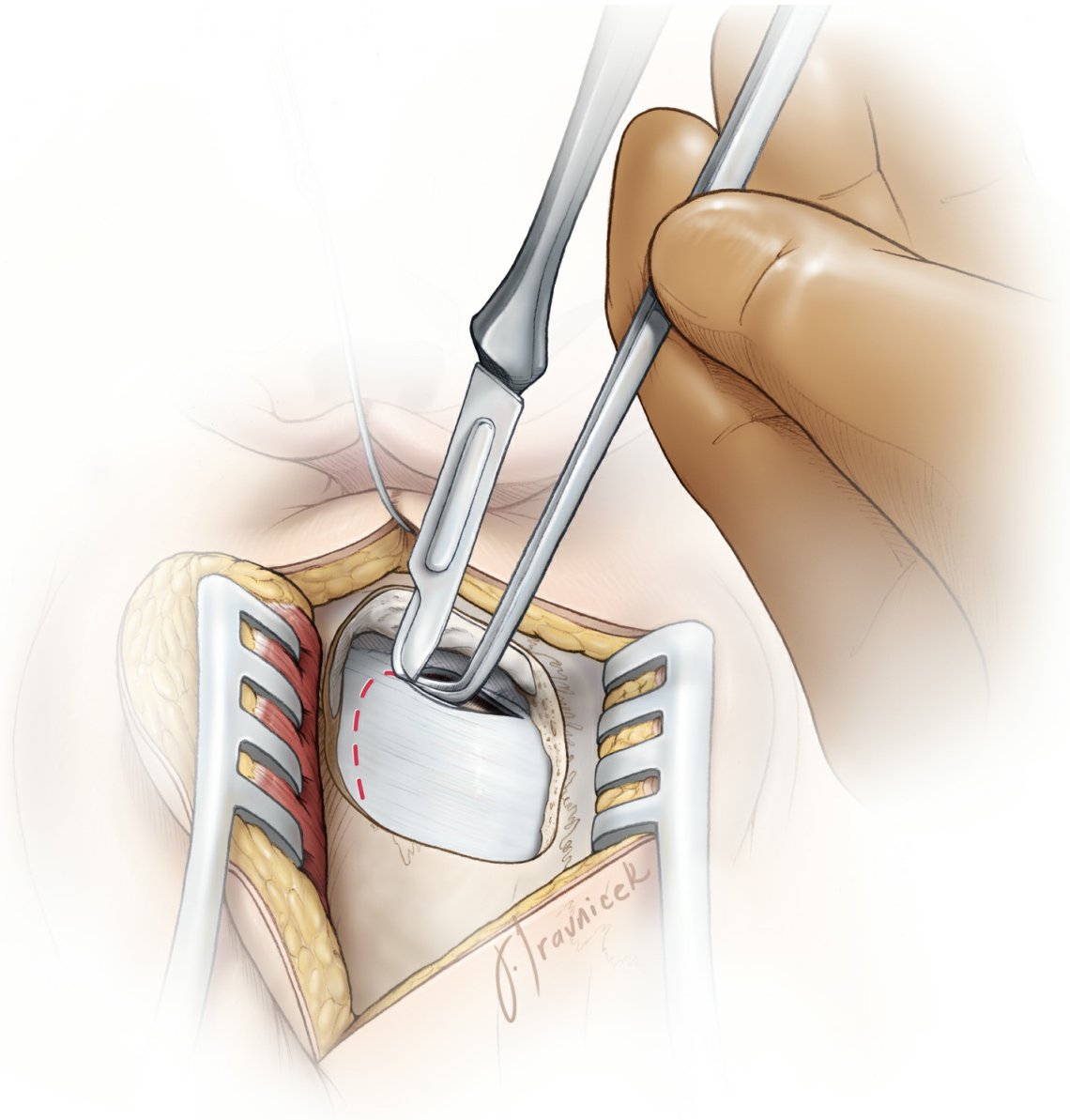
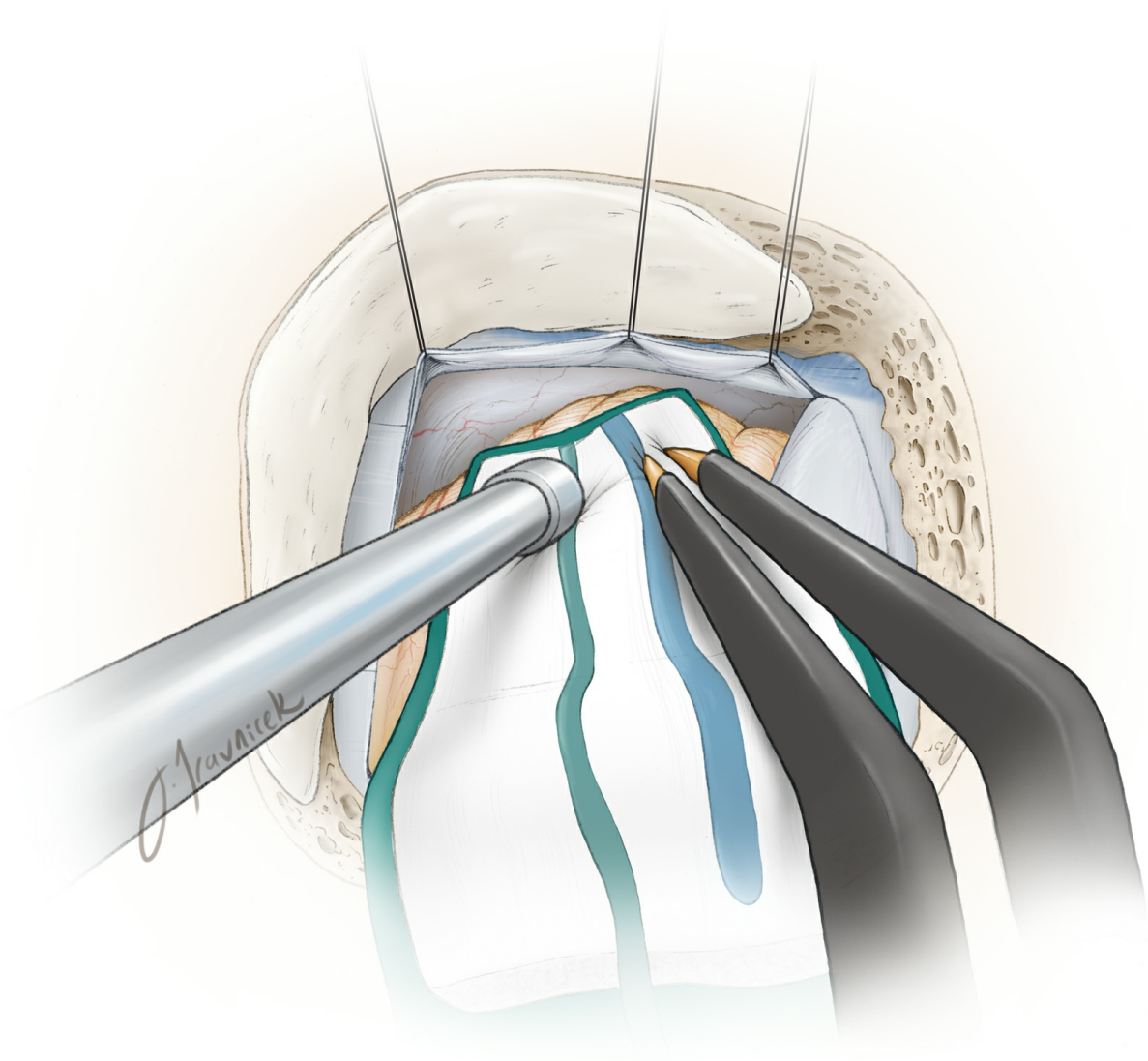




Figure 6: A technique for incising the dura (top image). A magnified operative photo demonstrates the extent of craniotomy and dural opening parallel to the sigmoid sinus and floor of posterior fossa (bottom image). There is no need to expose the transverse sinus. This mode of dural opening leaves most the dura on the cerebellum and therefore avoids desiccation and shrinkage of the dura under the operating microscope's intense light.

Unlike the linear skin incision, the curvilinear incision mobilizes the retracted myocutaneous flap inferiorly and prevents it from increasing the operator's working distance.

INTRADURAL PROCEDURE



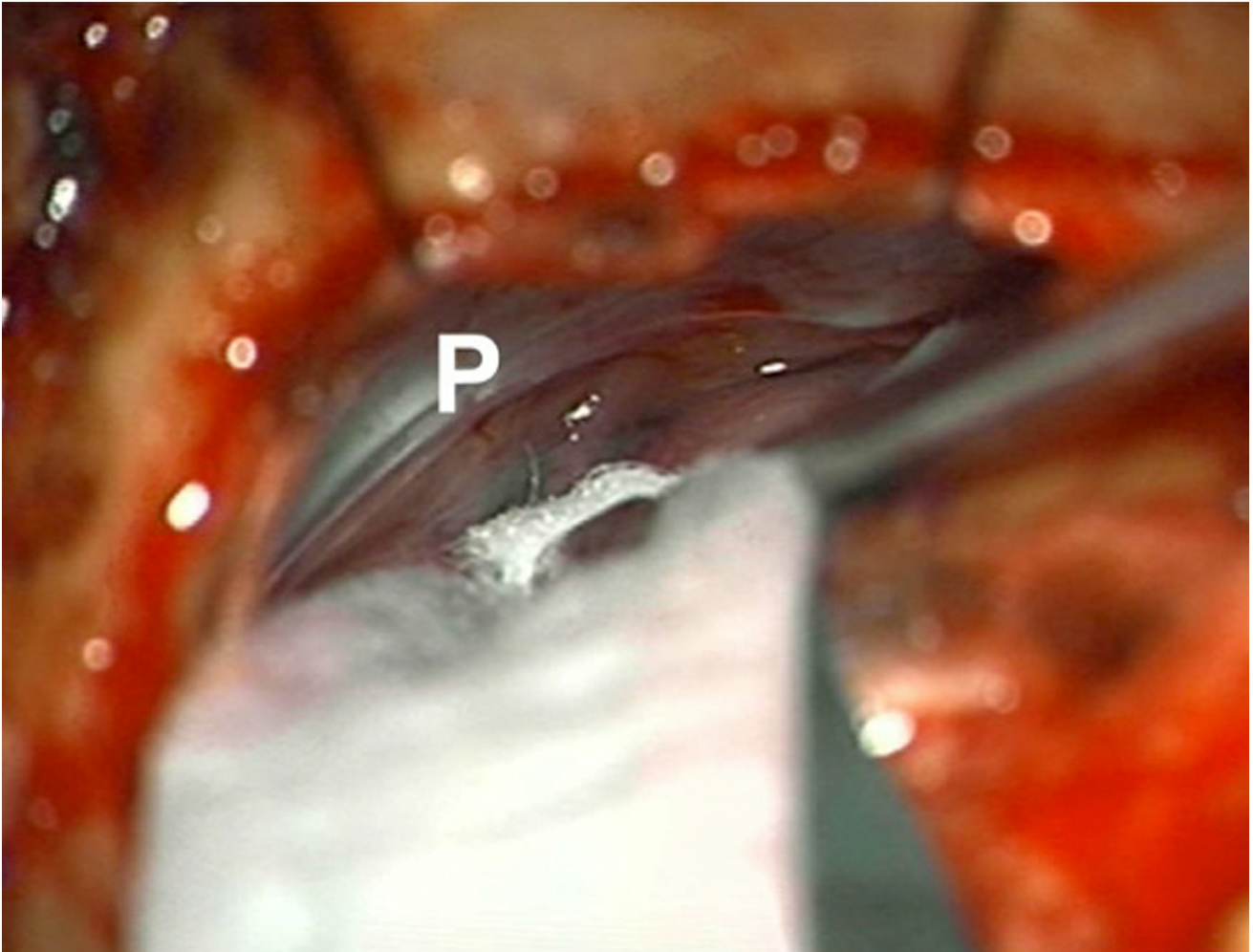


Figure 7: Supramedial cerebellar retraction: A piece of glove (cut slightly larger than the cottonoid patty) acts as a rubber dam. It protects the cerebellar hemisphere against the rough surface of the cottonoid as the rubber dam slides over the cerebellum while dissection is continued to expose the cerebellopontine angle (top image). I identify the junction of the petrous bone and the floor of posterior fossa (P, bottom intraoperative image) and advance the cottonoid over the rubber dam near the turn of the petrous bone toward the lower cranial nerves.

Medial retraction of the cerebellum parallel to CN VII/VIII is avoided to prevent direct transmission of retraction to these nerves. *The vector of retraction is parallel to CN IX. Note that I do not apply fixed retractors, but instead use the suction apparatus to mobilize the cerebellar hemisphere in a dynamic fashion during dissection. Along with generous opening of the regional arachnoid membranes over the cranial nerves, this maneuver minimizes the risk of hearing loss. Dynamic retraction of the suction apparatus allows intermittent exposure only where needed. Aggressive retraction of fixed*

retractors often provides exposure at places that may not be necessary.

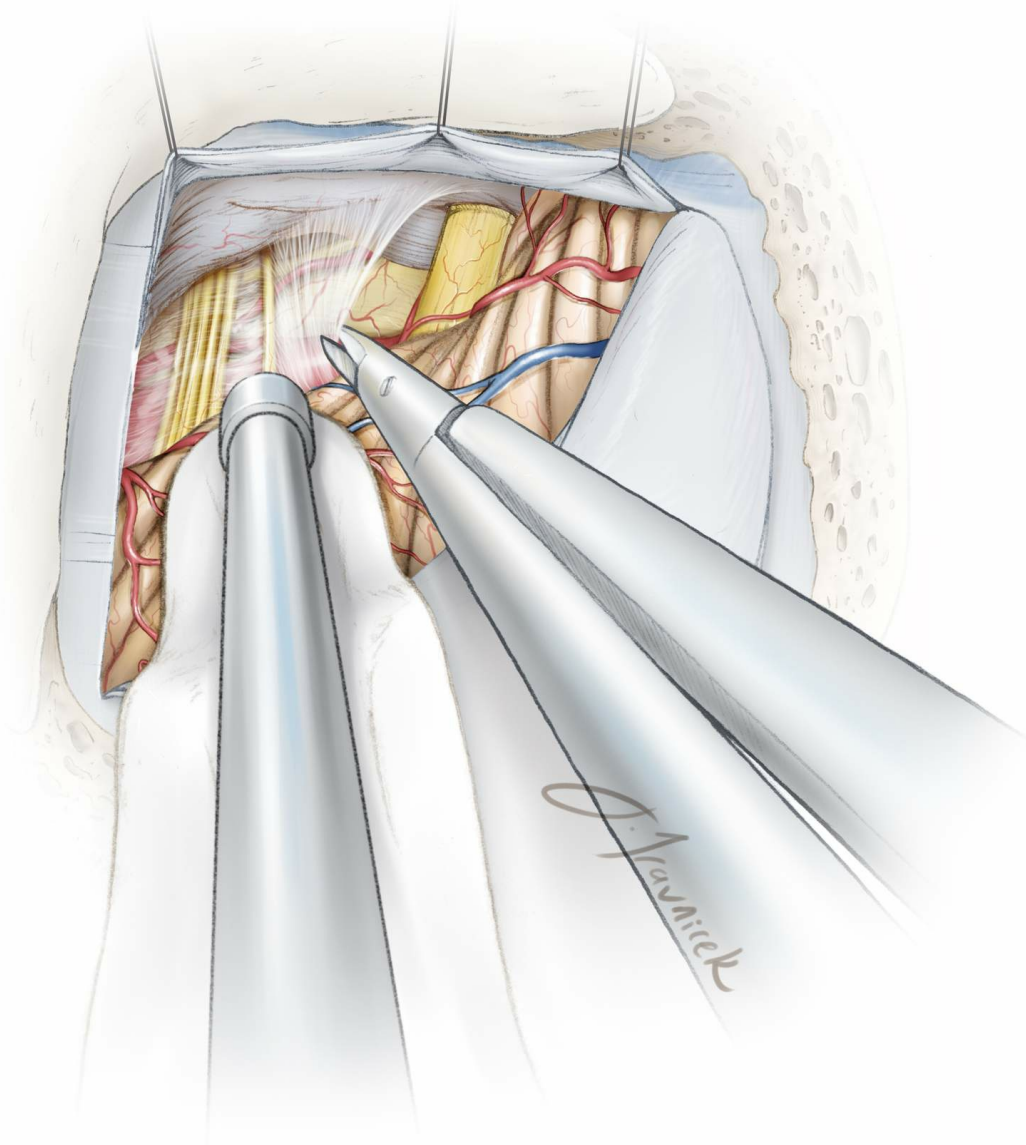


Figure 8: I *sharply* dissect the arachnoid membranes over the lower cranial nerves and identify CN IX. **Supramedial cerebellar mobilization allows me to follow the path of this nerve to its the exit zone at the level of the brainstem.** Intraoperative BAER monitoring guides the surgeon to adjust retraction to minimize undue traction on CN VIII.

I continue irrigating the field periodically during intradural dissection because the intense light of the microscope can cause heat injury to CN VIII. If exposed, I also cover the surface of CN VIII with a small piece of papaverine-soaked gelfoam to relieve vasospasm. If the BAERs change at

anytime during the intradural procedure, I perform the following steps:

1. Stop dissection and relieve all retraction while irrigating the operative field.
2. Allow a few minutes for the BAERs to return to normal. It may be necessary to increase the blood pressure. Before reapplying dynamic retraction, I further dissect the arachnoid membranes over CN VII/VIII to relieve any traction on these nerves while mobilizing the medial cerebellum. I also cover these nerves with a small piece of papaverine-soaked sponge to relieve any vasospasm caused by traction and the heat of the microscope.
3. I then attempt more superiorly directed retraction and use the infrafloccular corridor while minimizing any traction parallel to the CN VII/VIII complex.

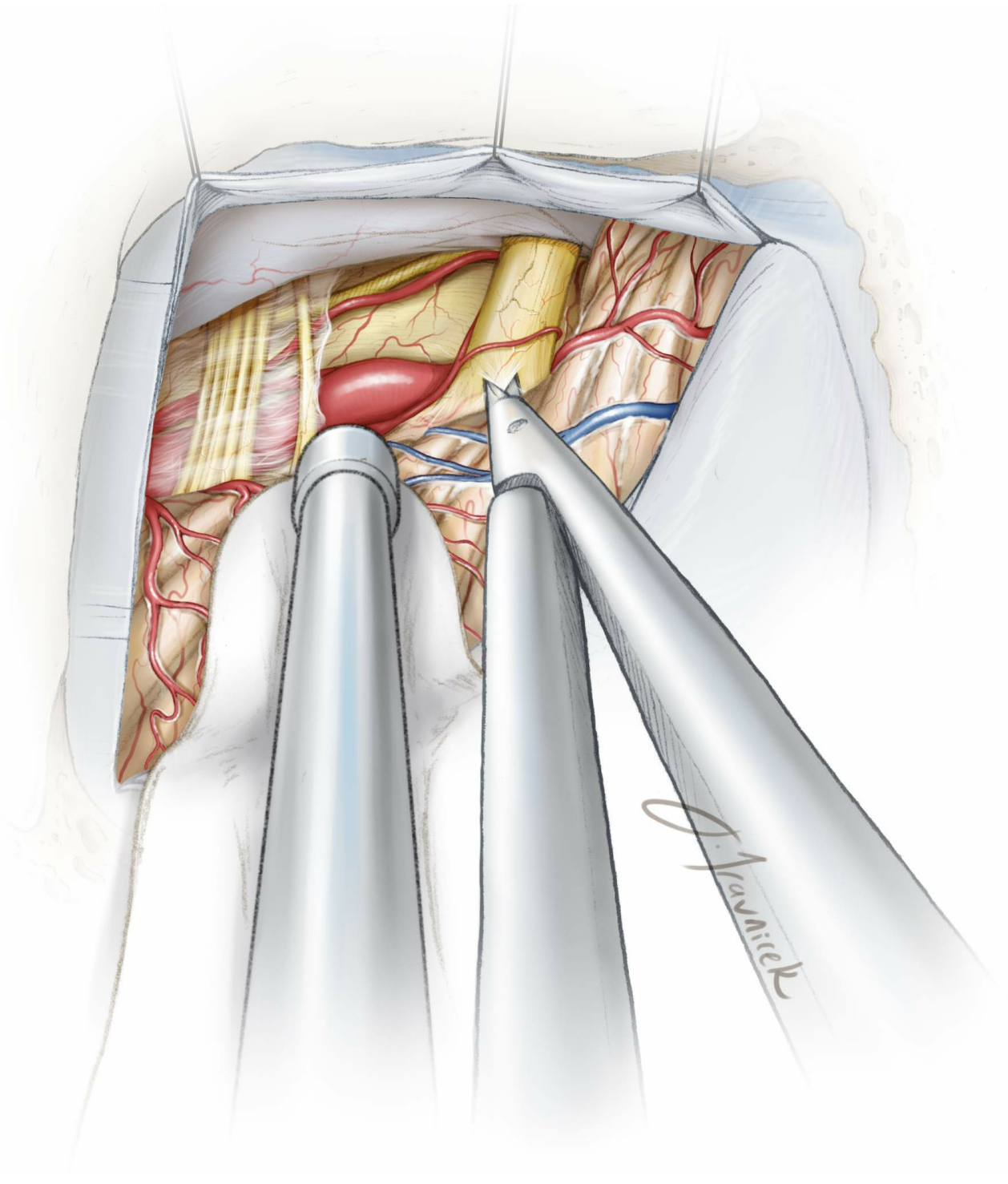
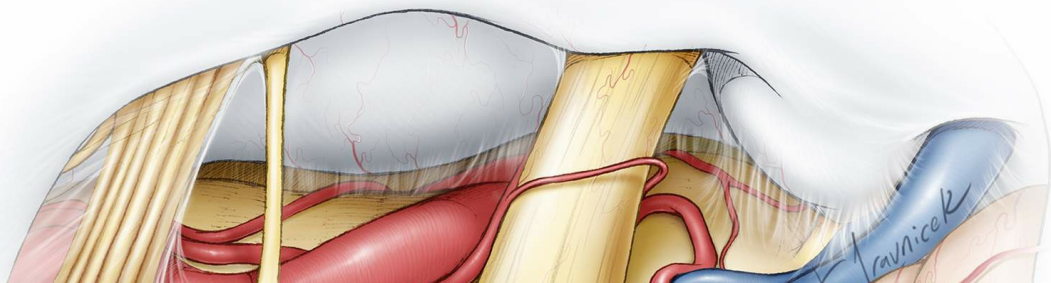


Figure 9: The arachnoid membranes over the CN VII/VIII complex are split sharply, close to the brainstem, to prevent undue traction on these nerves during mobilization of the flocculus.



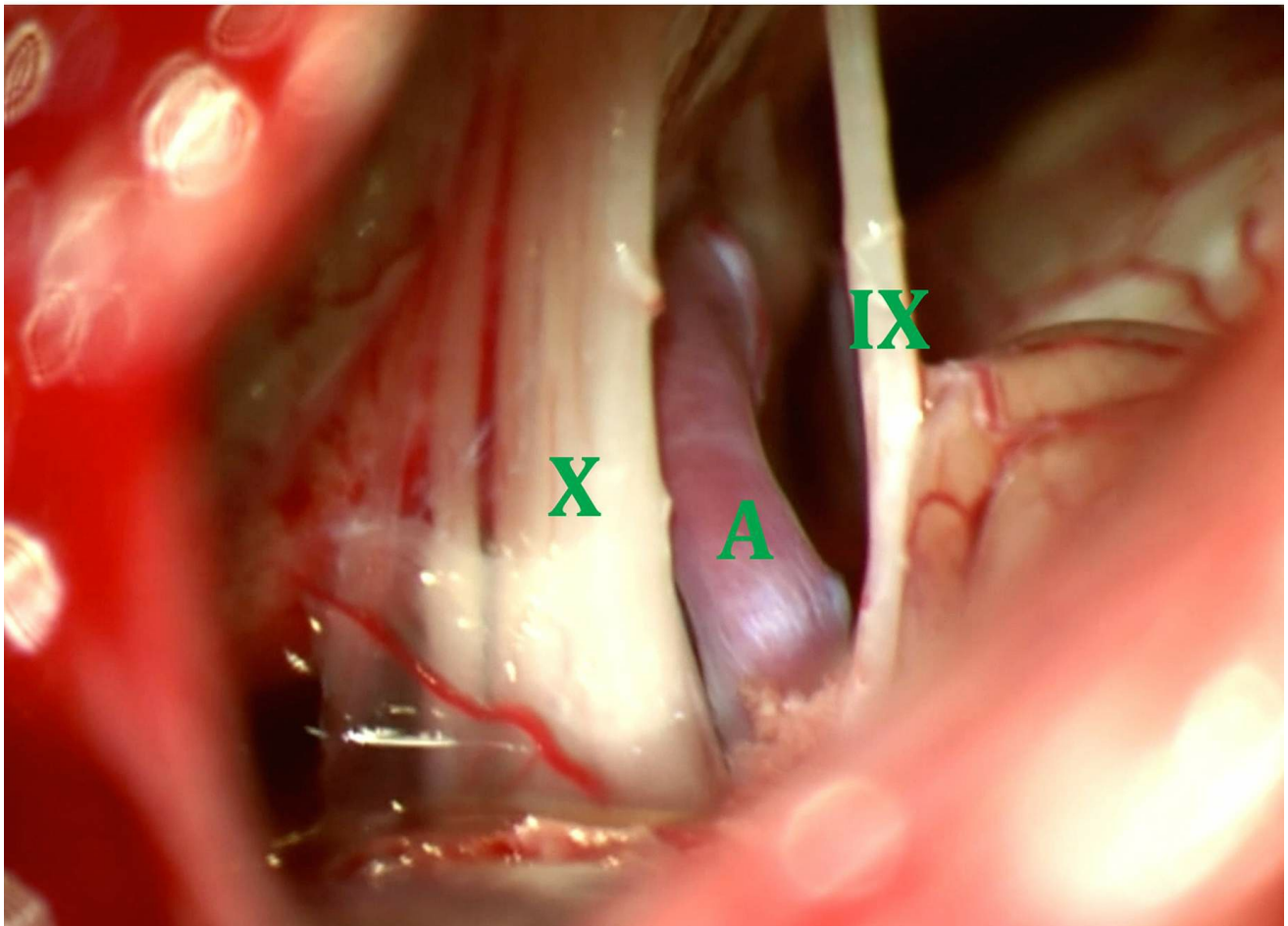
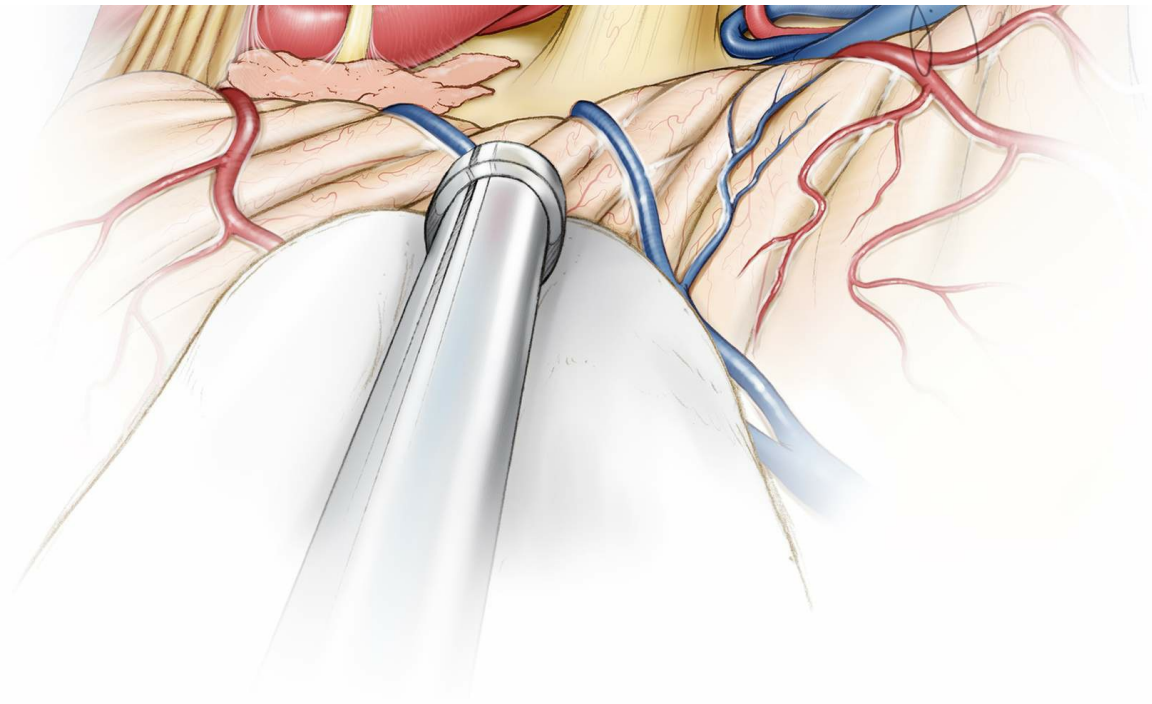

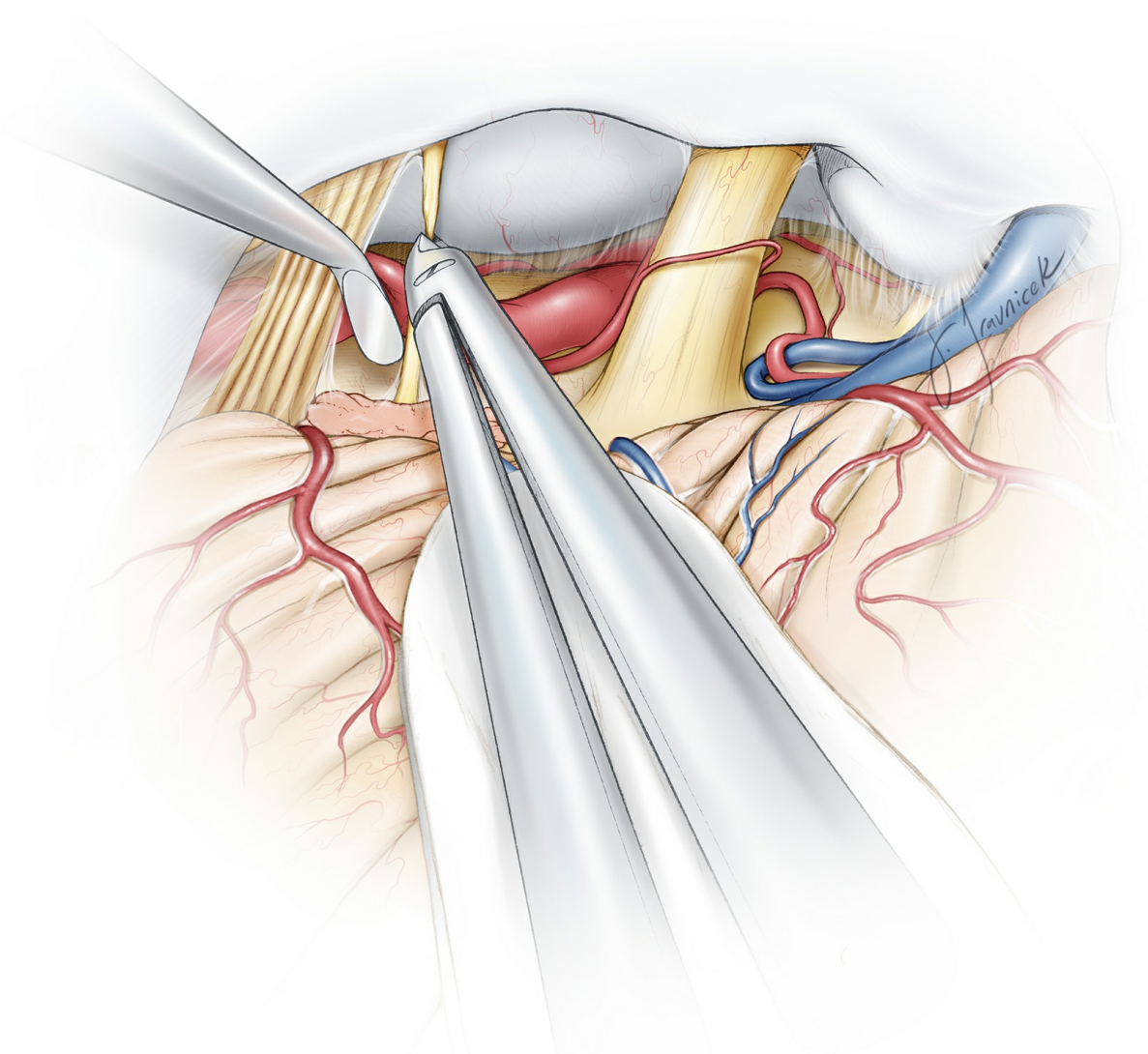


Figure 10: Once the arachnoid membranes are dissected, the anatomy of the lower cranial nerves in relation to CN VII/VIII complex should be easily appreciated (top image). The offending artery (A) is usually apparent between CN's IX and X. The arachnoid bands between CN's IX and X must be sharply transected and the nerves clearly identified and

separated (bottom image). Given the variations that could be present, it is important to correctly identify cranial nerves before CN IX transection and CN X decompression is undertaken.

There are several ways to distinguish CN IX from CN X:

1. The entrance porus of CN IX is at the cranial portion of the jugular foramen, and hence, it is closest to CN VIII.
2. The porus of CN IX is separated from those of CN's X and XI by a dural crest. The crest might not always be apparent intraoperatively. However, the only location where CN IX can be consistently distinguished from CN X is just proximal to the dural meati and crest.



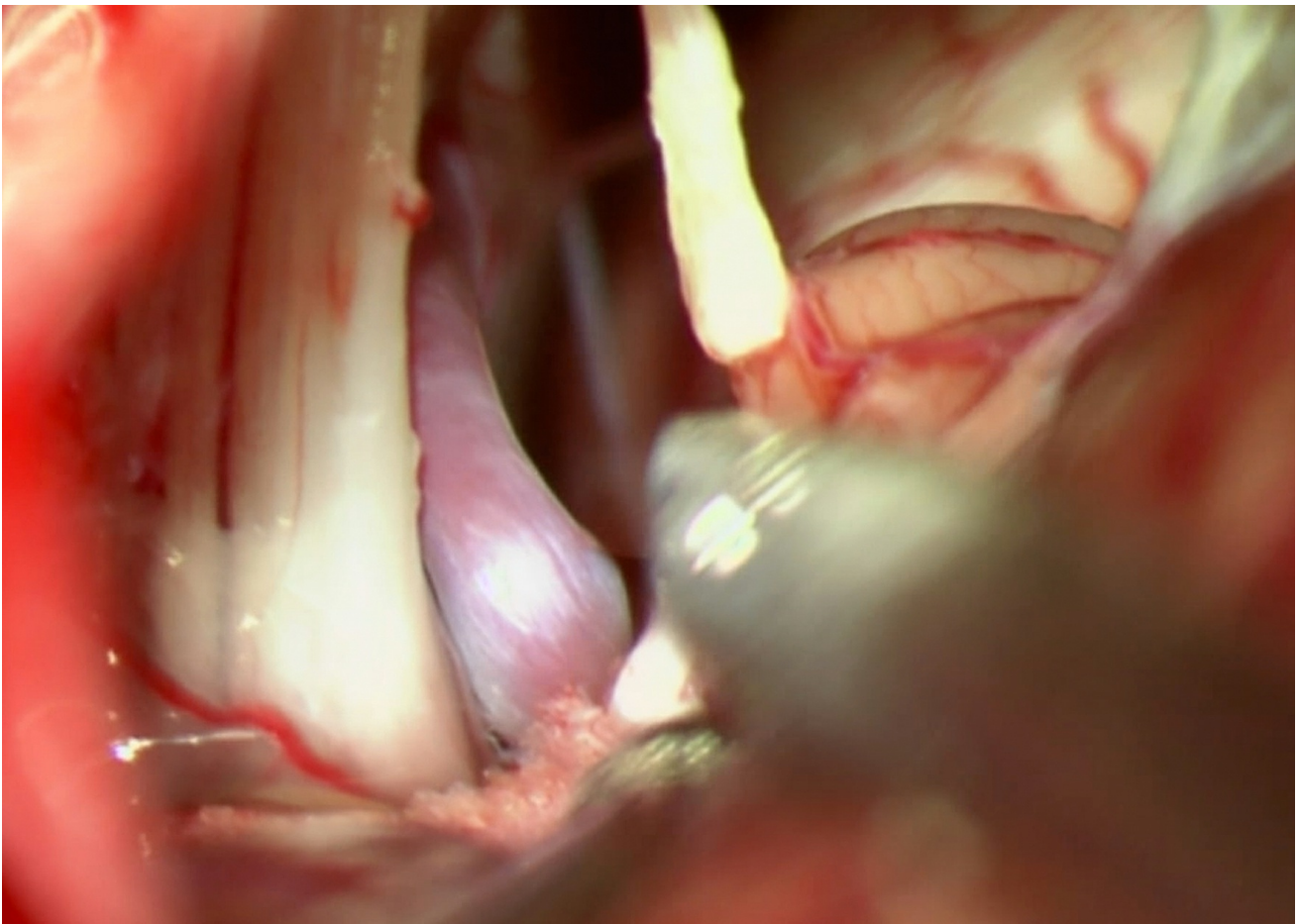


Figure 11: Once CN's VII through X can be adequately visualized, I sharply divide CN IX close to the brainstem after its coagulation. Before dividing the nerve, I give proper warning to the anesthesiologist since dramatic hypotension or tachycardia is possible, especially among older patients. In my experience, the morbidity risk of severing CN IX is minimal, and this maneuver provides valuable and much needed space to adequately decompress CN X.

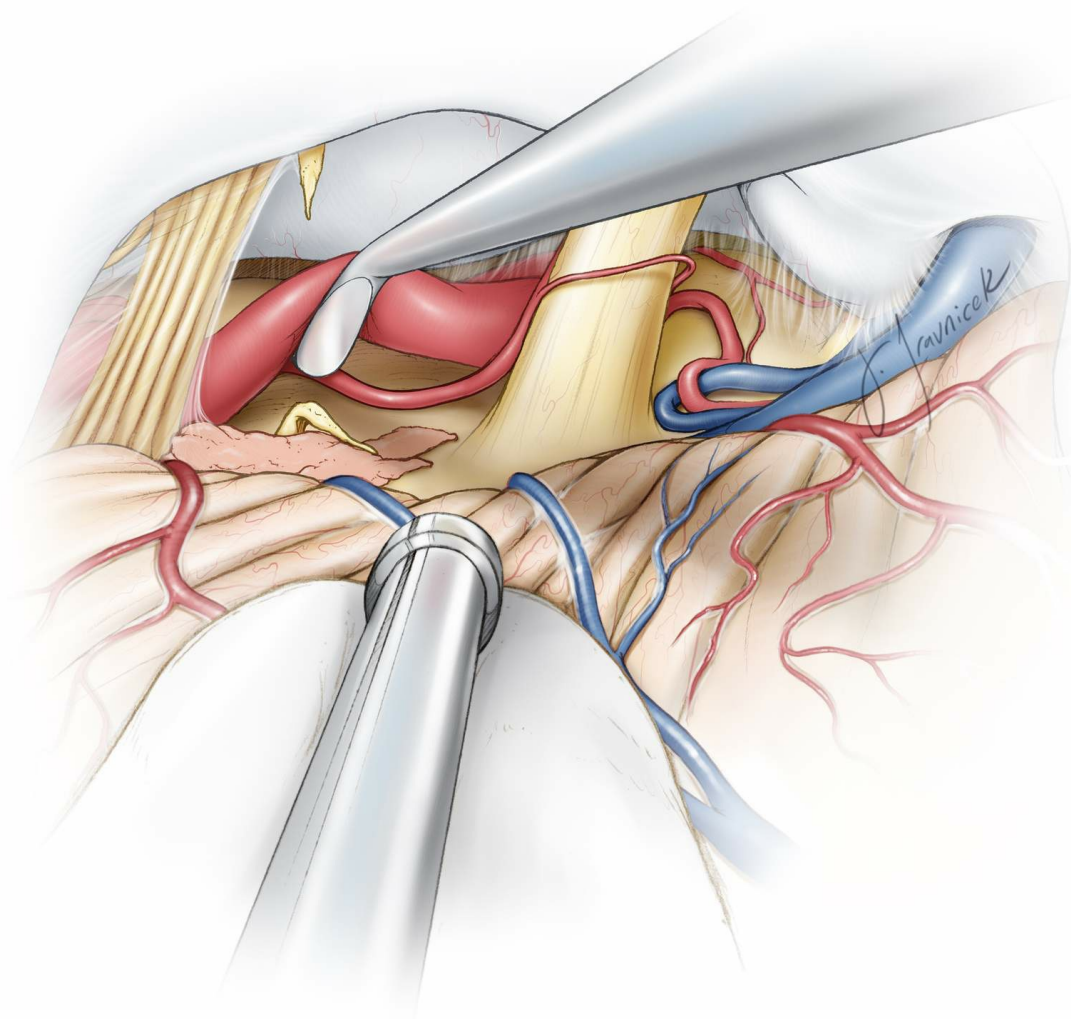
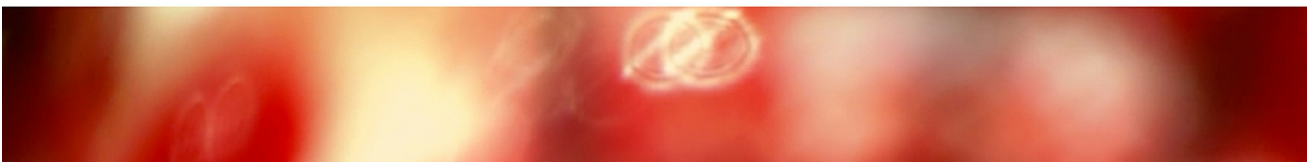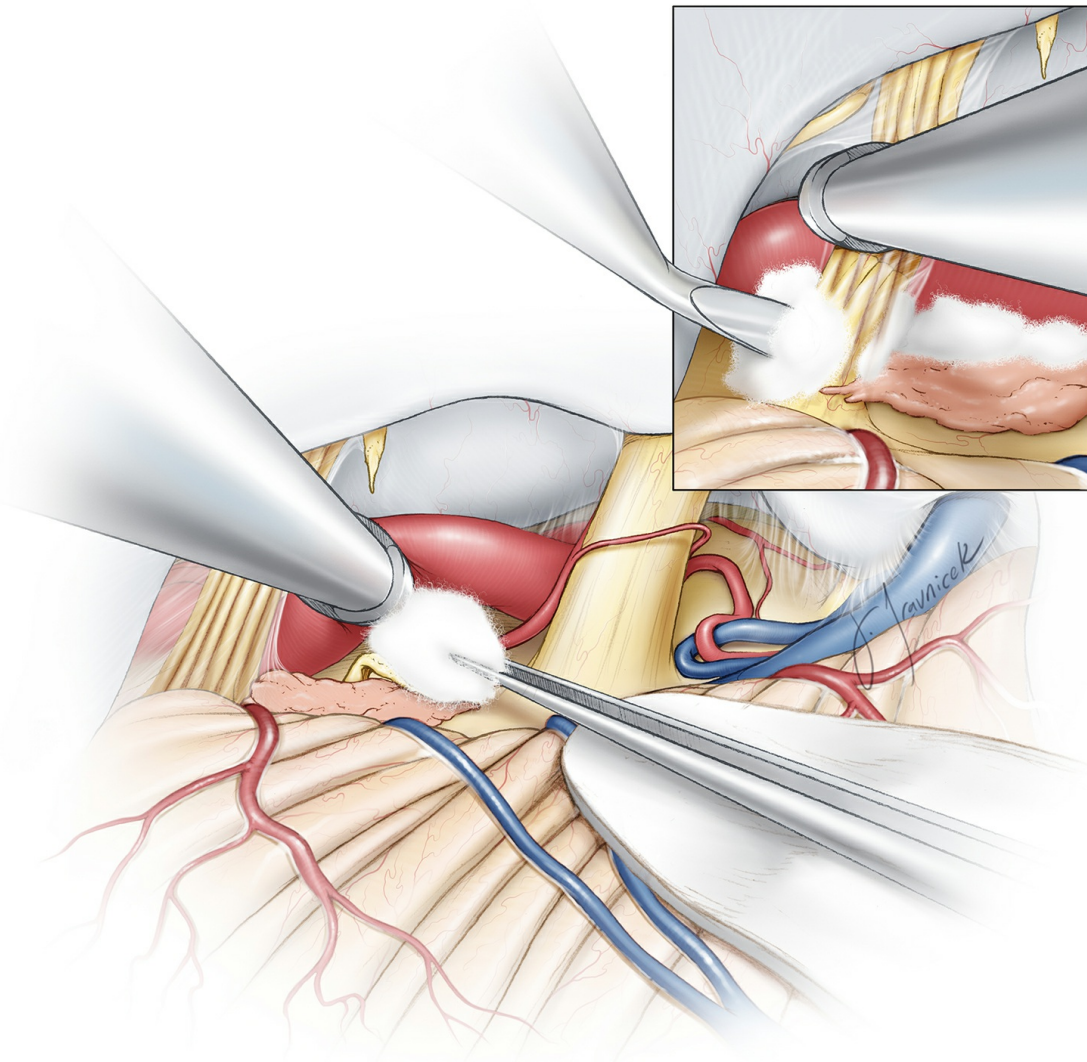


Figure 12: I then proceed to mobilize the offending vascular loop away from the CN X root exit zone along the lower brainstem. **Some operators advocate transection of the upper two rootlets of CN X, if no obvious vascular compression is found. However, I have abandoned this practice due to its associated high risk of postoperative hoarseness and vocal cord paresis.** With appropriate patient selection for surgery, I have always found a convincing vascular loop along the root exit zone of CN X.

I pay particular attention to the perforating vessels coming off of the PICA and vertebral arteries as their injury should be avoided. The cranial nerves should be examined along their entire exposed cisternal segment. Inexperienced surgeons can easily overlook the area of the brainstem due to its inaccessibility and therefore accomplish an inadequate decompression.

To avoid untoward traction on CN X, in most cases, direct exposure of its root exit zone might not be feasible; however, inspection of the cerebellomedullary fissure along the shoulder of the nerve will reveal a vascular loop causing neurovascular conflict at the root exit zone of CN X. This arterial loop must be carefully mobilized away from the root exit zone, protecting the associated perforators. A fear of cerebellar retraction should not justify inadequate exposure and decompression. Careful dissection of the medial arachnoid membranes and strategic dynamic cerebellar retraction will lead to identification of the specific offending vessels.



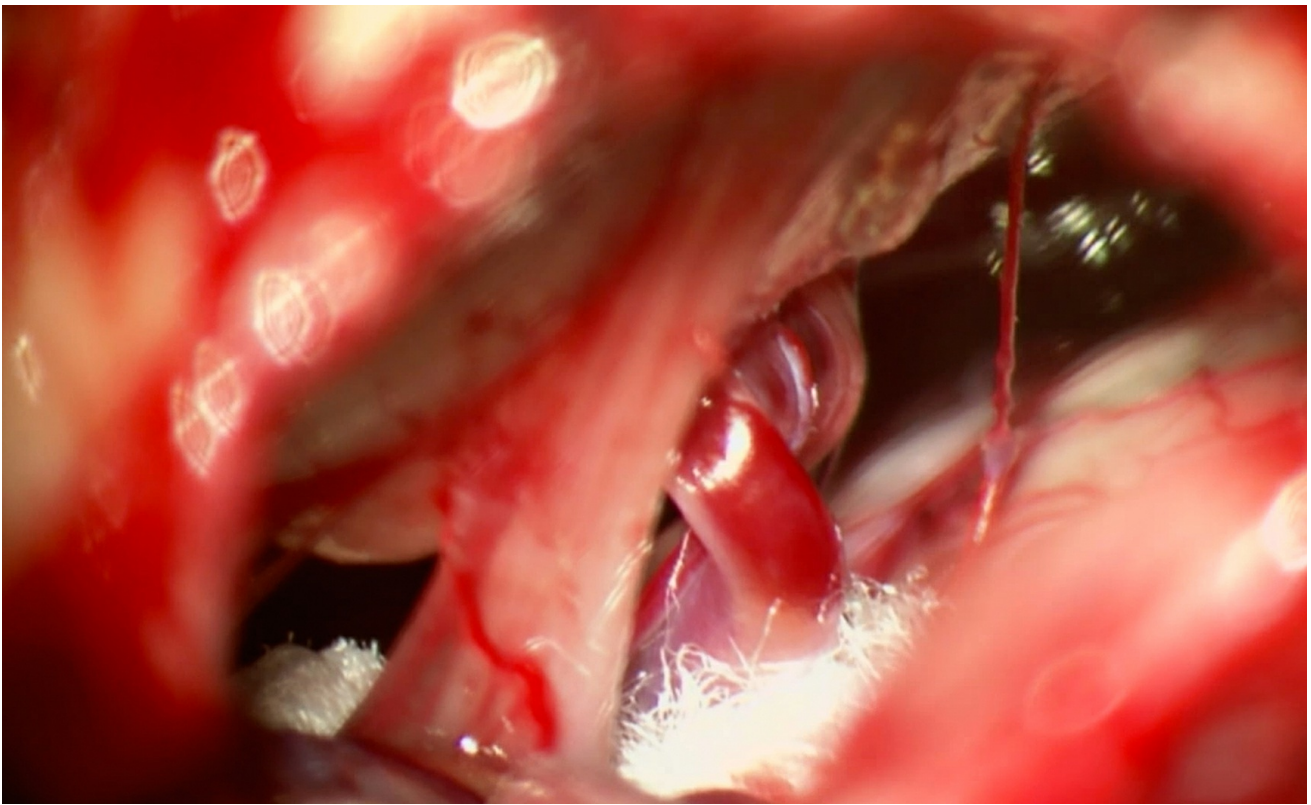

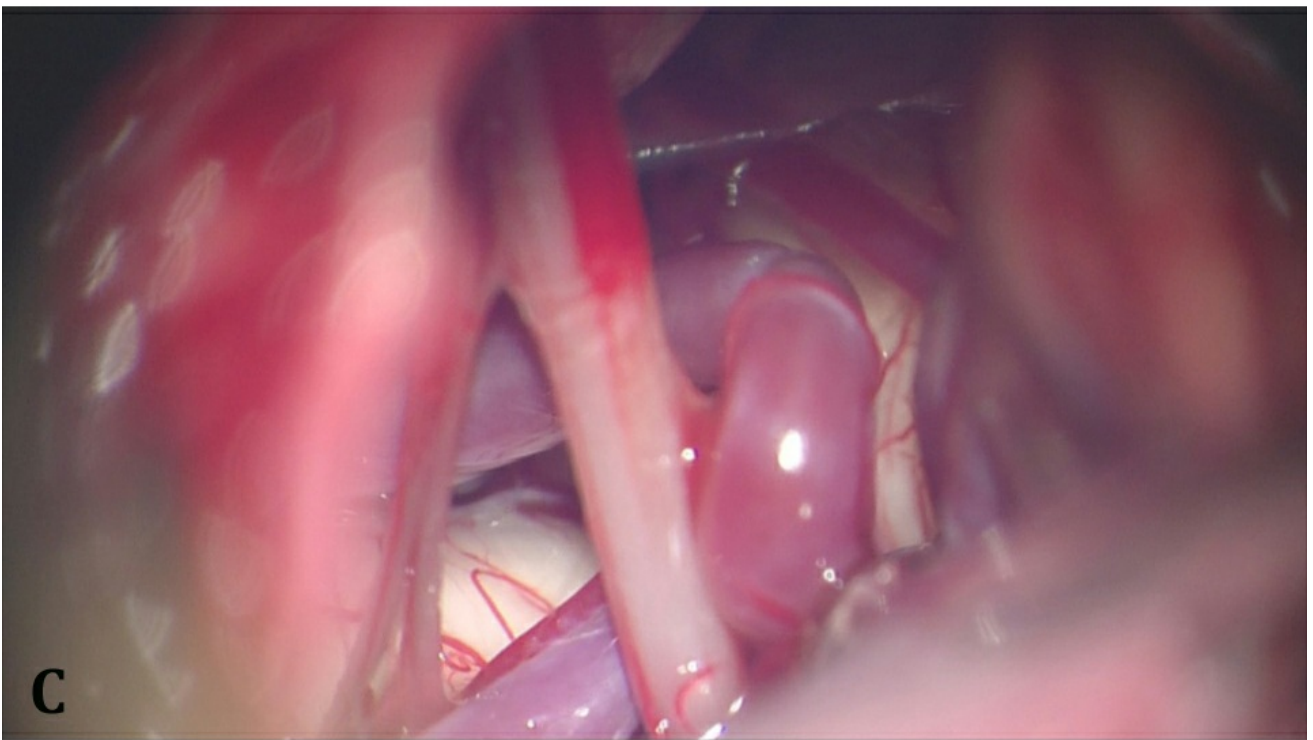
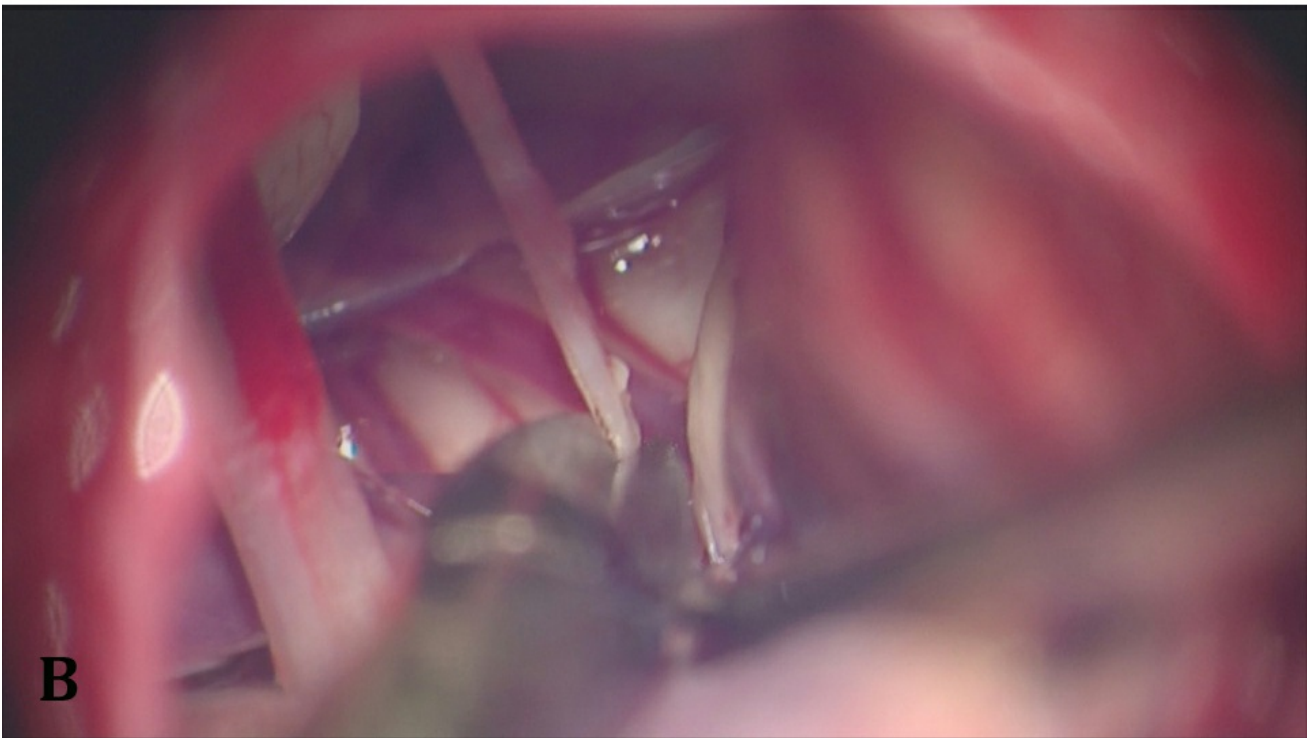
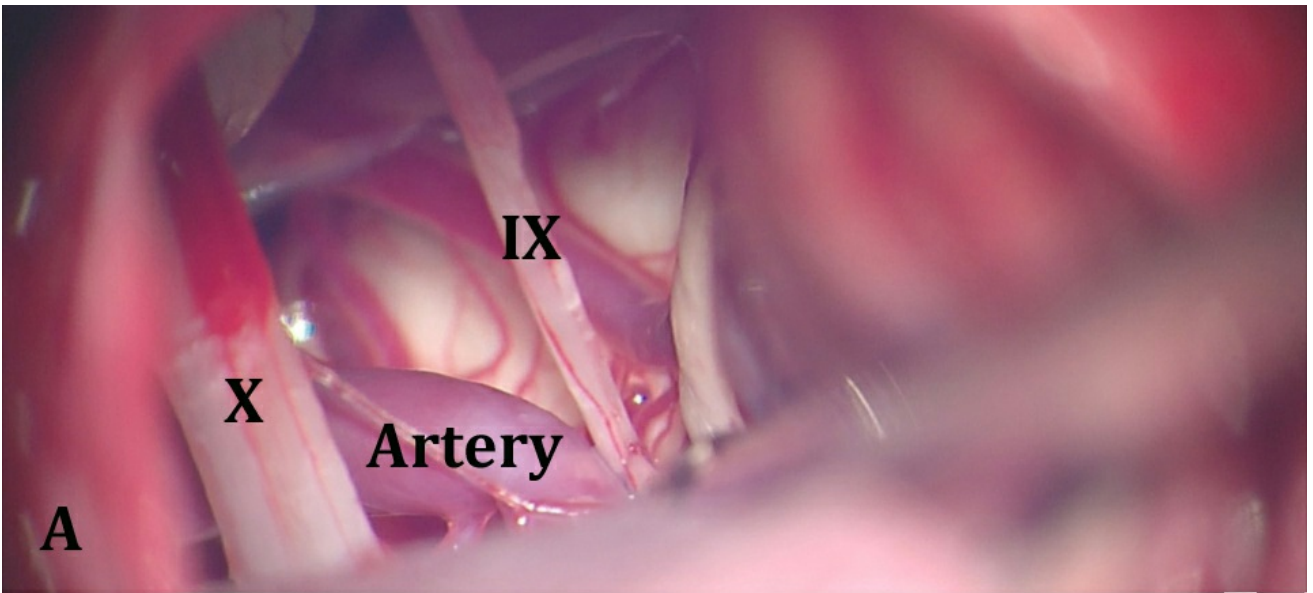


Figure 13: To thoroughly relieve the neurovascular conflict, I implant multiple pieces of shredded Teflon while working above and below CN X. Teflon is also placed between the brainstem and the offending loop at the level of CN X (top image-inset). Sequential introduction of these pieces of Teflon helps with mobilization of the vessel and prevents its return to its original position (bottom image). An excessive amount of Teflon should be avoided as it can cause an inflammatory reaction and chemical meningitis.

Large vertebral artery or PICA offending vessels may not be readily mobilized using pieces of Teflon. I have not been able to safely use the sporadically reported “sling” methods to prepare the sling around the vessel and suture the sling to the petrous dura to move the vessel. I do not recommend such an attempt due to the limited space available and the attended risks to the vital neighboring cerebrovascular structures. If a large tortuous vessel is encountered, I do my best to pad the vessel using shredded Teflon. I am usually able to consult patients regarding the lower chance of pain freedom based on the finding of the large vessel on the preoperative MRI.





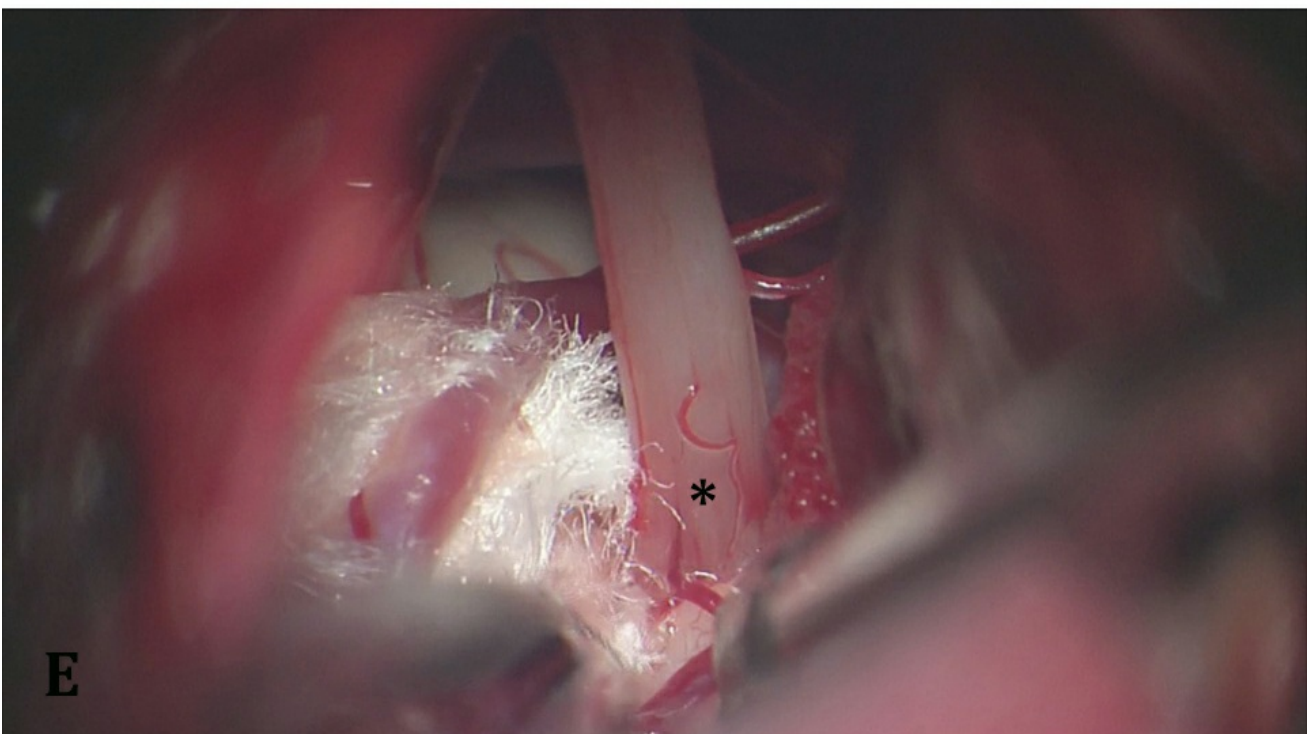
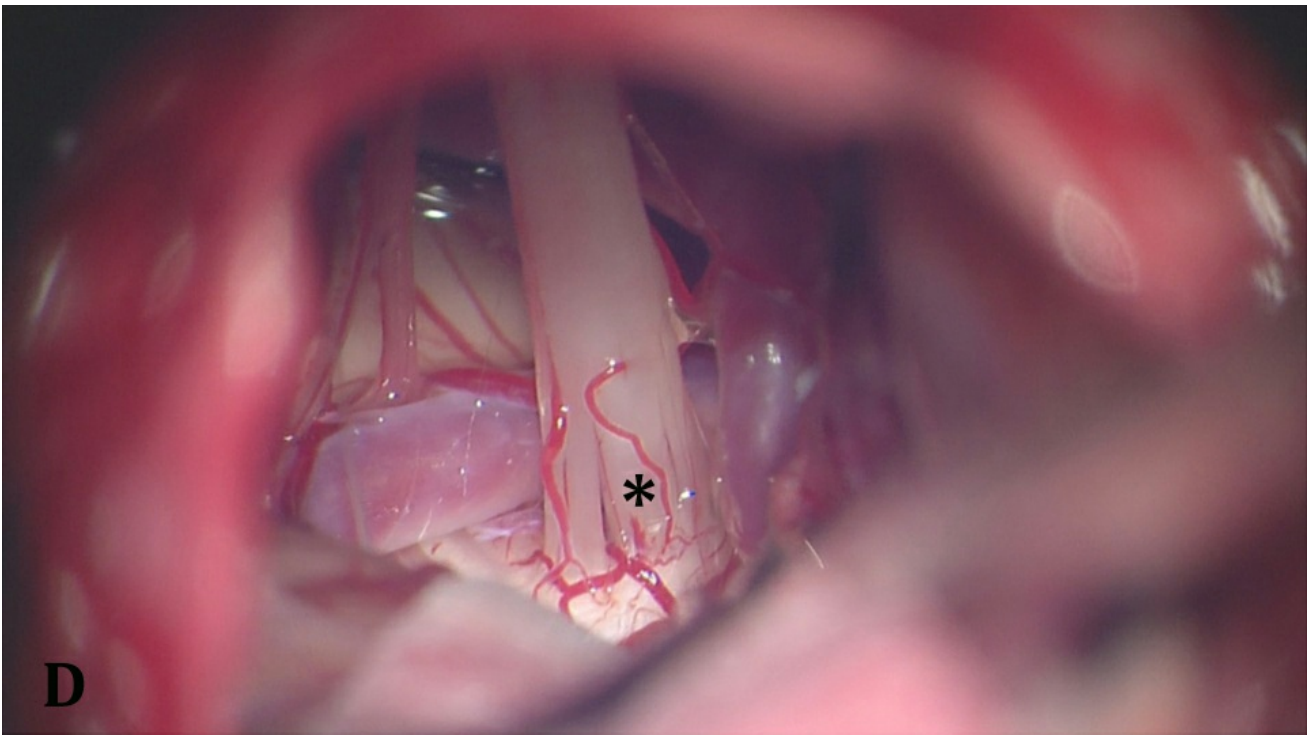


Figure 14: Intraoperative findings in another case of left-sided GN. Neurovascular conflict is apparent upon opening of arachnoid membranes around the lower cranial nerves (A). Transection of CN IX (B) and vascular conflict at the level of the brainstem (C). Dynamic retraction allows excellent exposure of the root exit zone of CN X and discoloration of the nerve exit zone (*) (D). Please note the nerve fibers are separated by the offending vessel. Insertion of Teflon pledgets assures adequate resolution of the conflict near the brainstem (E).

Closure

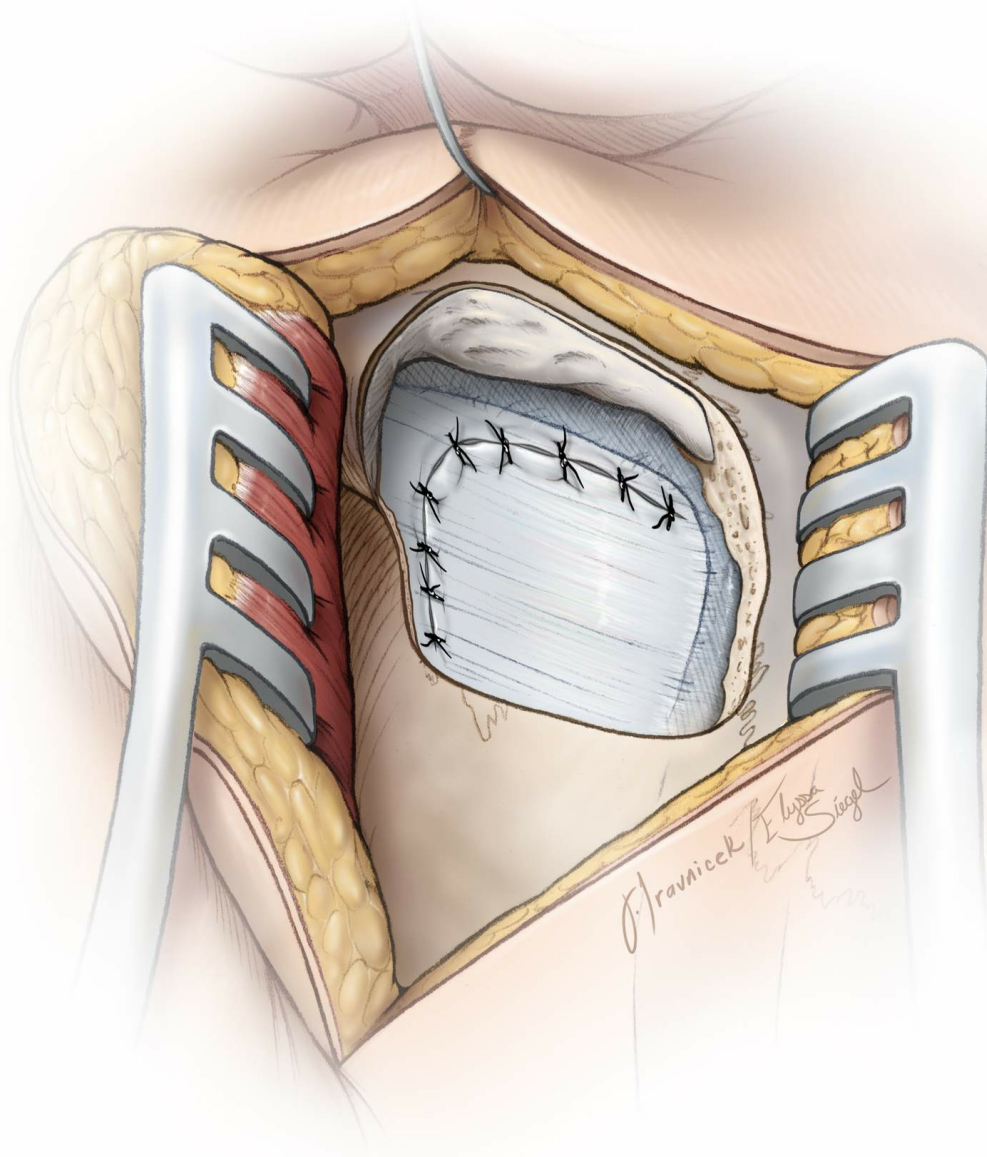


Figure 15: Dural closure

The dura is approximated primarily. I do not perform a "watertight" dural closure and have experienced a very low rate of cerebrospinal fluid (CSF) leak for microvascular decompression operations. Mastoid air cells are rewaxed thoroughly ("wax in, wax out") and the bone flap is replaced or a methylmethacrylate cranioplasty is performed. The muscle and scalp are closed in anatomical layers.

Postoperative Considerations

Patients are usually admitted to the neuro intensive care unit for an overnight stay for observation and then transferred to a regular ward for a

couple of days before they can be discharged home. Special attention should be paid to hemodynamic parameters, neurologic examination, and wound care. Some patients may develop transient hoarseness or dysphagia. It is reasonable to assess the patient's swallowing status before commencing an oral diet to minimize the risk of aspiration.

Cerebrospinal fluid leak is an uncommon complication; if the patient suffers from CSF otorrhea or rhinorrhea, I return him or her to the operating room immediately to close the dura in a "water-tight" fashion and rewrap the mastoid air cells. If CSF is leaking from the wound, the wound is initially oversown and a lumbar drain is instituted for 72 hours. If CSF continues to drain from the wound despite these measures, the patient is returned to the operating room for wound exploration and "water-tight" closure of the dura, muscle, and skin layers.

Pearls and Pitfalls

- Glossopharyngeal neuralgia is a rare cranial nerve hyperactivity disorder characterized by severe, lancinating, paroxysmal pain in the areas supplied by the auricular and pharyngeal branches of CN's IX and X.
- Symptoms of various cranial neuralgias can overlap; hence, every possible effort should be made to reach a correct diagnosis based on history, physical examination, trigger points, imaging studies, and nerve blocks. Incorrect diagnosis will lead to erroneous treatment and result in frustration for both patient and surgeon.
- I have found transection of CN IX and decompression of CN X effective for safe relief of GN.
- The cerebellum should be retracted only parallel to the direction of CN IX to avoid traction on CN VIII, leading to hearing loss. Sharp arachnoid dissection and strategic dynamic cerebellar retraction will facilitate cerebellar mobilization without placing the cranial nerves at risk. These maneuvers will allow adequate exposure of the medial lower brainstem to allow safe mobilization of the offending vascular loop and Teflon implantation.

Contributor: Aqueel Pabaney, MD

DOI: <https://doi.org/10.18791/nsatlas.v6.ch03>

REFERENCES

Blumenfeld A, Nikolskaya G. Glossopharyngeal neuralgia. *Curr Pain Headache Rep.* 2013;17:343.

Hitotsumatsu T, Matsushima T, Inoue T. Microvascular decompression for treatment of trigeminal neuralgia, hemifacial spasm, and glossopharyngeal neuralgia: Three surgical approach variations: Technical note. *Neurosurgery.* 2003;53:1436-1441.

Rey-Dios R, [Cohen-Gadol AA](#). Current neurosurgical management of glossopharyngeal neuralgia and technical nuances for microvascular decompression surgery. *Neurosurg Focus.* 2013;34:E8.

Rhoton, A. Jugular foramen. *Neurosurgery.* 2000;47:S267-285.

Rhoton A. The cerebellopontine angle and posterior fossa cranial nerves by the retrosigmoid approach. *Neurosurgery.* 2000;47:S93-129.

Sampson JH, Grossi PM, Asaoka K, Fukushima T. Microvascular decompression for glossopharyngeal neuralgia: long-term effectiveness and complication avoidance. *Neurosurgery.* 2004;54:884-889.

Teixeira MJ, de Siqueira SR, Bor-Seng-Shu E. Glossopharyngeal neuralgia: neurosurgical treatment and differential diagnosis. *Acta Neurochir (Wien).* 2008;150:471-475.

Xiong NX, Zhao HY, Zhang FC, Liu RE. Vagoglossopharyngeal neuralgia treated by microvascular decompression and glossopharyngeal rhizotomy: clinical results of 21 cases. *Stereotact Funct Neurosurg.* 2012;90:45-50.

Related Materials

Available Through the Atlas

 Microvascular decompression of cranial nerves: Lessons learned af...

 Follow-up results of using microvascular decompression for treatm...

 Current neurosurgical management of glossopharyngeal neuralgia an...

 Vagoglossopharyngeal neuralgia treated by microvascular decompres...

 Intraoperative and anatomical descriptions of intracranial connec...

Unavailable Through the Atlas

 Microvascular decompression for glossopharyngeal neuralgia

 Is the root entry/exit zone important in microvascular compressio...

 Microvascular decompression in the management of glossopharyngeal...

 Microvascular Decompression for Glossopharyngeal Neuralgia: Long-...

 Microvascular decompression for glossopharyngeal neuralgia: A lon...
