



Orbitozygomatic Craniotomy

Last Updated: June 22, 2021

General Considerations

The orbitozygomatic craniotomy (OZ) involves an expansion of the pterional approach through osteotomy of various sections of the superior/lateral orbital rim/roof and zygoma. This additional bone removal broadens the subfrontal trajectory and minimizes the need for brain retraction to access the floor of the anterior and middle skull base as well as the parasellar and interpeduncular spaces. It also allows an enhanced inferior-to-superior operative trajectory and working angles with flexible multidirectional degrees of operative freedom.

Multiple variations of the OZ have been described involving different amounts of bone work. **The most widely used and practical modifications are the “one” and “two-piece” supraorbital osteotomies with limited resection of the zygoma. These modified variations involve mobilization of the orbital roof and rim as well the frontal process of zygoma.**

In the one-piece osteotomy, the frontotemporal craniotomy and supraorbital osteotomy are completed as one bone flap. In the two-piece osteotomy, a traditional pterional craniotomy is first elevated, followed by the supraorbital osteotomy. **The one-piece frontotemporal craniotomy and supraorbital osteotomy (referred to as modified OZ) is the least disruptive alternative and provides most of the advantages of all the other OZ variations and will be reviewed here.**

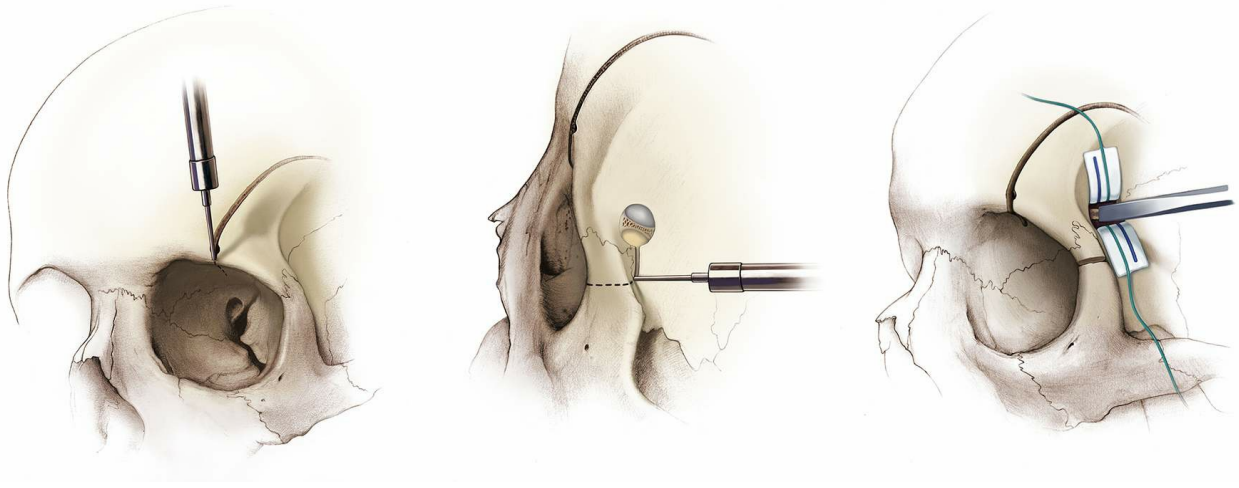


Figure 1: Shown are fundamental osteotomy locations for the one-piece modified OZ. The first osteotomy (left image) cuts across the orbital rim. The second osteotomy (middle image) disconnects the frontal process of the zygoma, and the last cut (right image) is across the roof of the orbit through an expanded keyhole. The “key” location of the keyhole for exposing the orbit and frontal dura is important for planning subsequent osteotomies. These bony cuts lead to disarticulation of the orbital rim, zygoma, and orbital roof.

My colleagues have generously described many modifications of this skull base approach, but these descriptions often confuse novice surgeons. I will attempt to simplify this versatile skull base approach with a special emphasis on *its selective and judicious applications*.

Indications for the Modified Orbitozygomatic Osteotomy

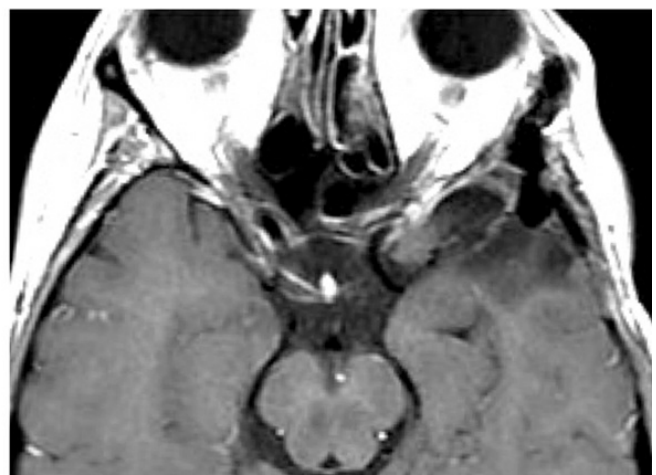
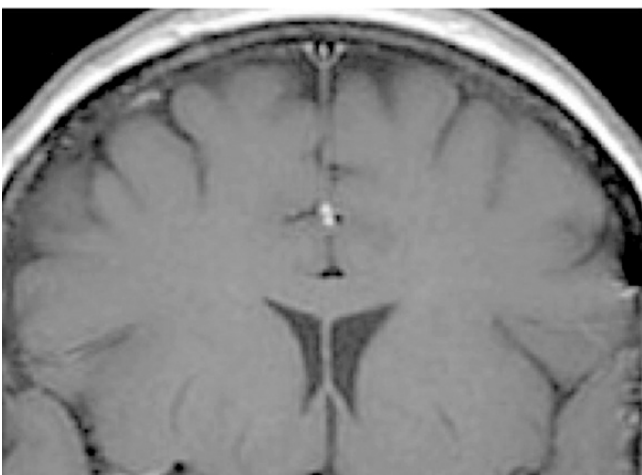
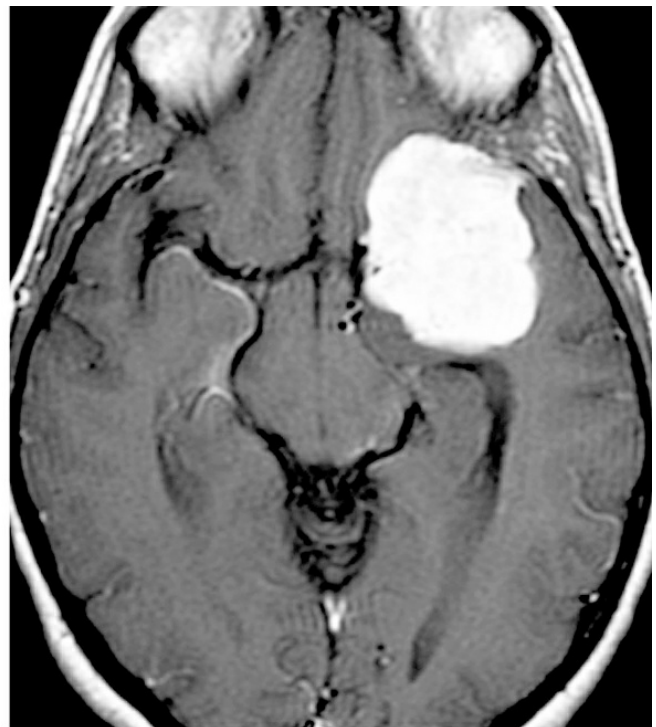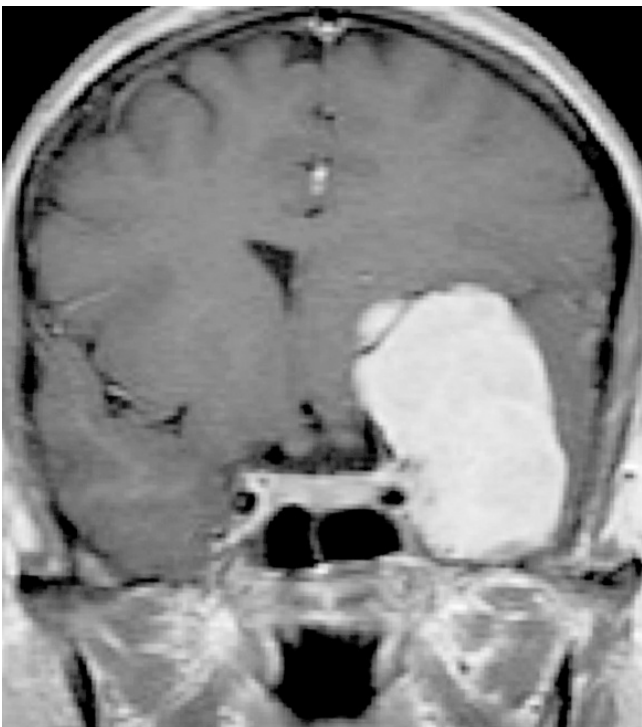
Modifications of the OZ have been widely used for both vascular and neoplastic lesions within the orbital apex, paraclinoid and parasellar regions, cavernous sinus as well the interpeduncular and upper paraclivus territories. Cranial base masses with tremendous superior extension can benefit from the expanded inferior-to-superior operative trajectory and from the medial-to-lateral operative working angles of the OZ pathway; OZ mitigates the vector of retraction on the frontal lobes.

I recommend the use of one-piece modified OZ. A complete zygomatic osteotomy of the temporal portion of the zygomatic arch does not significantly add to the exposure. In fact, temporal zygomatic osteotomy can be redundant for exposure of most lesions and increases the risk of

cosmetic deformity.

I do not routinely use the OZ for lesions that can be exposed through the [extended pterional craniotomy](#). The extended pterional craniotomy requires aggressive drilling of the roof of the orbit and lateral sphenoid wing; these two maneuvers expand the reach of the standard pterional corridor.

I selectively use the modified OZ for parasellar lesions extending superiorly into the third ventricular space and orbital lesions within the posterior one-third of the orbit. More specifically, I use this approach for giant parasellar meningiomas or “high-riding” basilar apex aneurysms, as well as posterior intraorbital meningiomas/cavernous hemangiomas. The lesions within the cavernous sinus can also benefit from the modified OZ. As you can see, the list is relatively short and selective.



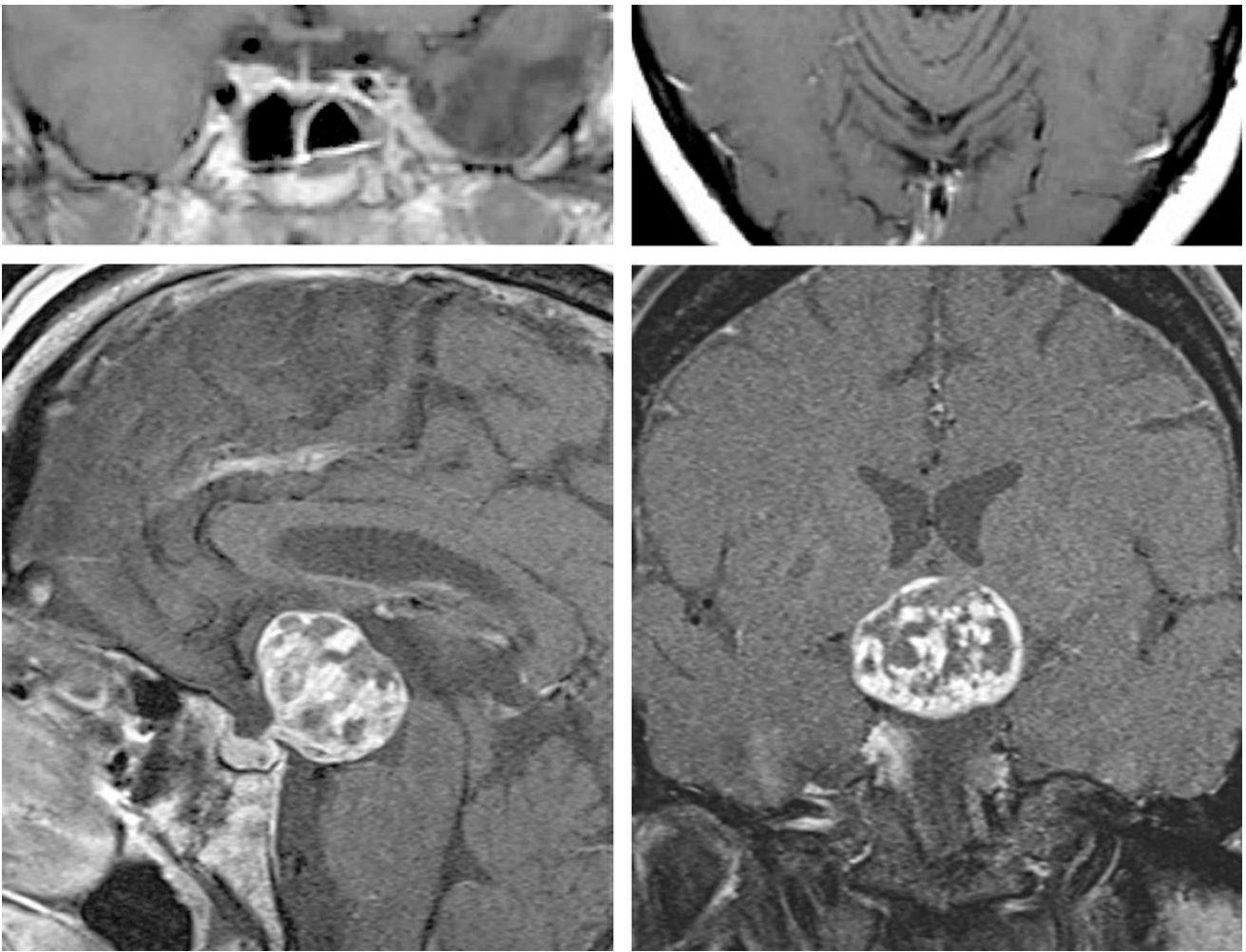


Figure 2: This large medial sphenoid wing meningioma (top photos) was resected via the modified OZ (middle photos). The significant superior extension of the tumor required a steep inferior-to-superior intradural operative trajectory afforded through the orbital trim osteotomy. Similarly, this third ventricular craniopharyngioma (bottom images) was removed via the same approach through the lamina terminalis.

Preoperative Considerations

Meningiomas can lead to hyperostosis of the roof of the orbit and lateral sphenoid wing; this finding should be evaluated on preoperative imaging. If the modified OZ is performed for resection of sphenoid wing and orbital meningiomas, the osteotomy along the orbital roof should be performed under direct vision and not blindly. Due to the increased thickness of the orbital roof, uncontrolled fracture of the roof and rim may extend as far as the optic canal and lead to optic nerve injury. The fracture can also involve the walls of the sphenoid and ethmoid sinuses, generating postoperative CSF leakage.

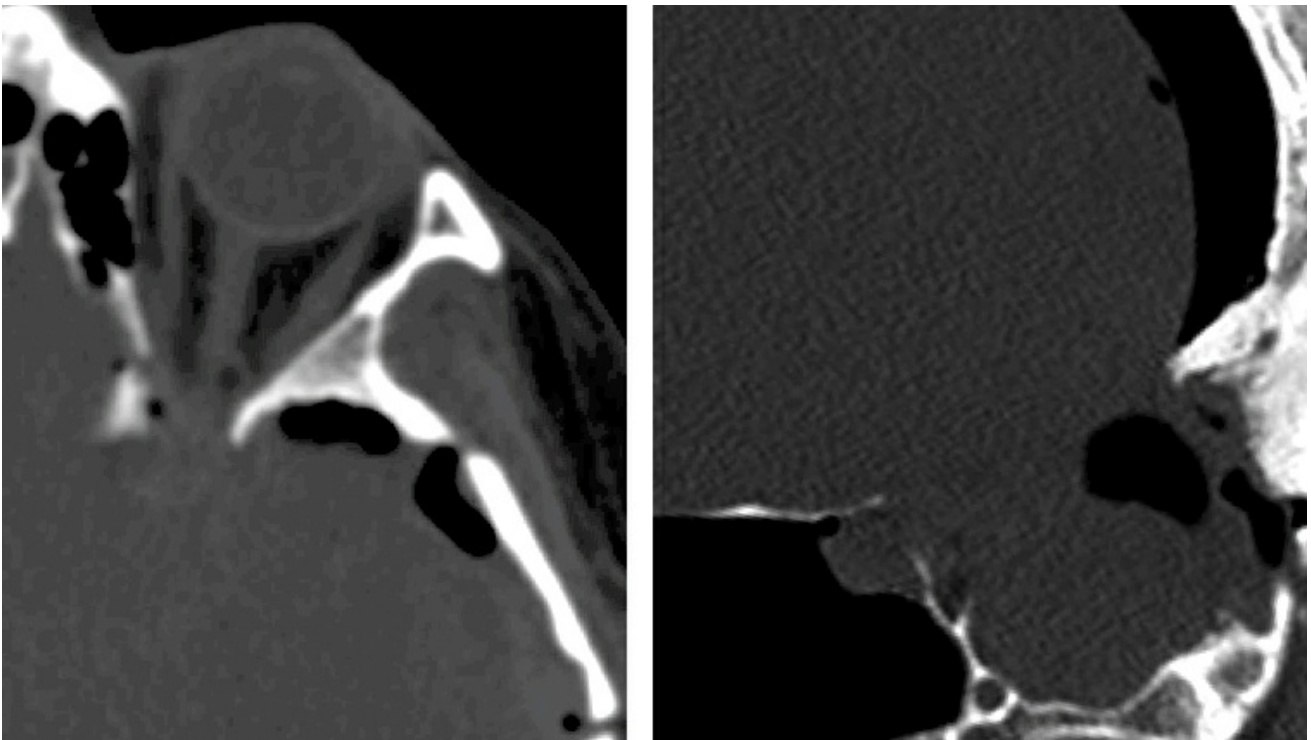


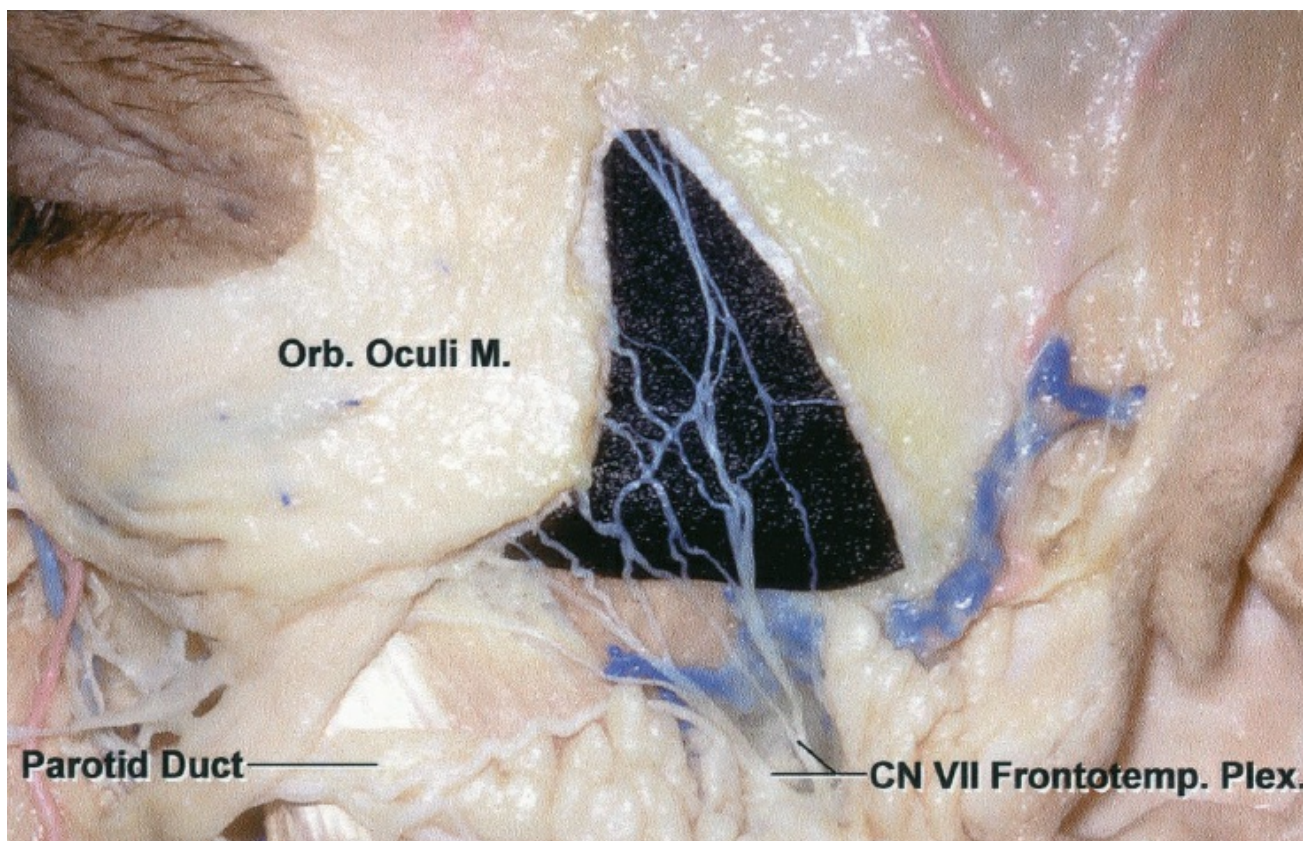
Figure 3: Aggressive elevation of the orbitozygomatic or pterional bone flap without its complete disconnection under direct vision along the orbital roof or lateral sphenoid wing should be avoided. Attempts to blindly fracture the bone flap at its margin at the hyperostotic lateral sphenoid wing in case of sphenoid wing meningiomas can lead to an inadvertent extension of the fracture into the optic canal (left) or ethmoid sinus (right) with resultant optic nerve injury or unrecognized postoperative CSF leak.

I consider the use of a lumbar drain since dural decompression can protect the dura and the brain during OZ osteotomies.

The lateral extent of the frontal sinuses should be studied on preoperative imaging. The risk of the entry into the frontal sinus should not compromise adequate exposure.

Operative Anatomy

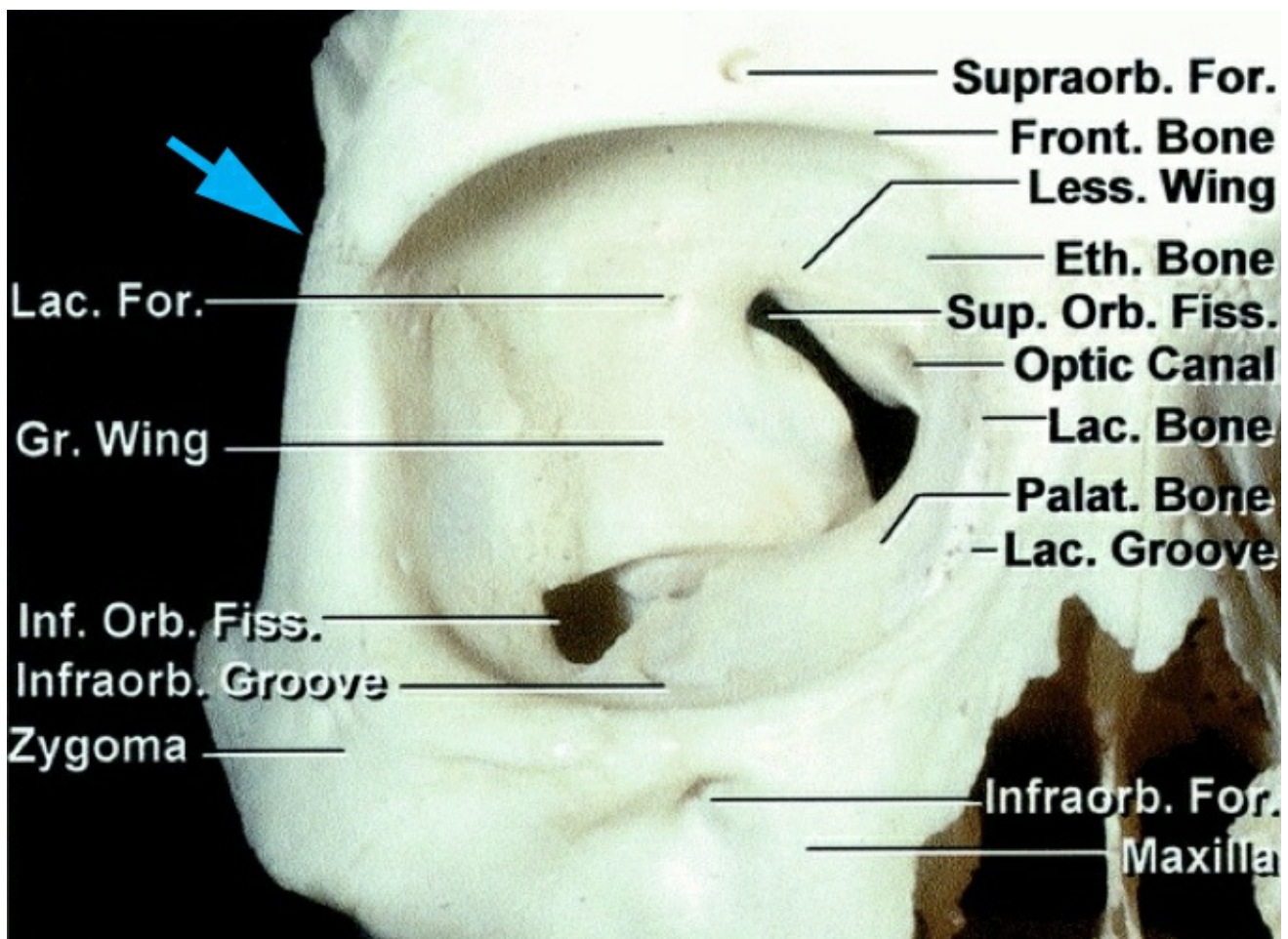
An in-depth understanding of the corresponding anatomy of the anterior skull base is pertinent.



[Click here](#) to view the interactive module and related content for this image.

Figure 4: The anatomy of the frontalis branches of the facial nerve within the superficial fascia of the fat pad is shown. The subfascial technique is used to reflect these branches in a separate layer than that of the temporalis muscle (image courtesy AL Rhoton, Jr).

For further details about the subfascial and interfascial techniques for mobilizing the facial nerve branches, please refer to the chapter on [Pterional Craniotomy](#).



[Click here](#) to view the interactive module and related content for this image.

Figure 5: The modified OZ involves removal of the orbital rim, anterior orbital roof and part of the frontal process of zygoma. This osteotomy may be extended to the level of the inferior orbital fissure, but this is rarely necessary. The frontozygomatic suture (blue arrow) approximates the level of the orbital roof (image courtesy of AL Rhoton, Jr).

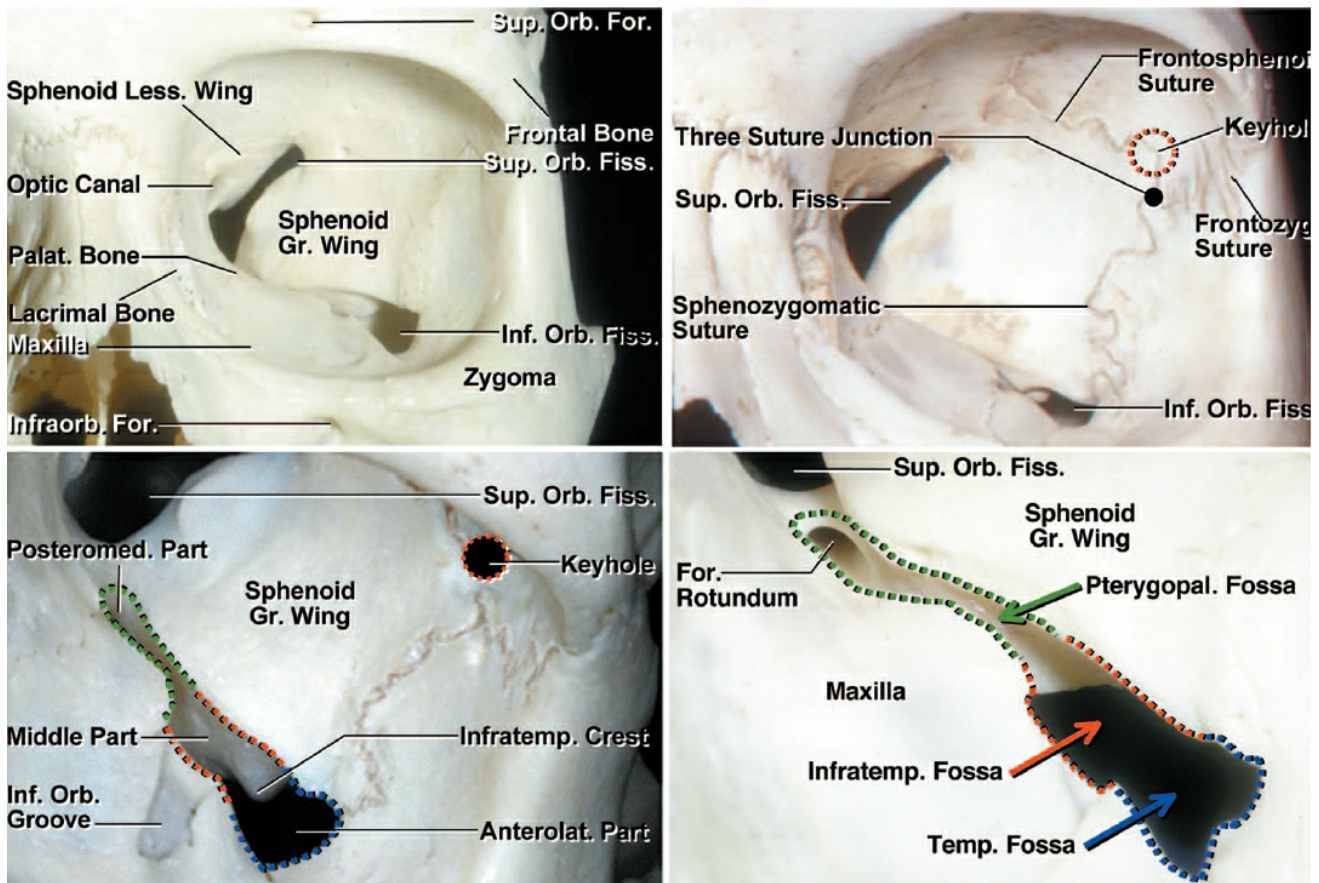


Figure 6: Bony anatomy of the anterolateral skull base (left upper image) as it relates to the OZ is demonstrated. Note the location of the keyhole relative to frontozygomatic suture from inside the orbit (right upper and left lower images). The pterional “keyhole” that exposes only the frontal dura is more superiorly situated than the real McCarty keyhole used for OZ that exposes both the orbit and the frontal dura (images courtesy of AL Rhoton, Jr).

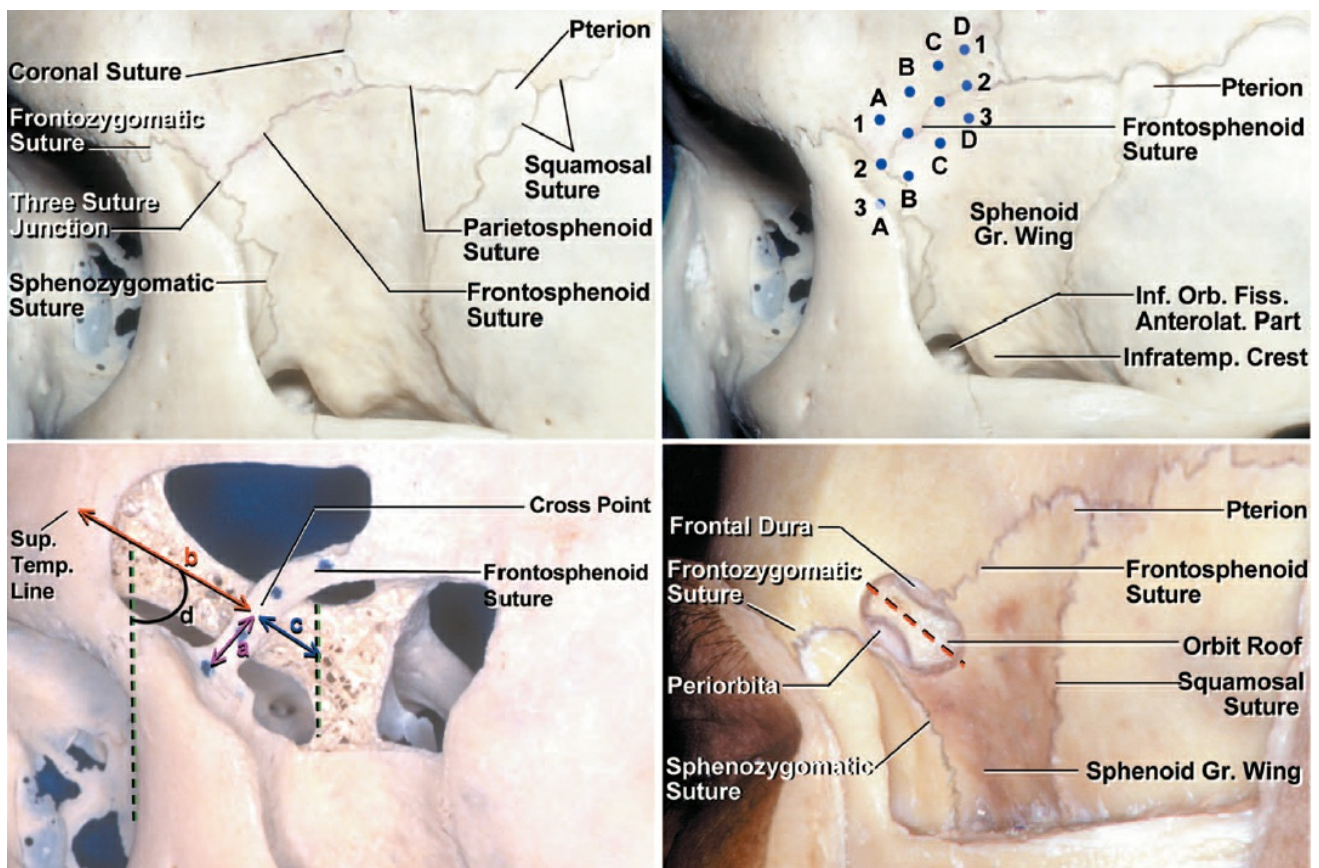


Figure 7: The osteology around the area of the keyhole (left upper image). I find the location of A1 (right upper image) as the most likely place for the keyhole to expose the orbit and the frontal dura separated by the orbital roof. Note the orientation of the orbital roof in relation to the vertical hashed lines (left lower image). The orbital roof has variable thickness and orientation. Its typical oblique orientation should be kept in mind during expansion of the keyhole so that both the frontal dura and the periorbita are exposed (right lower image)(images courtesy of AL Rhoton, Jr).

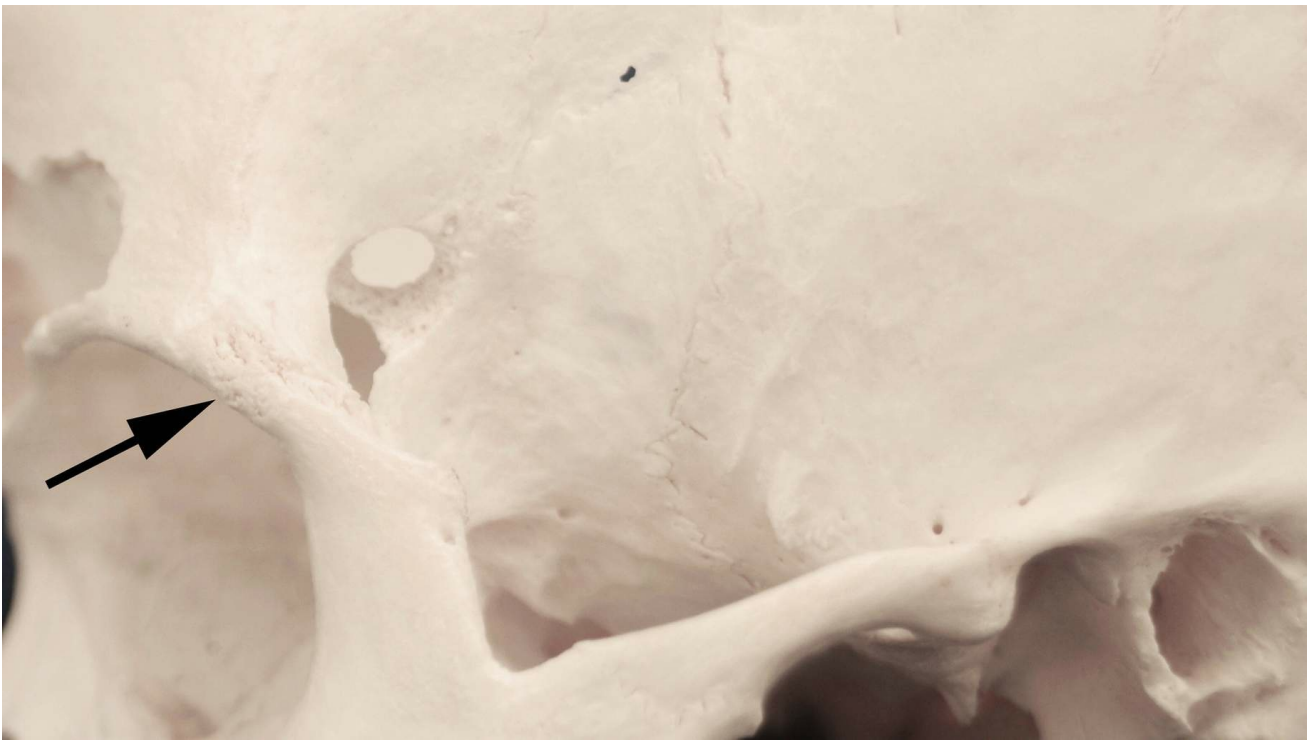


Figure 8: Precise and accurate placement of the initial keyhole to expose the orbit and the frontal dura is the most important step for appropriate and efficient execution of the orbitozygomatic and supraorbital/fronto-orbital craniotomies. The center of the keyhole is usually 7 mm superior and 5 mm posterior to the frontozygomatic suture (black arrow).

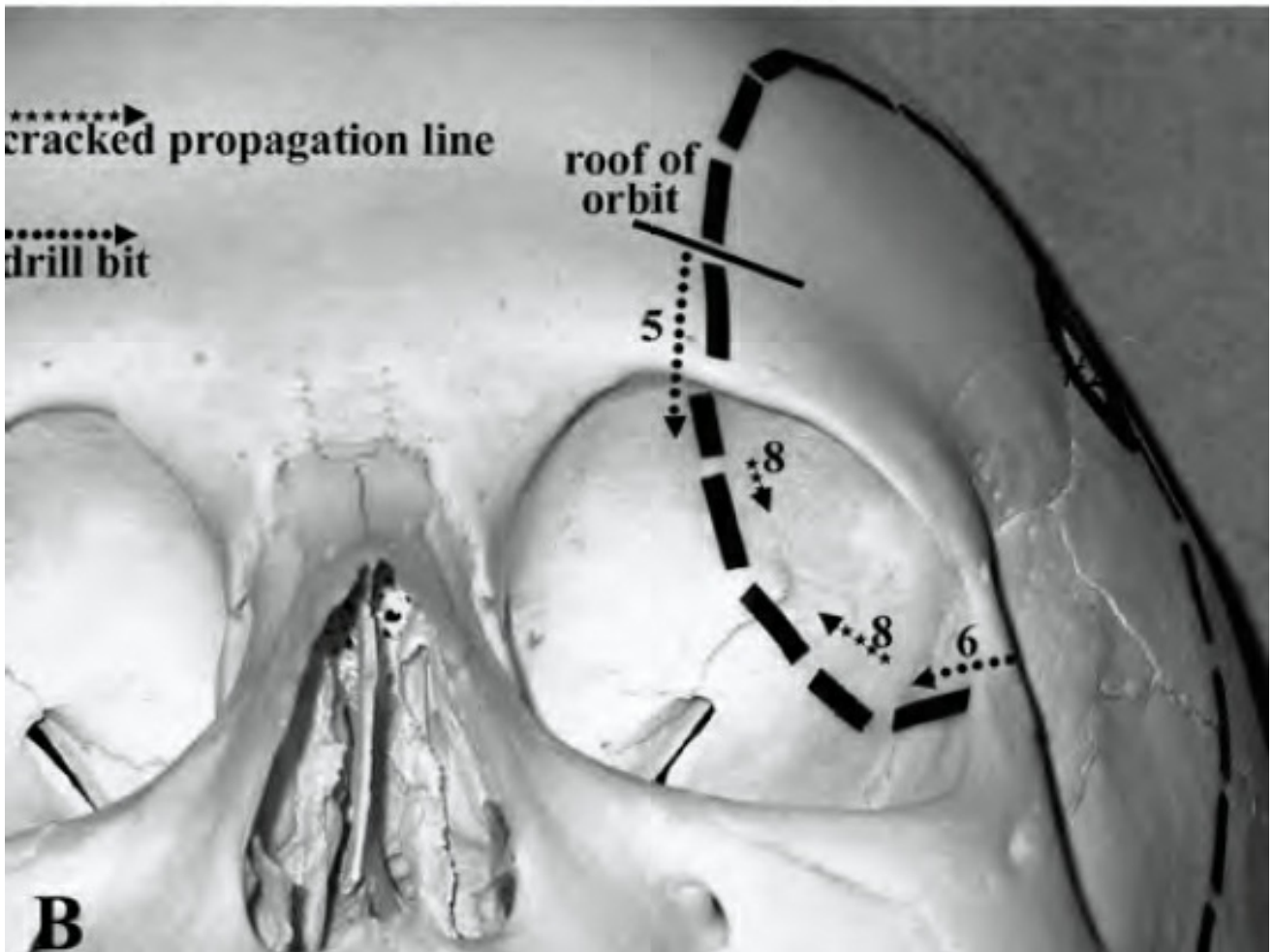
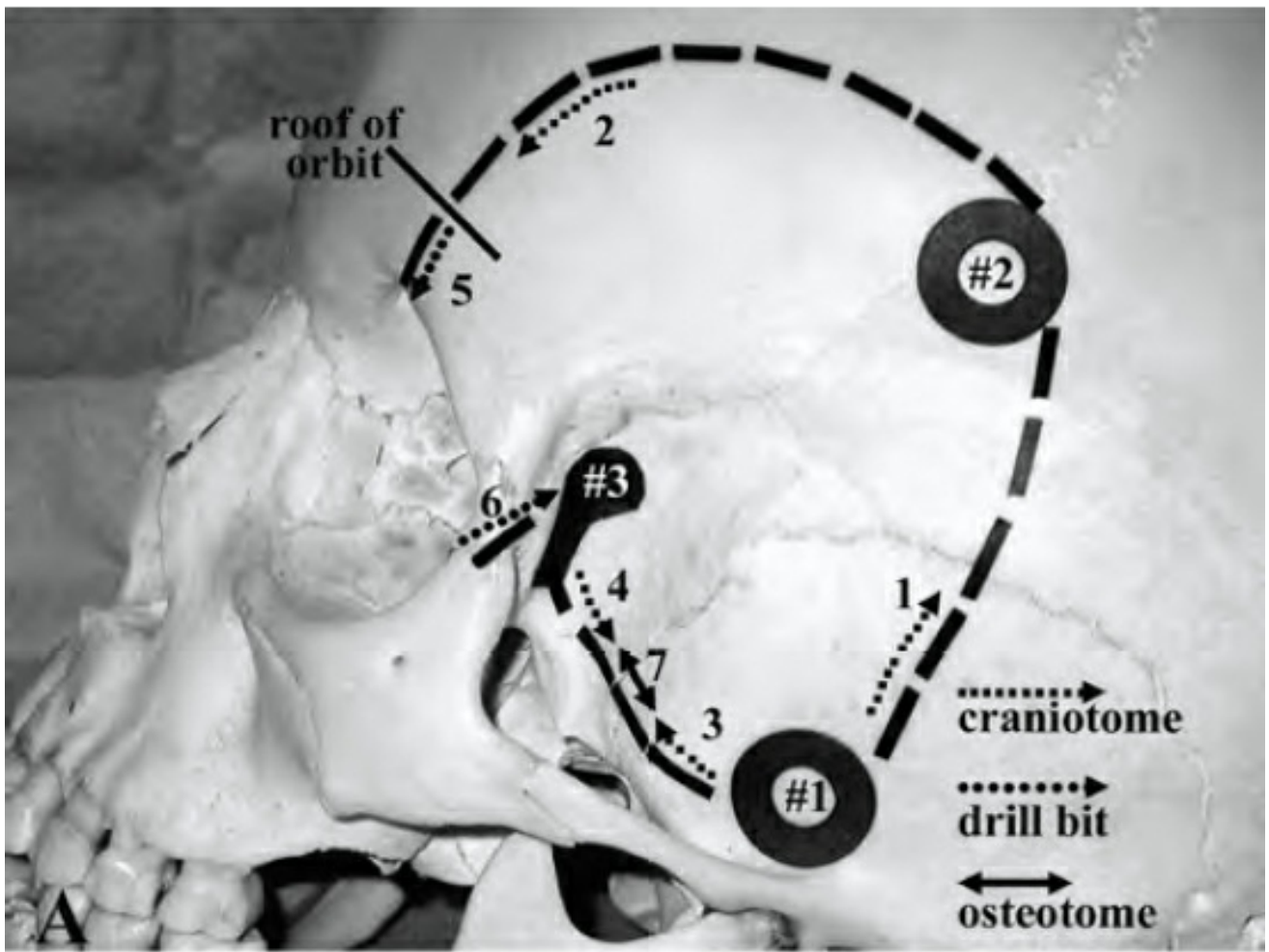


Figure 9: The steps in execution of a one-piece modified OZ are shown.

The osteotomies corresponding to the steps 3, 4, 5, 6 and 7 are performed using a B1 drill bit without a footplate. Step 8 is done using a thin osteotome (images reproduced with permission from: Balasingam, V and colleagues. Modified osteoplastic orbitozygomatic craniotomy. *J Neurosurg* 102:940-44, 2005).

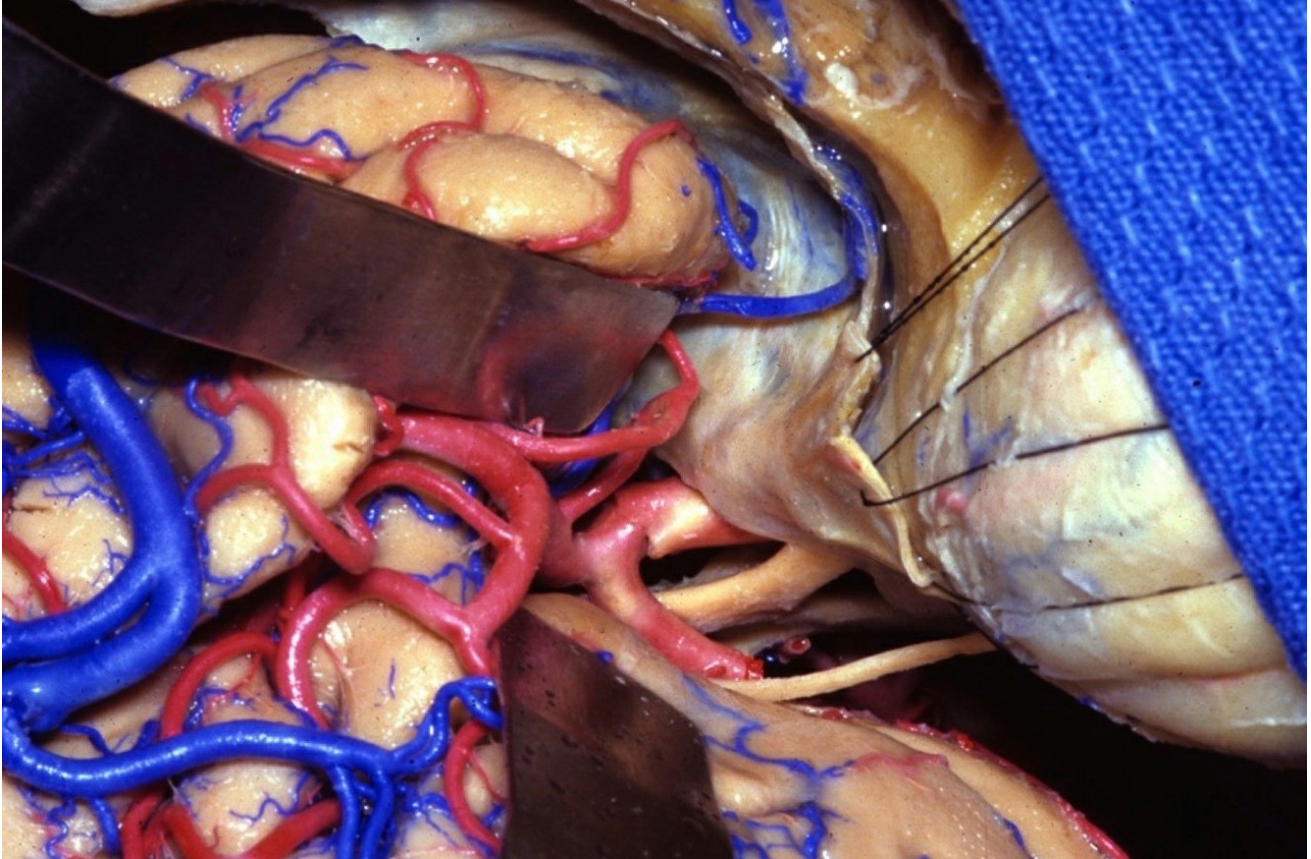


Figure 10: Intradural exposure after an orbitozygomatic craniotomy is shown. Note the expanded operative view toward the anterior and middle skull base (image courtesy of AL Rhoton, Jr).

MODIFIED ORBITOZYGOMATIC CRANIOTOMY/OSTEOTOMY

The patient is positioned supine with the head turned 20-40 degrees, depending on the specific location of the lesion. The closer the lesion to the midline, the less the head is turned. The patient's neck is slightly extended and the head is tilted toward the floor so that the malar eminence is the highest point of the field. This maneuver allows gravity retraction to mobilize the frontal lobes away from the orbital roof. Please refer to the [Pterional Craniotomy](#) chapter for more details about the operating room setup.

Other colleagues use other parameters to position the head. More basal pathologies such as ophthalmic and posterior communicating artery aneurysms as well as cavernous sinus masses require little head deflection and greater head rotation so that the orbital ridge is left in the superior plane. On the other hand, middle cerebral and carotid bifurcation artery aneurysms as well as suprasellar tumors with more superior extension benefit from a greater head deflection and minimal head rotation, allowing the malar prominence to stay in the superior plane.

The incision begins 1 cm anterior to the tragus at the level of the zygomatic arch and stays behind the hairline, curving forward across the midline to the point where the contralateral midpupillary line meets the hairline. Shorter incisions would greatly limit the reflection of the scalp flap and temporalis muscle, and will compromise the exposure of the frontal zygoma and orbital rim.

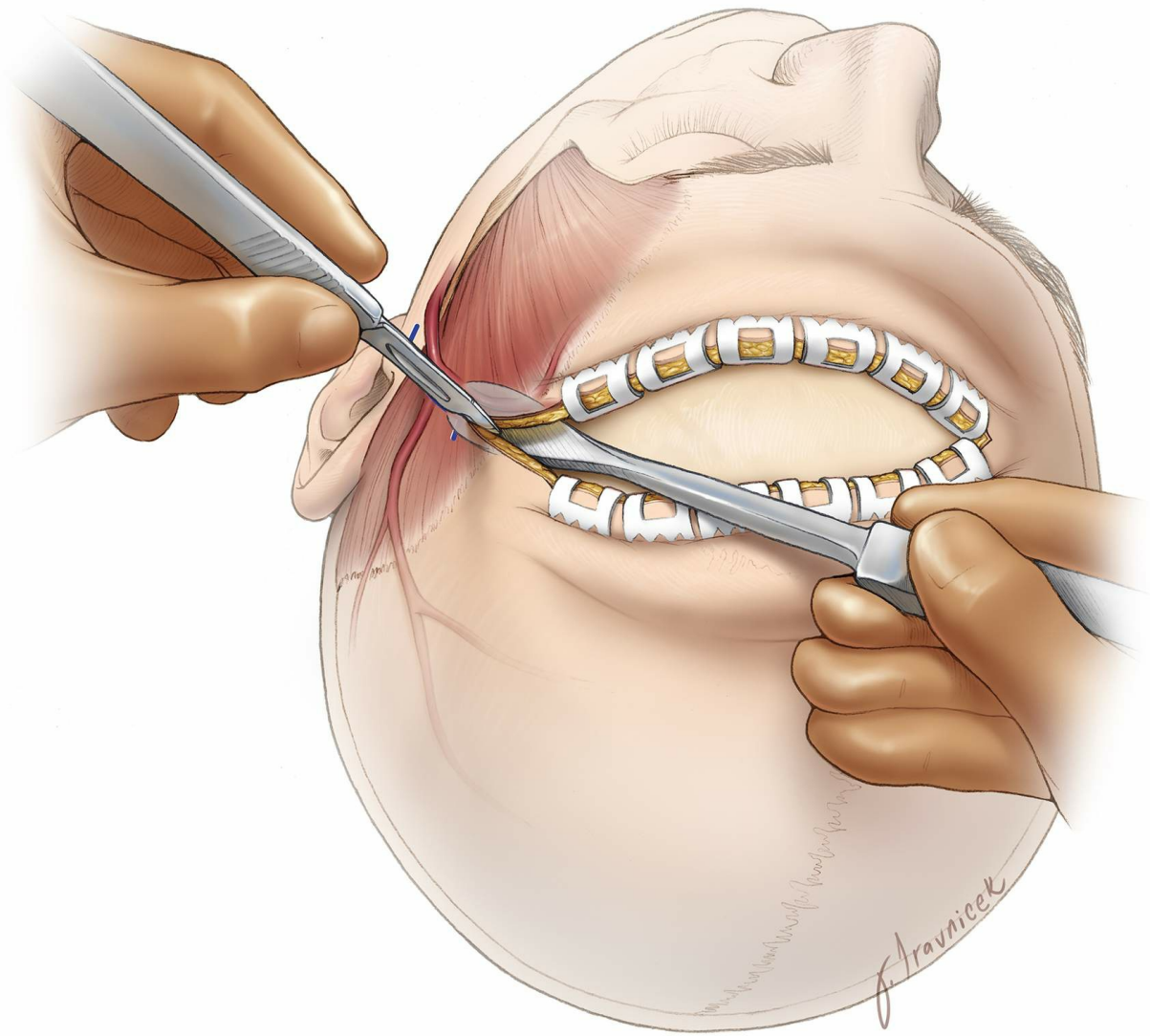


Figure 11: The incision essentially follows the hairline, stays perpendicular to the superior temporal line, without significant posterior extension. To avoid injury to the branches of the facial nerve, I do not extend the incision more than 1 cm below the zygomatic arch. If there is a potential need for a future contralateral procedure or if the patient already owns a contralateral scar, the incision may be modified to allow for its convergence into an overall bicoronal type of incision. A flat dissector separates the galea from the pericranium as the knife incises the skin.

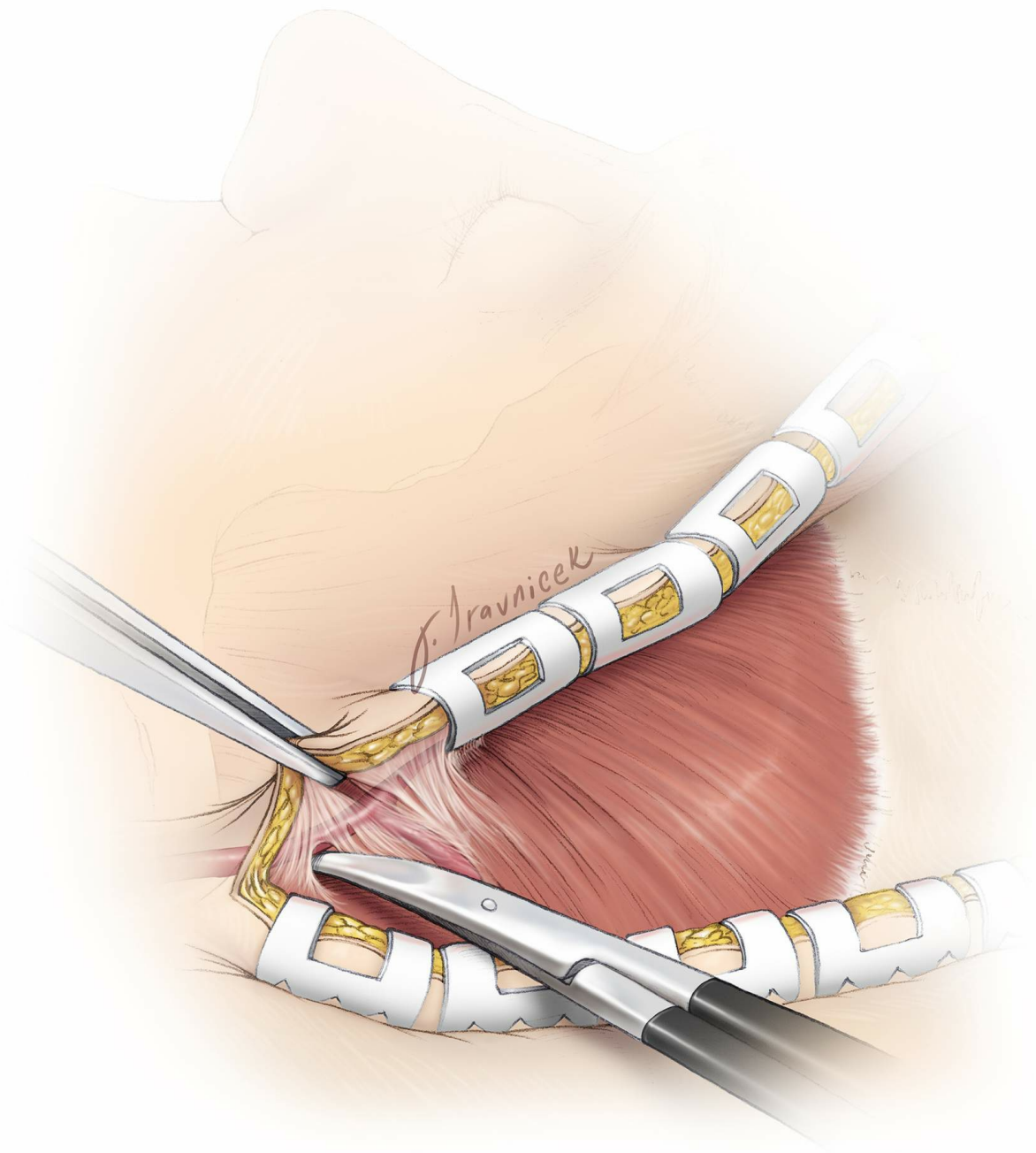


Figure 12: The skin incision is carried down sharply to the level of the pericranium and temporalis fascia. The posterior branch of the superficial temporal artery is preserved whenever possible. The frontal branch of this artery is coagulated and divided.

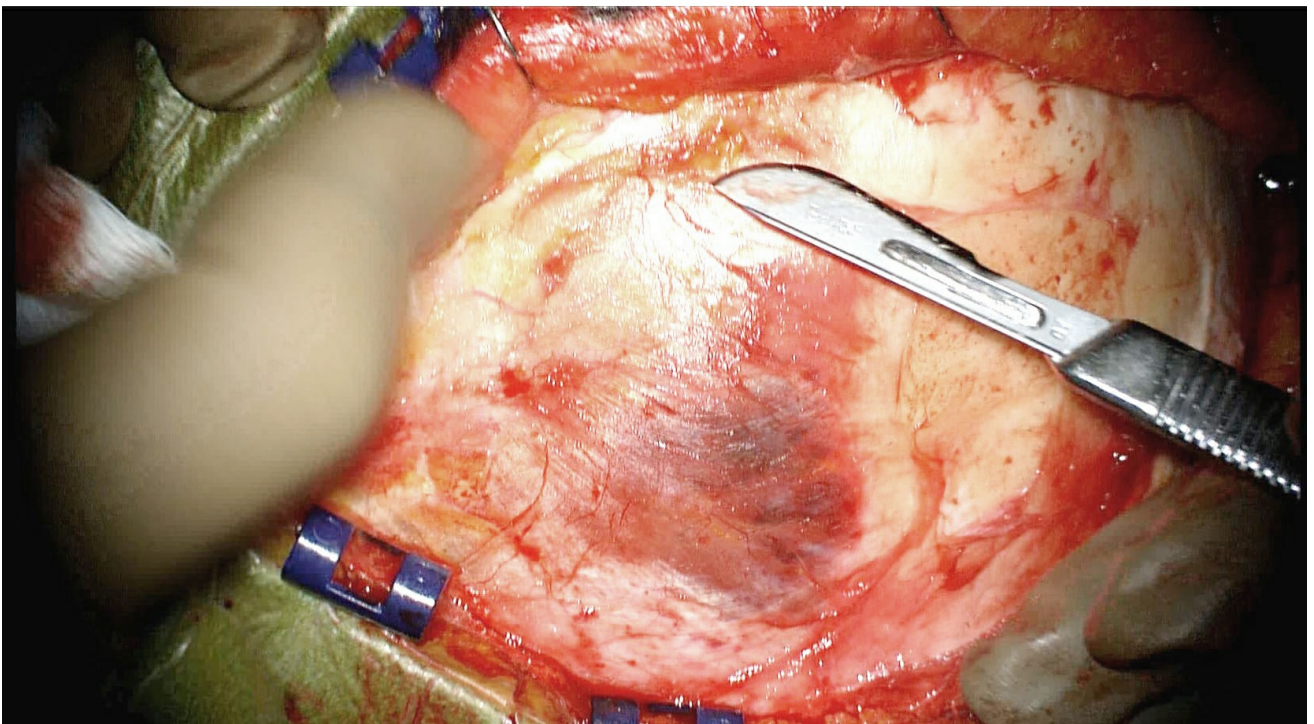
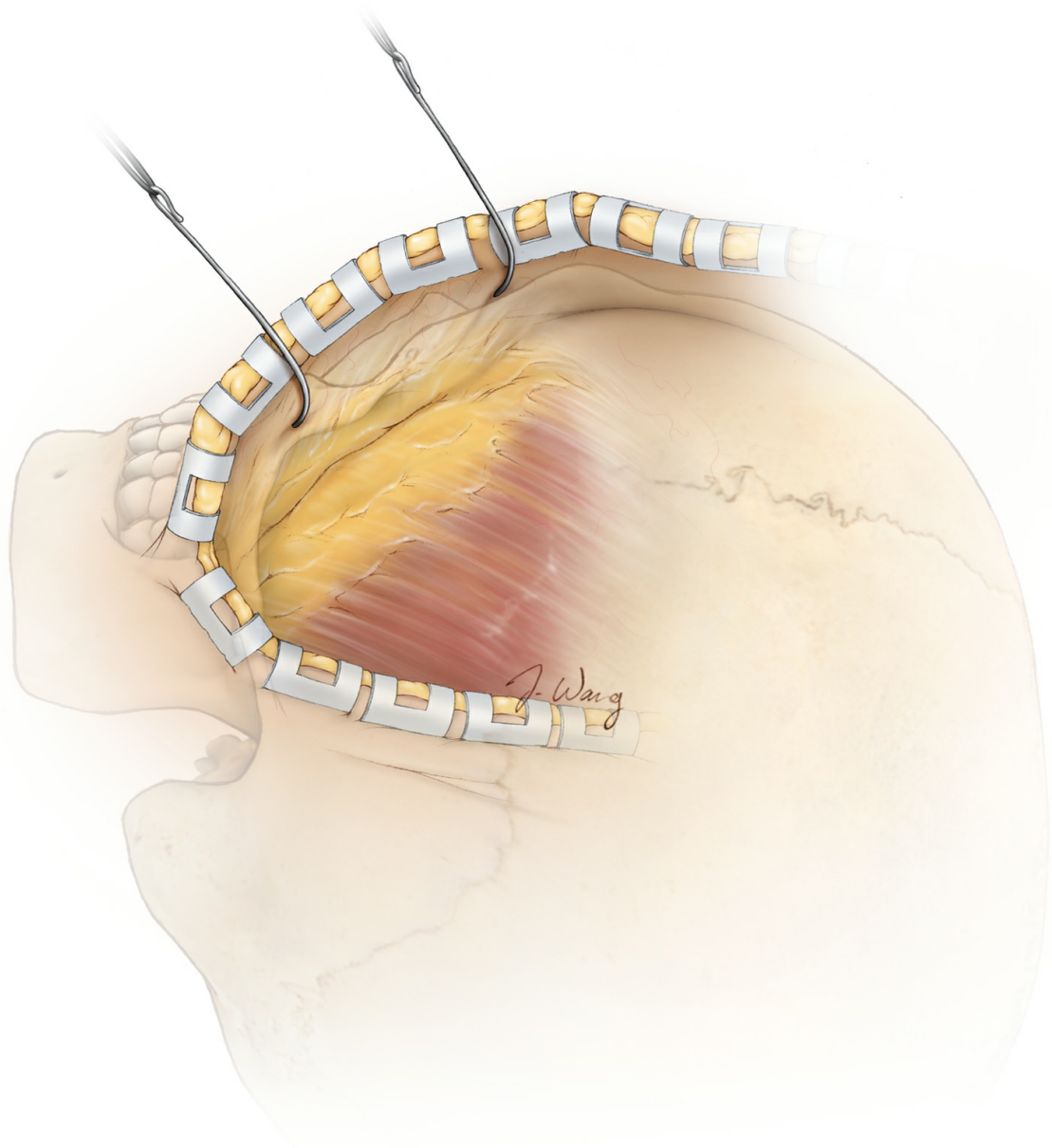


Figure 13: The plane between the galea and the pericranium is developed in case a vascularized pericranial flap is needed at the time of closure. The scalp flap is reflected anteriorly and is separated from the temporalis fascia. The belly of the #10 scalpel blade may be used to separate the pericranium from the galea. The fat pad is exposed.

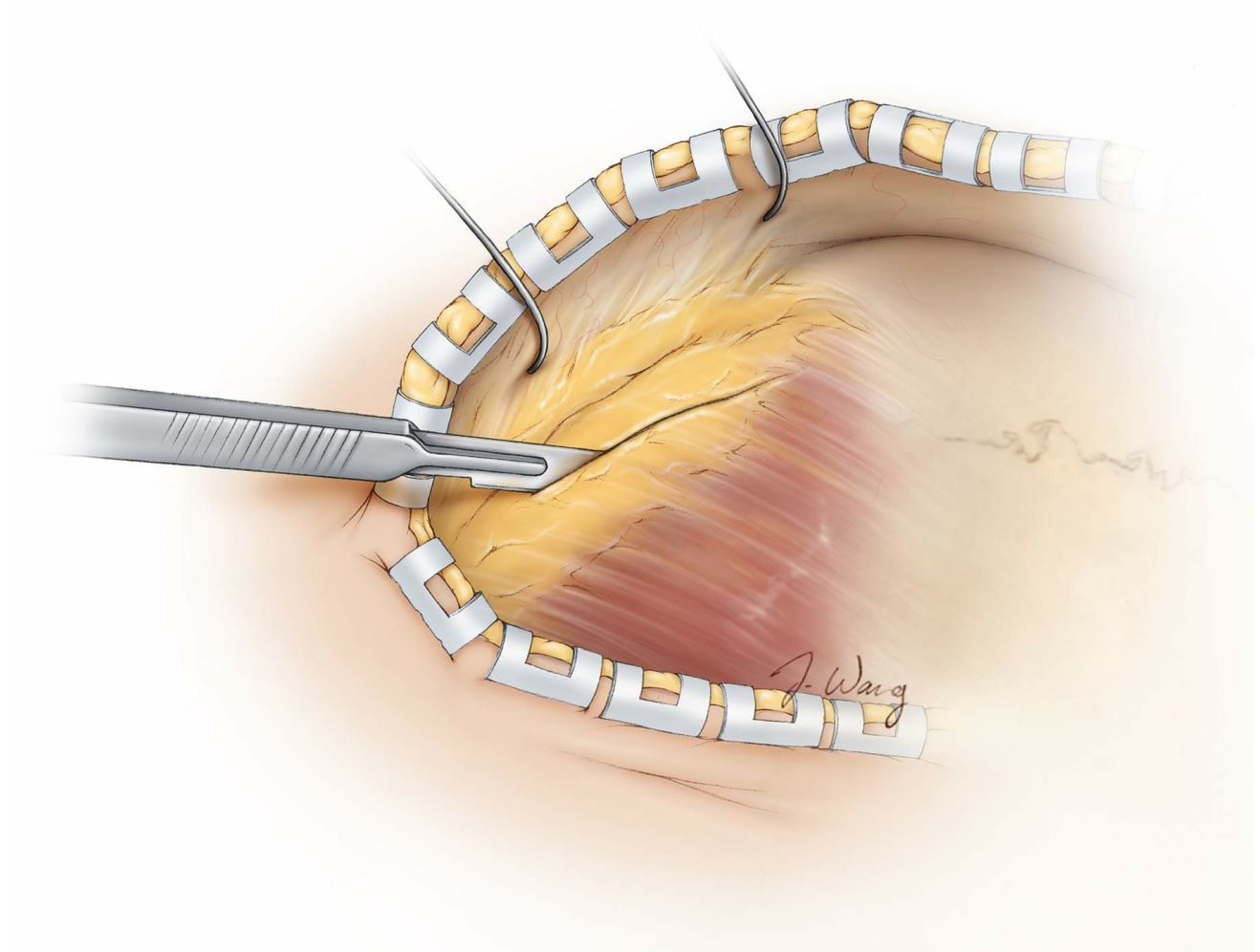


Figure 14: The plane between the galea and the pericranium is developed until the subgaleal fat pad containing the frontotemporal (frontalis) branches of the facial nerve becomes visible. These branches are located in the superficial fascia of the fat pad, not within the fat pad. There are therefore two techniques for reflecting the fat pad without injuring these branches:

1. *Interfascial technique*: The superficial temporal fascia is reflected anteriorly along with the fat pad via dissection underneath the fat pad but superficial to the deep temporal fascia.
2. *Subfascial technique*: The superficial temporal fascia is reflected anteriorly along with the fat pad and the deep temporal fascia, all as one layer **(this is my preferred method because it offers maximal**

protection for the facial nerve branches).

This fat pad is usually located 2.5 to 3 cm posterior to the frontal process of the zygoma and the orbital rim. Bovie electrocautery is used to cut the deep temporal fascia and reflect the fat pad in the subfascial manner.

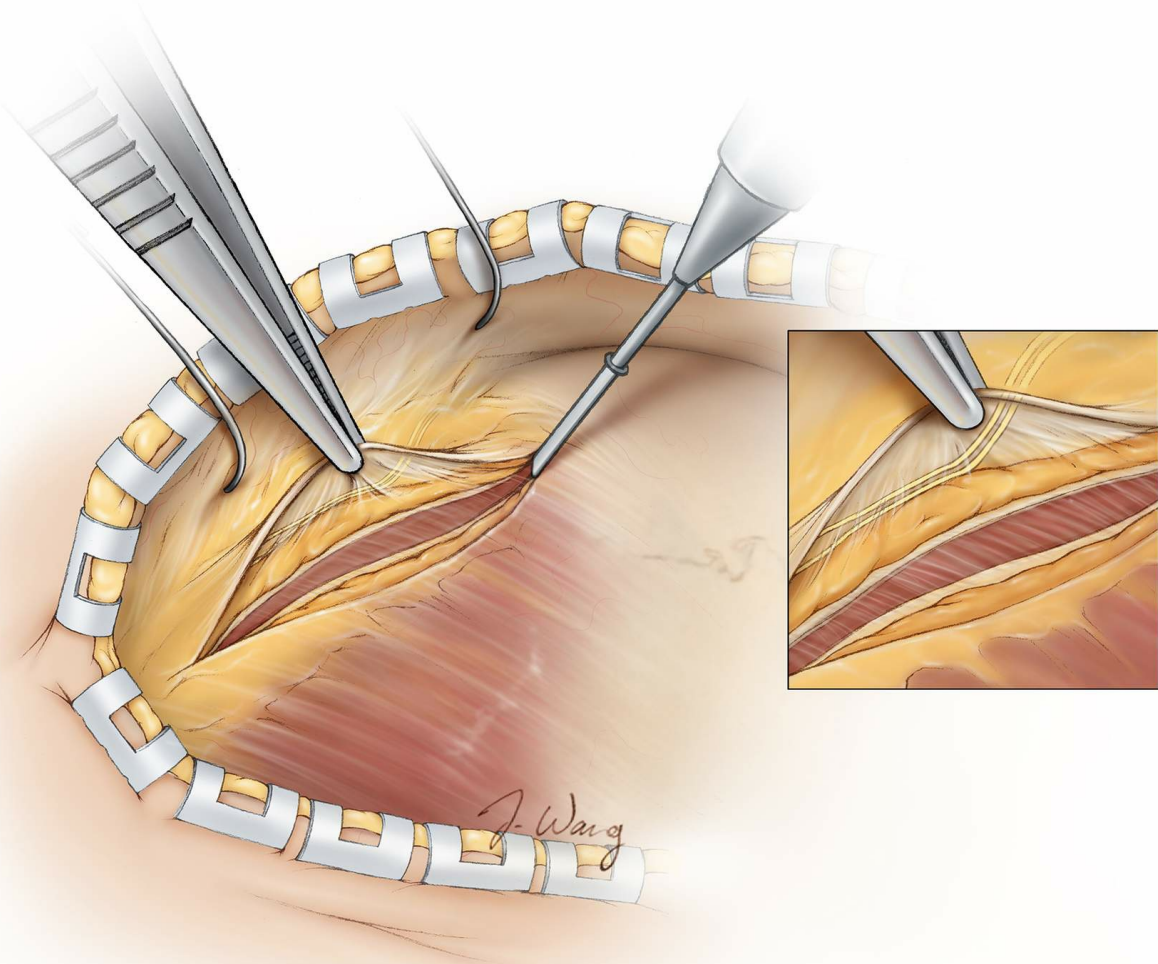


Figure 15: Subfascial technique: The two layers of the temporal fascia encasing the fat pad are incised to the level of the muscle fibers and parallel to the frontal zygomatic arch. This flap containing the fat pad and the nerve branches (inset image) is elevated and reflected anteriorly along with the scalp flap. The pericranium medial to the superior temporal line is cut perpendicular to the superior temporal line. In other words, the cut along the superior temporal line should be parallel to and in continuity with the cut used to elevate the fat pad and not perpendicular to it. This maneuver reflects the subfascial flap and the pericranial flap medial to the superficial temporal line in one layer.

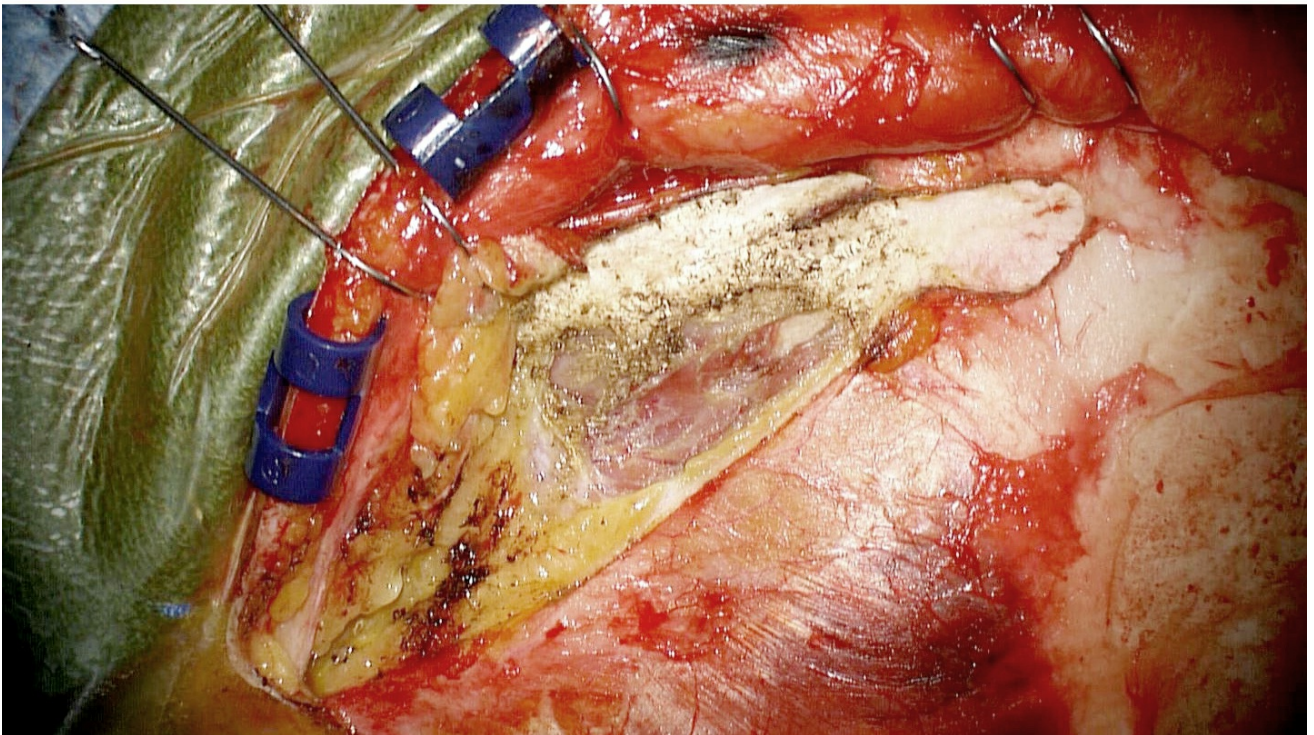
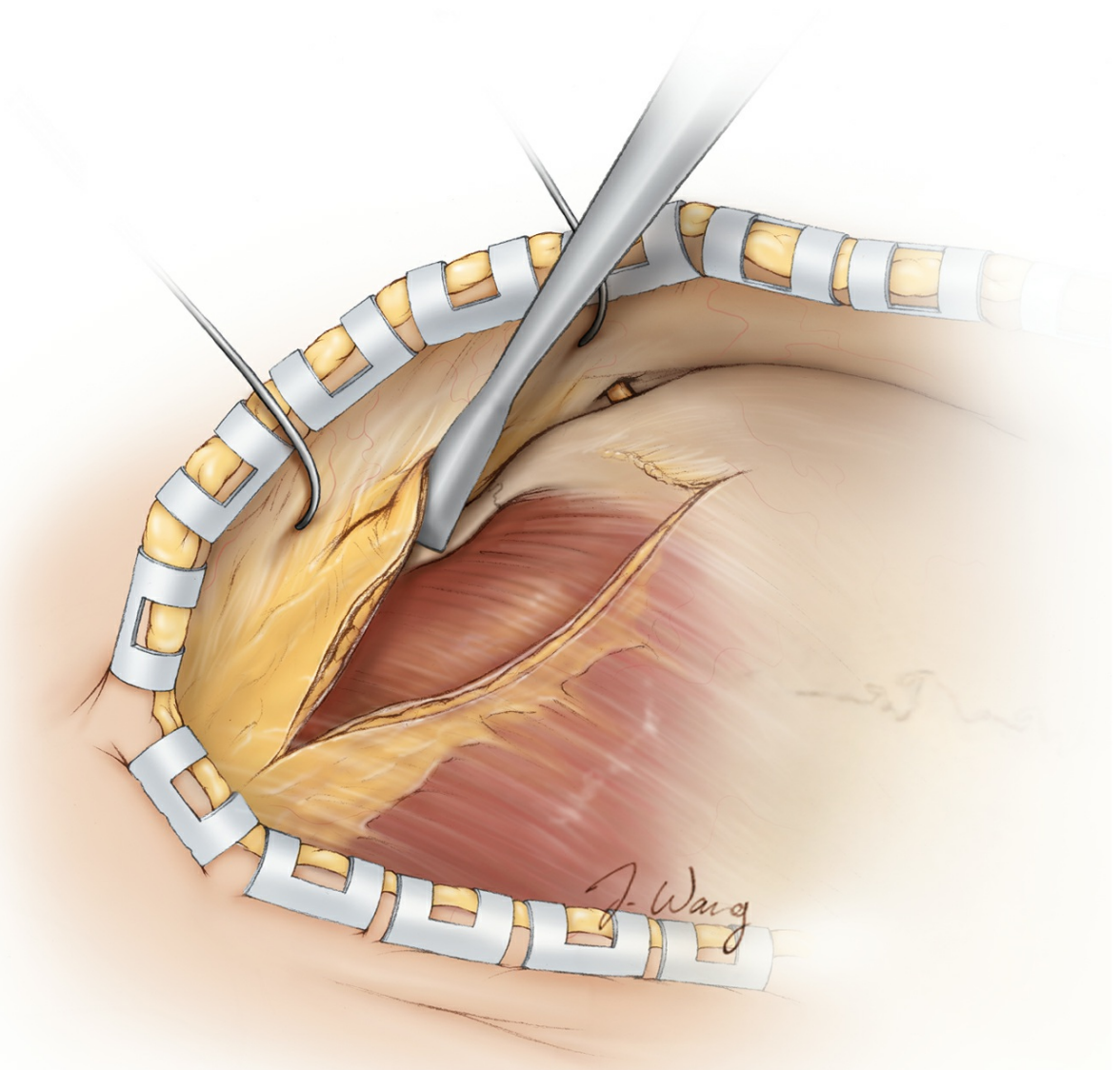


Figure 16: Subperiosteal exposure of the zygoma is shown. The deep temporalis fascia is fused along its anterior edge with the periosteum of the frontal zygomatic process. The subfascial dissection is continued anteriorly with subperiosteal dissection over the frontal zygomatic bone to achieve full exposure of the superior orbital rim and frontal zygomatic process. The pericranium over the frontal bone is also reflected anteriorly toward the orbital rim, and subperiosteal dissection is continued until the supraorbital nerve and notch are identified.

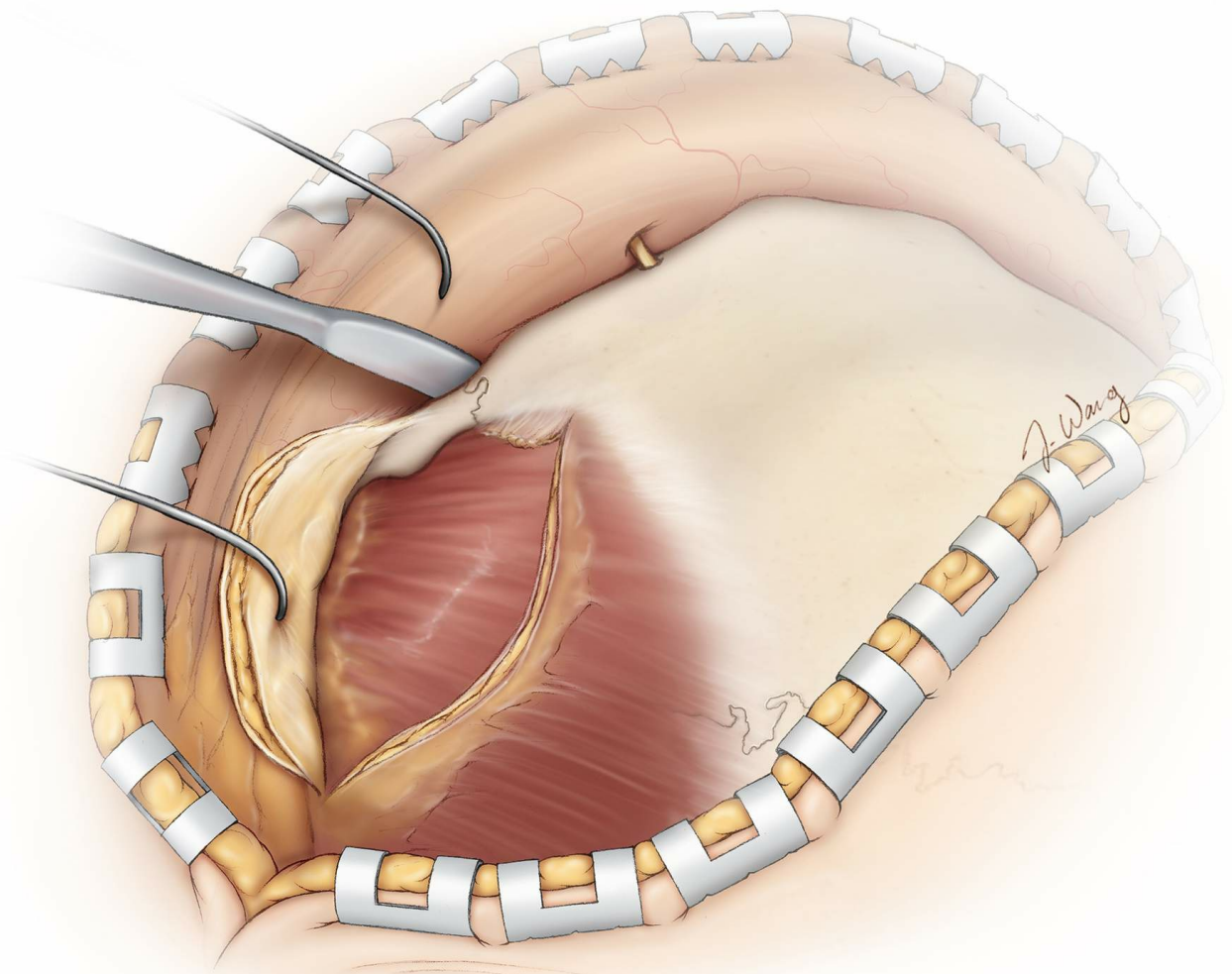


Figure 17: The superiosteal or subpericranial dissection is carried around the orbital rim and underneath the anterior roof of the orbit. Beyond the rim, the periosteum of the zygomatic and frontal bones blends into the periorbita. Blunt dissection is used to free the periorbita from the orbital rim lateral to the supraorbital notch. The periorbita is often adherent at the frontozygomatic suture. This attachment is dissected first, and then a blunt dissector is used to sweep over the periorbita from the inferior

orbital fissure toward the supraorbital notch until the subperiosteal plane is well defined.

Usually, 2 to 3 cm of dissection into the orbit is sufficient. If the periorbital is disrupted, intraorbital fat that herniates through the defect may be shrunk using bipolar electrocautery. Disruption of the periorbital leads to a more pronounced postoperative periorbital edema and bruising.

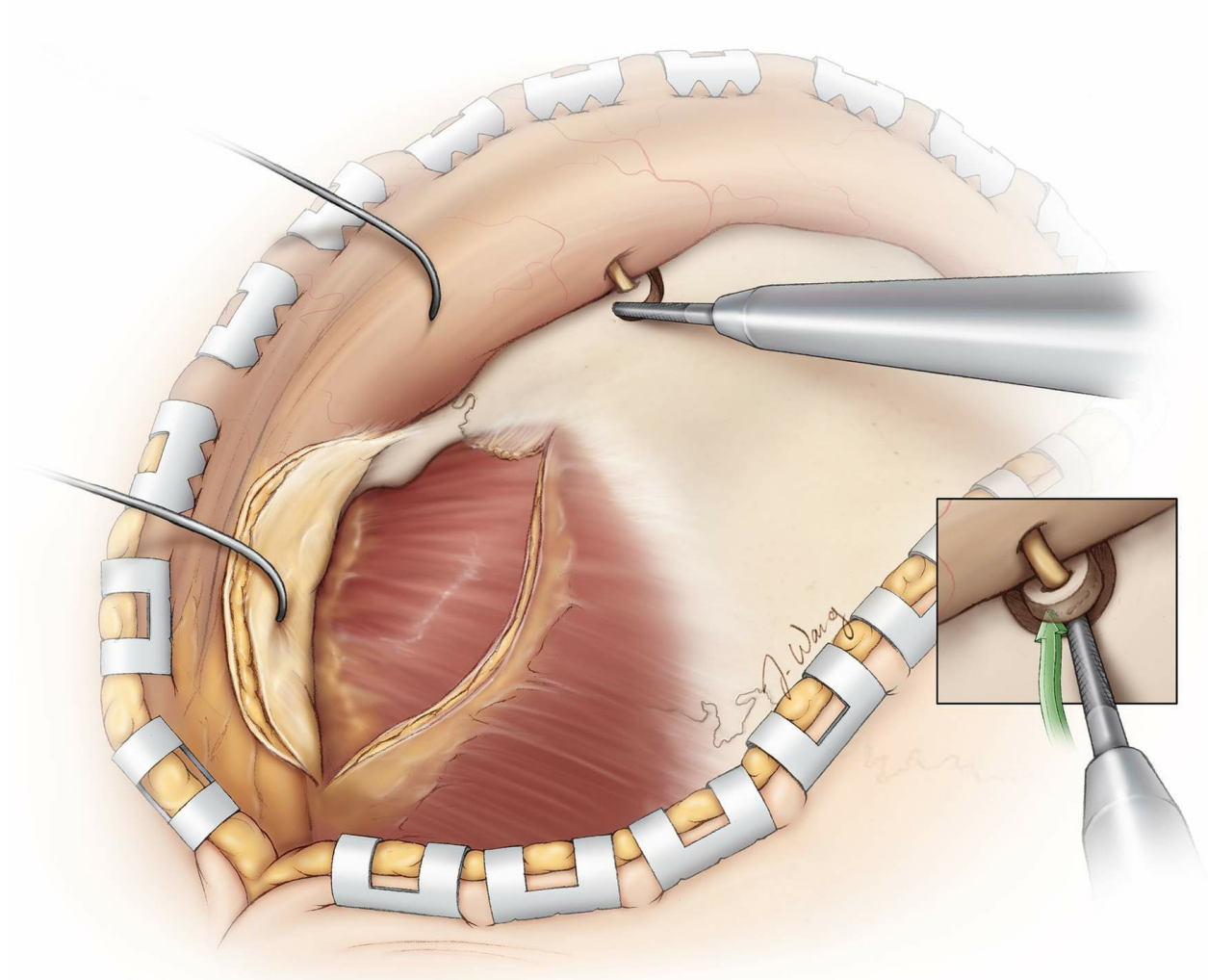


Figure 18: The supraorbital nerve is often embedded within its notch but may be mobilized out of its groove using gentle blunt dissection. However, the nerve rarely owns its own foramen. If such a foramen is present, a small caliber, straight, side-cutting drill bit is used to cut a halo of the orbital rim around the supraorbital nerve to allow for anterior mobilization of the nerve with its foramen without injury to the nerve (inset image).

Once the nerve is released, it can be easily reflected inferiorly along with the pericranial flap and periorbital. The small osteotomy around the nerve

may also be used as the exit point for the footplate of the craniotome at the time of the craniotomy.

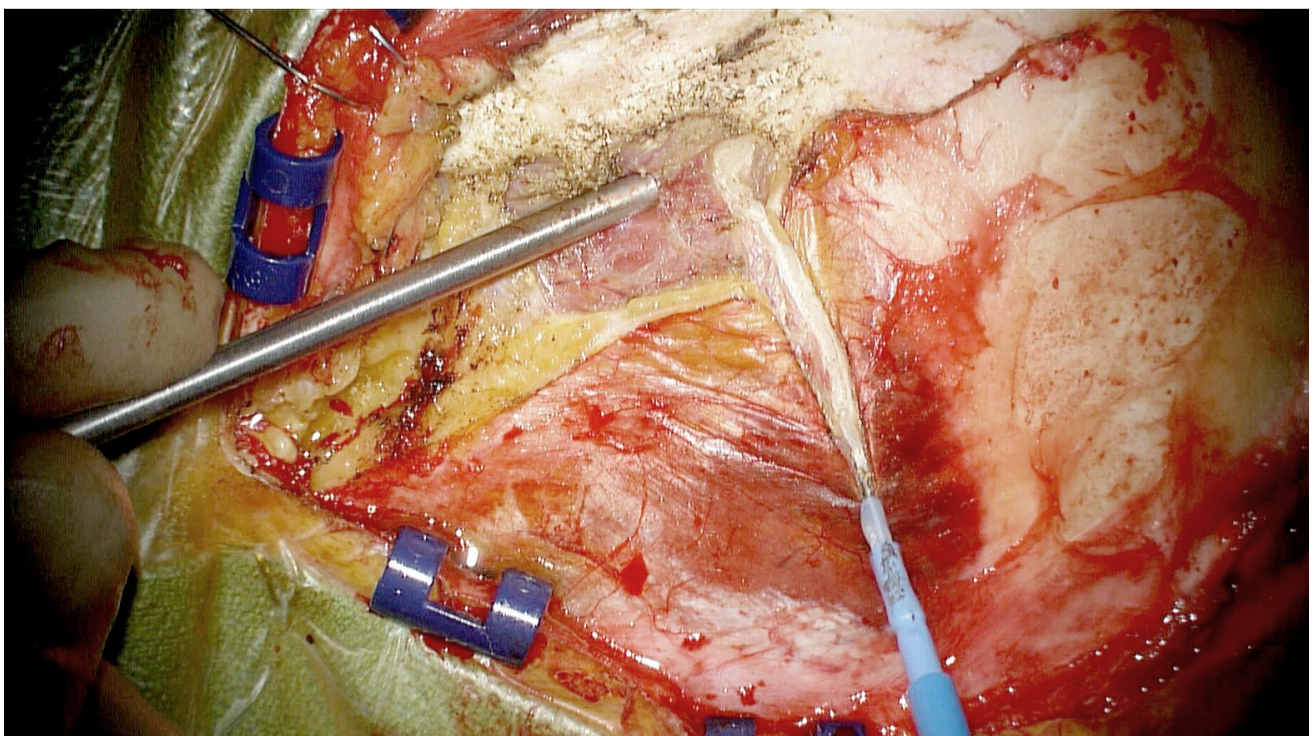
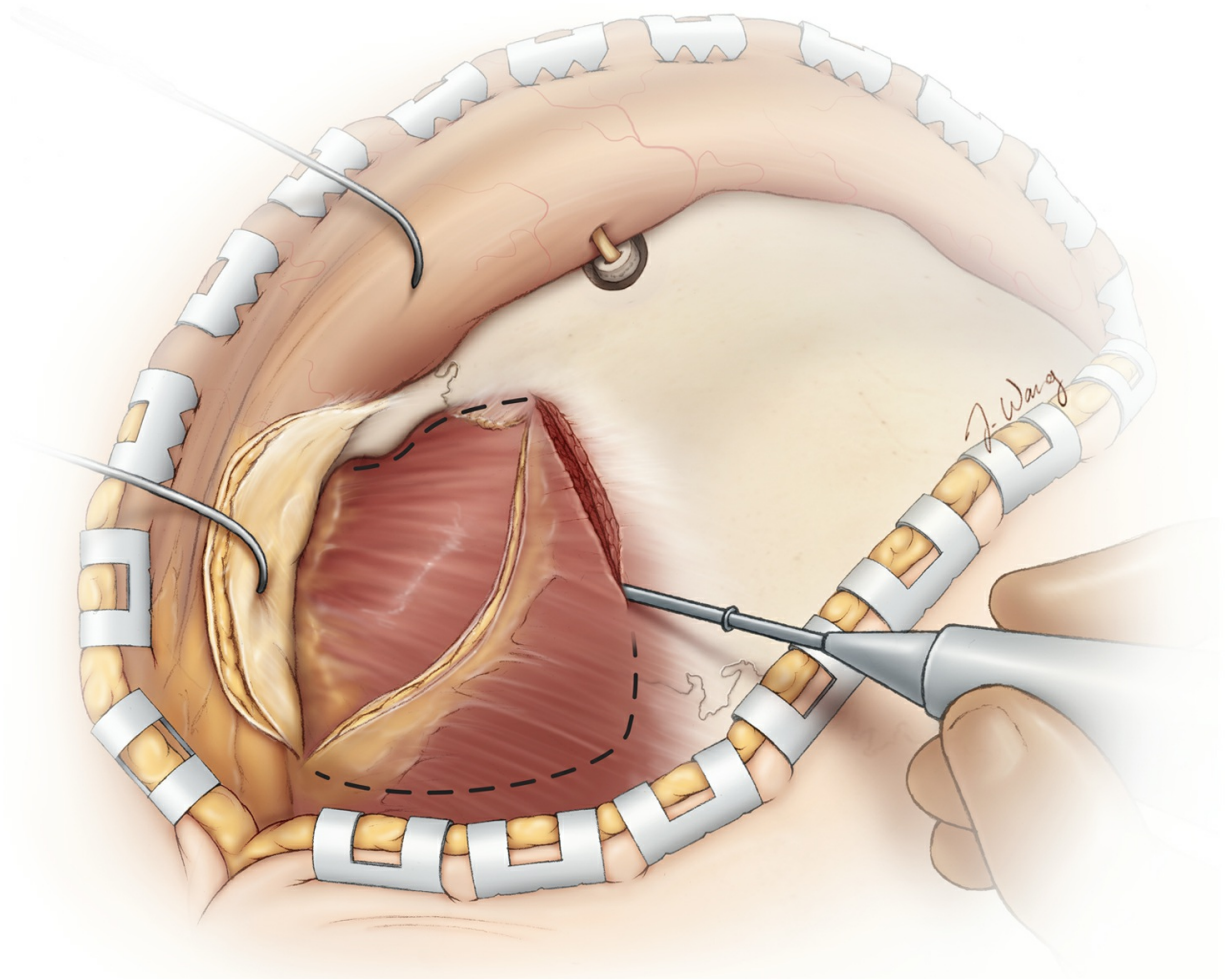


Figure 19: Next, the temporalis muscle is incised along its insertion at the superior temporal line and posteriorly parallel to the scalp incision line. A myofascial cuff is left in place at the superior temporal line to allow repair of the muscle upon closure. The muscle is then elevated in a subperiosteal manner using a periosteal elevator, starting at the zygomatic arch and working toward the superior temporal line.

This retrograde muscle dissection may permit a better preservation of the subperiosteal layer containing the deep temporal arteries and nerves nourishing the muscle, potentially minimizing its postoperative atrophy. The muscle is then retracted inferiorly, and not anteriorly, to maximize its mobilization away from the subfrontal working zone.

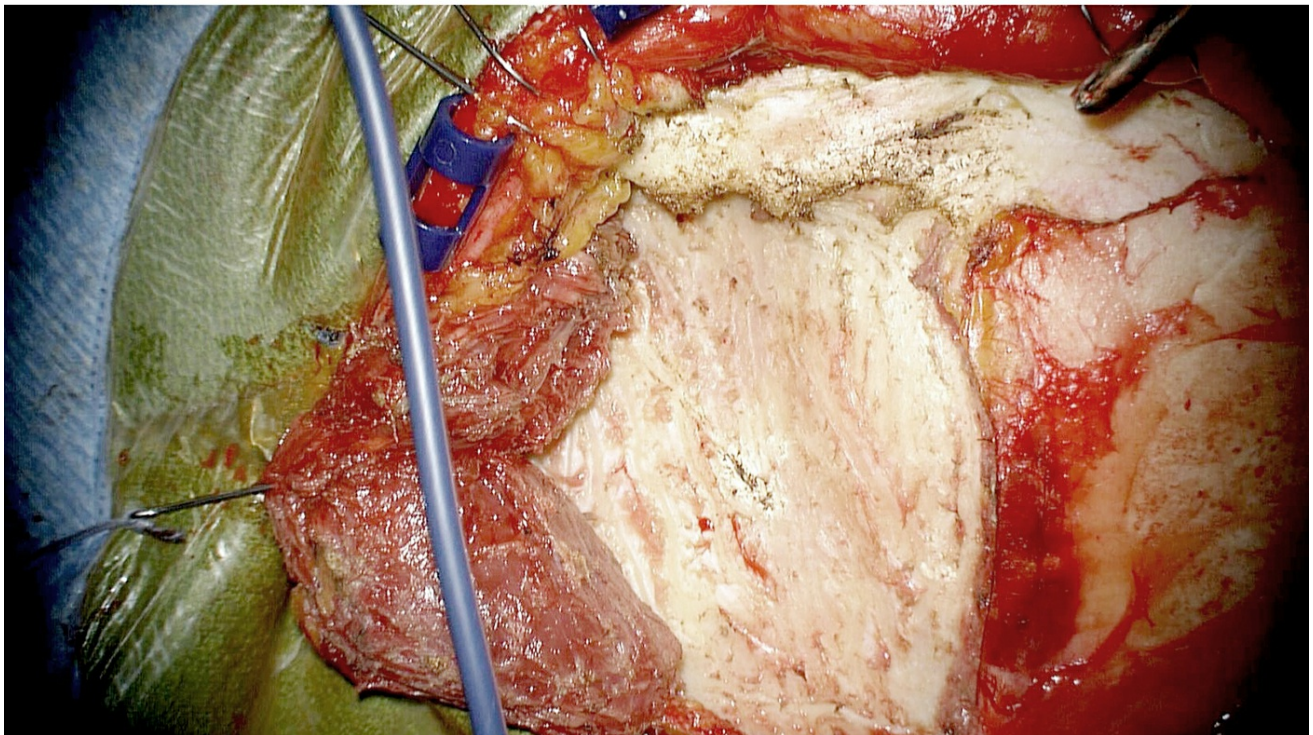
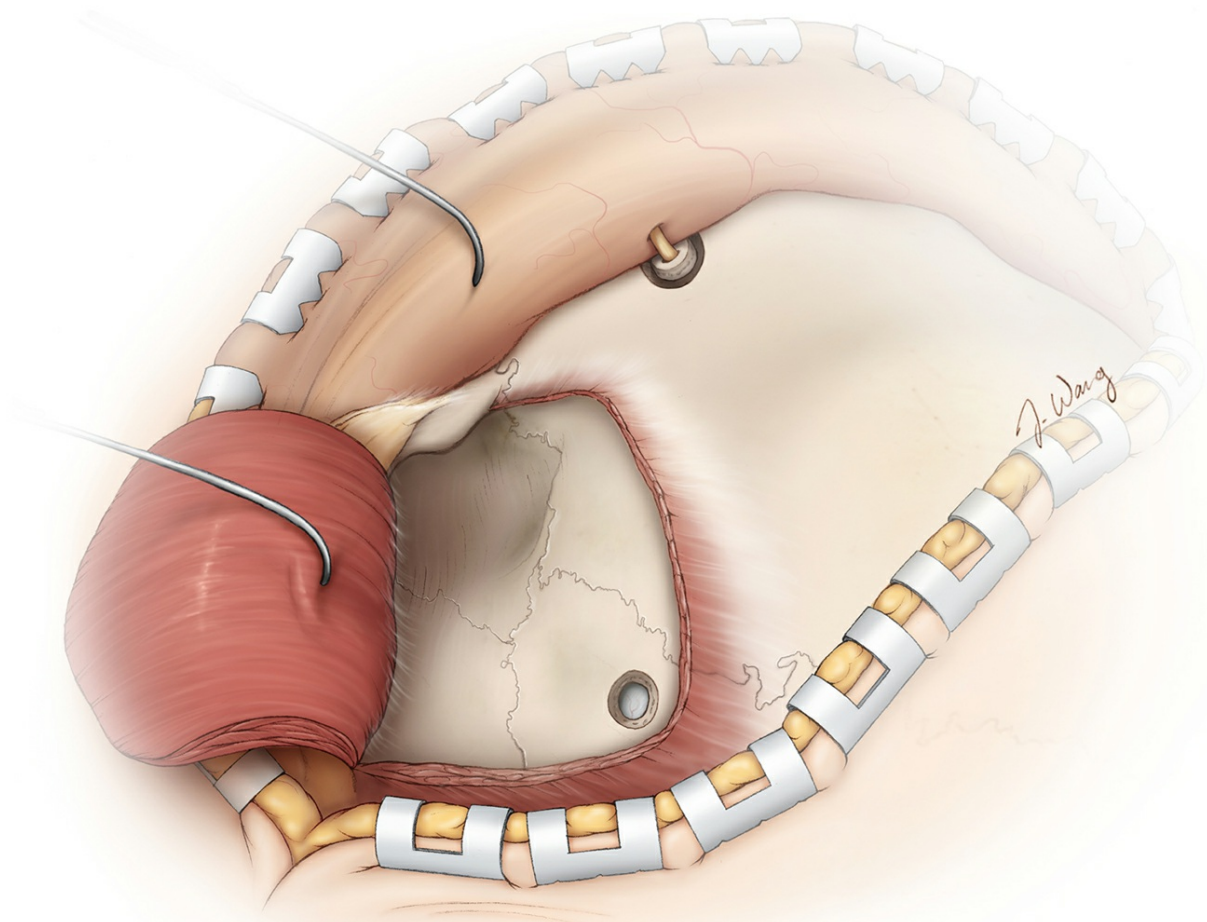
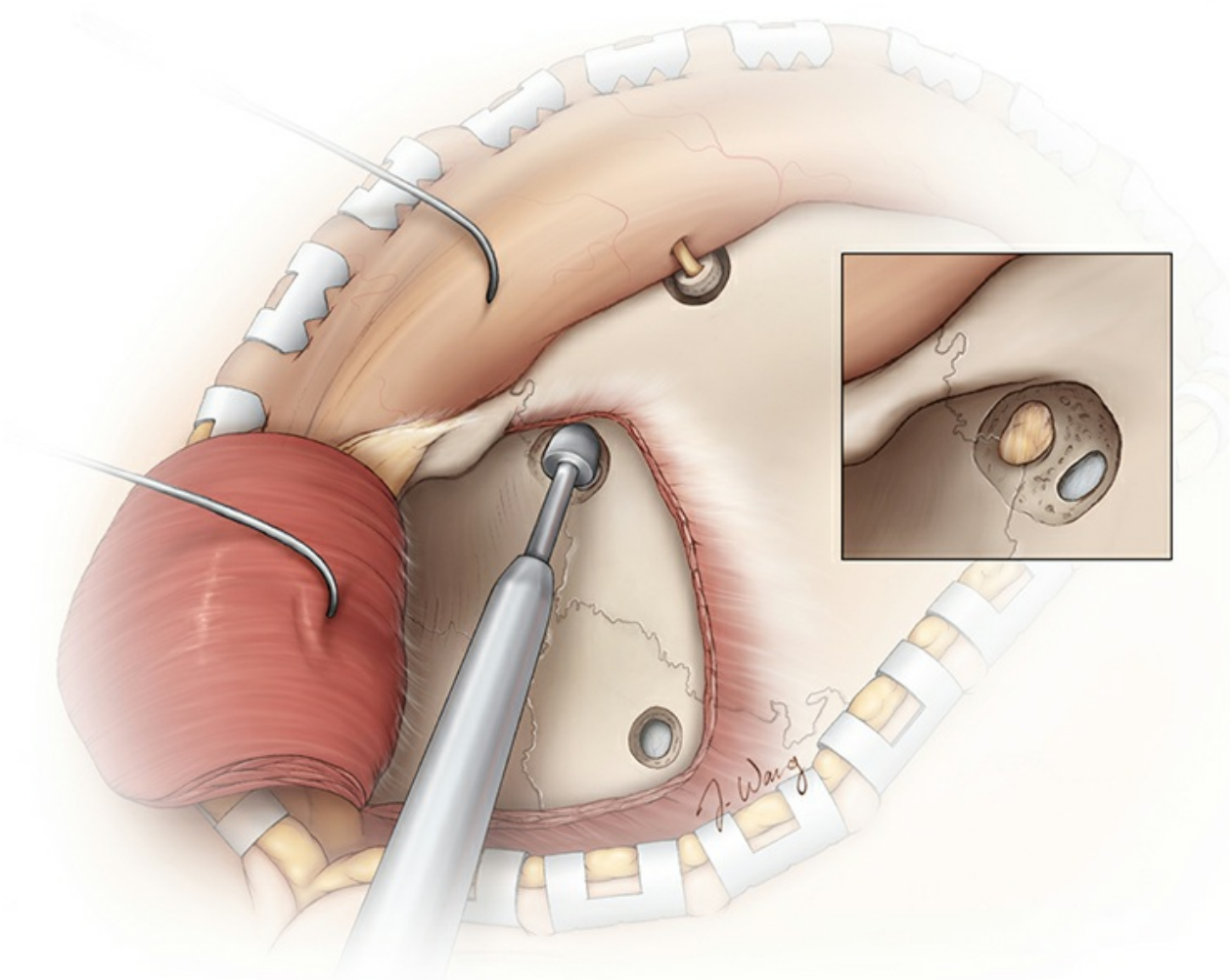
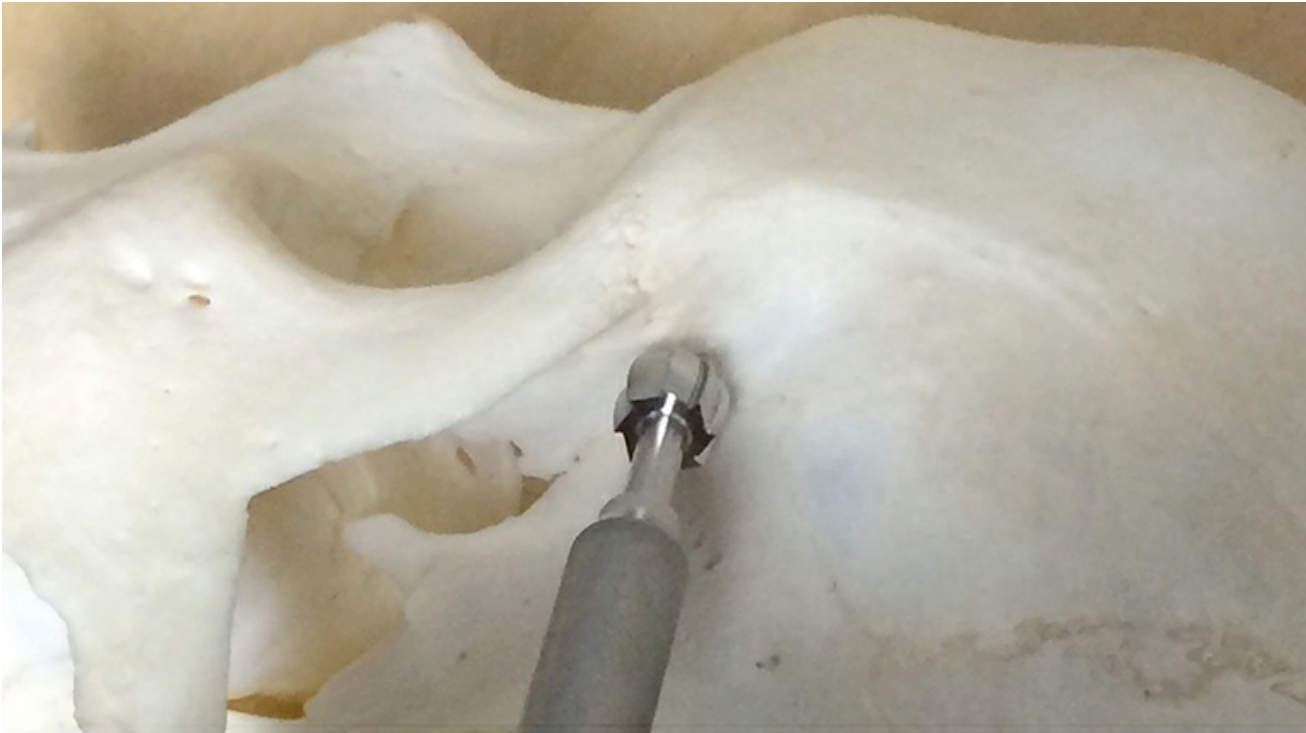

Figure 20: Two burr holes are needed to create an orbitozygomatic bone flap. Additional burr holes can be added, if necessary, to preserve the integrity of the dura. The first burr hole is placed immediately caudal to

the superior temporal line close to the posterior margin of the bony exposure. Note the use of fishhooks to maximally mobilize the soft tissues; the temporalis muscle is mobilized inferiorly rather than anteriorly.



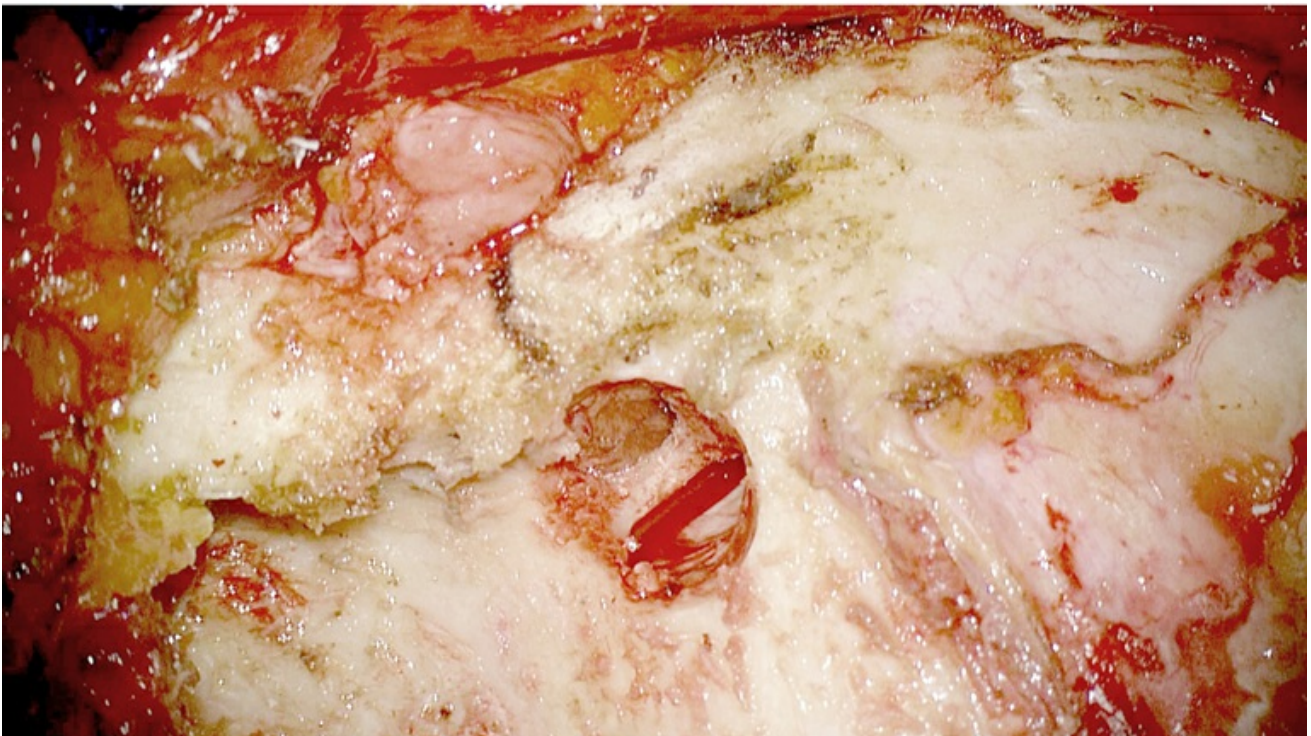
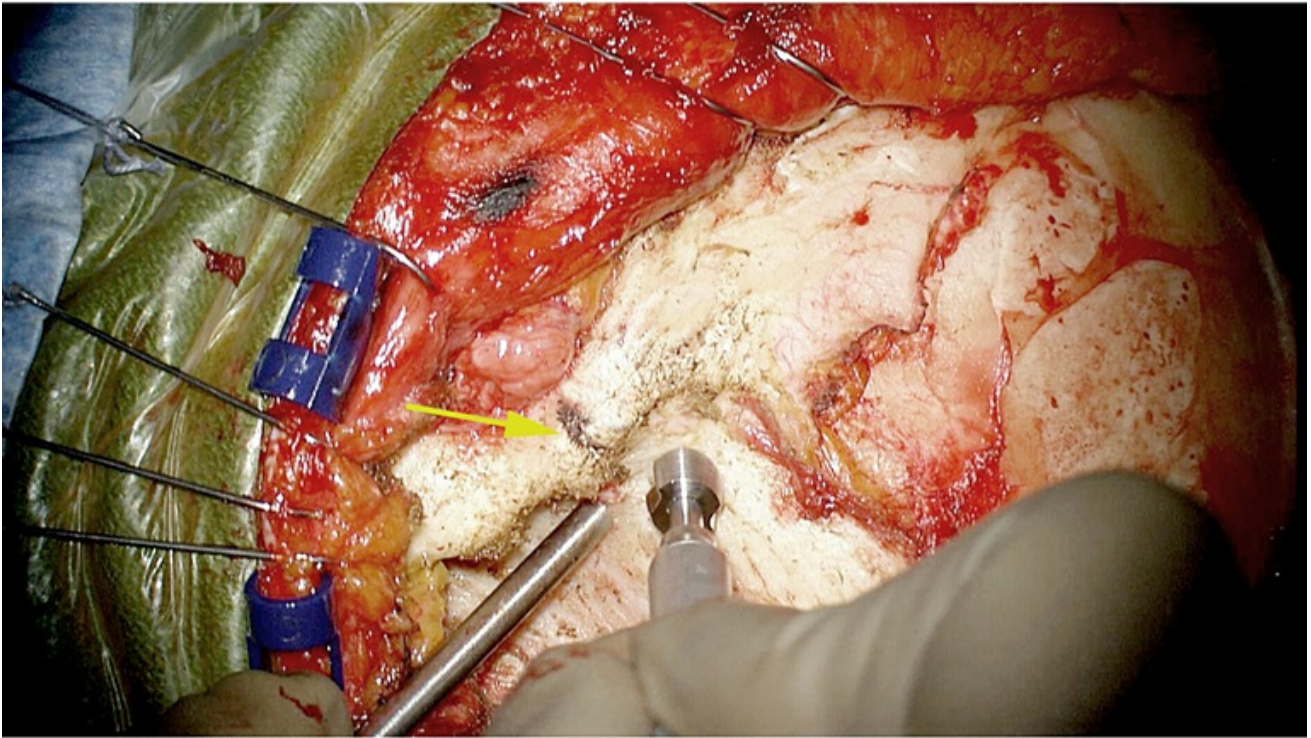


Figure 21: It is imperative to place the keyhole at the appropriate location and drill at the correct angle to expose both the periorbital and the frontal dura through the expanded burr hole. Accurate completion of the keyhole facilitates execution of the one-piece orbitozygomatic craniotomy and prevents excessive bone loss in the keyhole region and resultant cosmetic deformity.

The keyhole is made in the temporal fossa, about 7-mm superior and 5-mm posterior to the frontozygomatic suture (yellow arrow). The shaft of

the drill is held at a 45 degree angle measured from the plane of the temporal bone. The supraposterior half of this burr hole exposes the dura of the anterior fossa, while the anteroinferior part exposes the periorbita (inset). The roof of the orbit divides these two compartments within the keyhole.

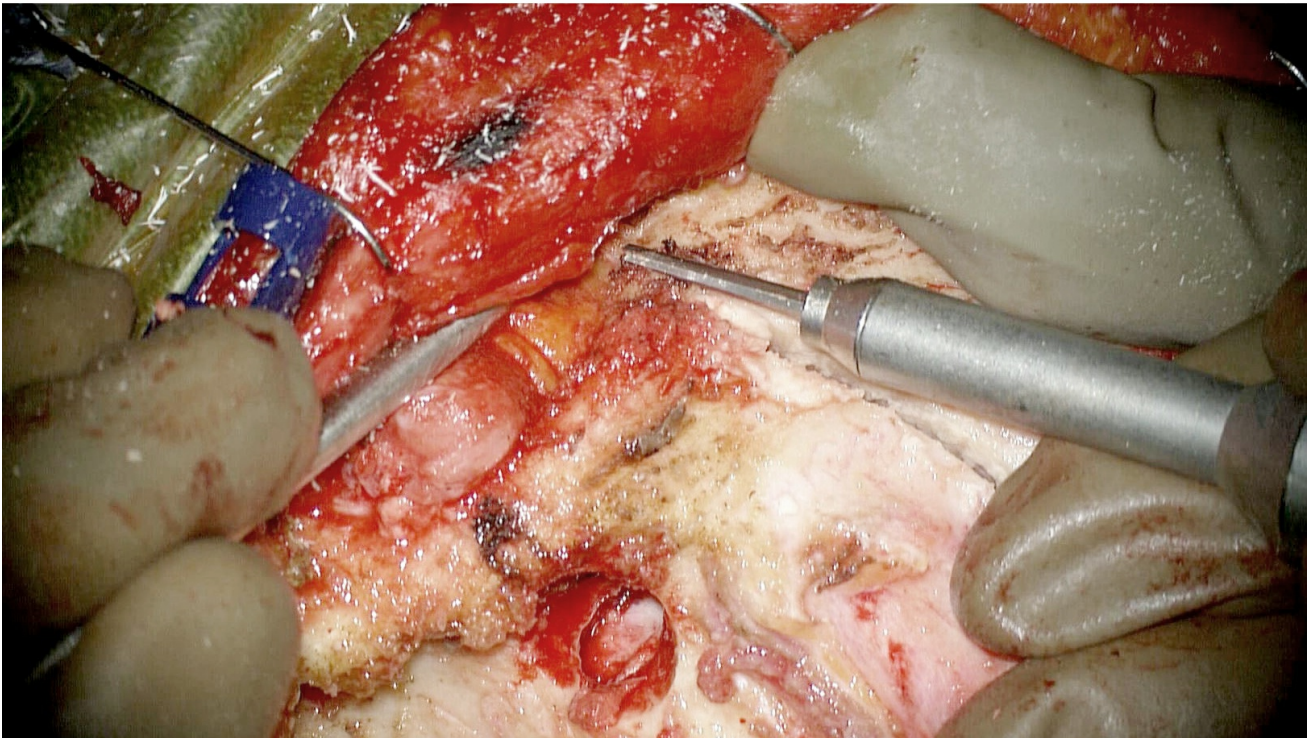
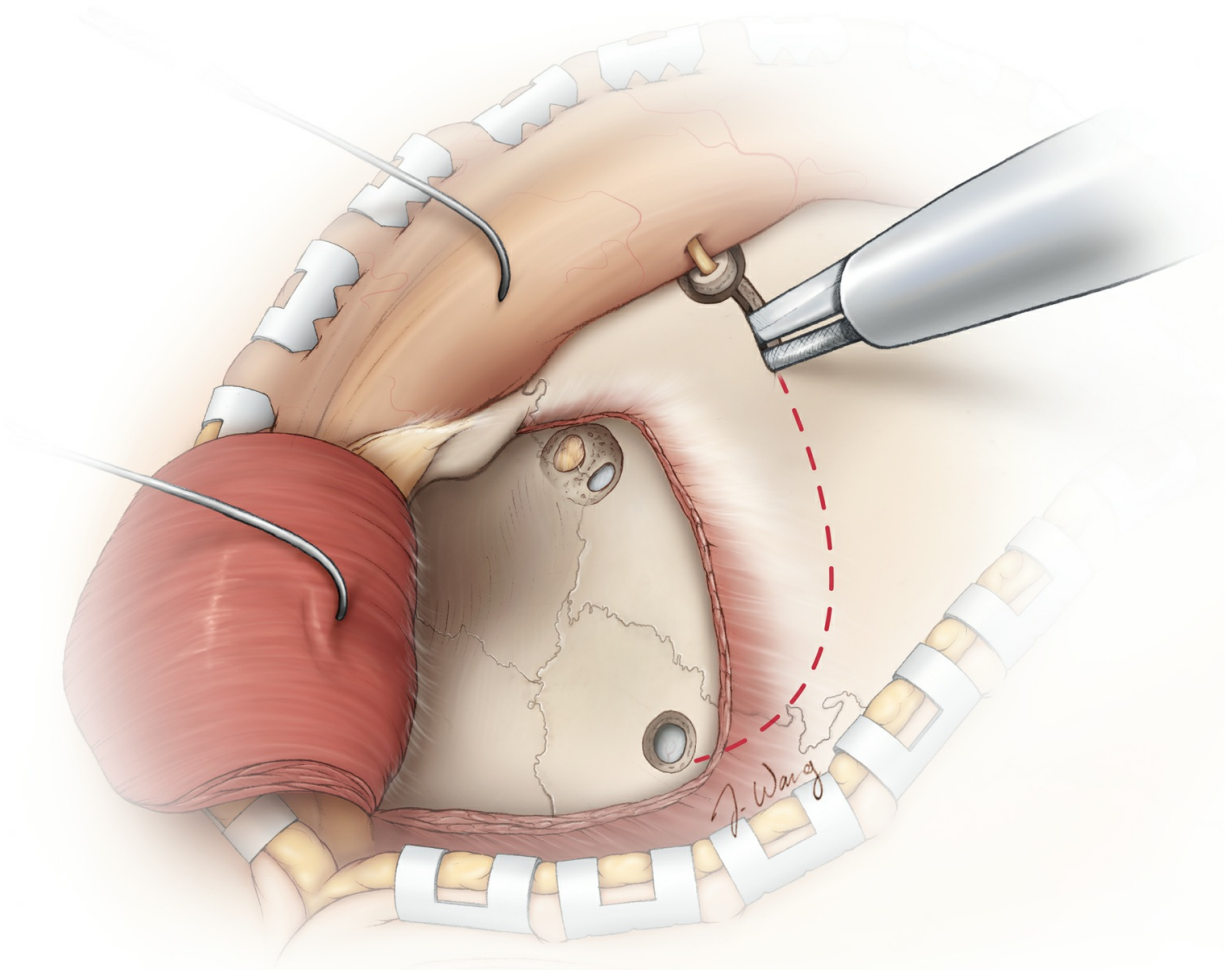


Figure 22: The craniotome with the footplate attachment is now used for the craniotomy. The first bony cut starts within the supraorbital notch,

where the small osteotomy was previously performed to release the nerve (top). Alternatively and more commonly, the temporal burr hole may be used as the starting point. This cut stays superior to and follows the contour of the superior temporal line. If the supraorbital notch does not require drilling to release the nerve, the orbital rim osteotomy is conducted lateral to the notch using a side-cutting drill bit (bottom).

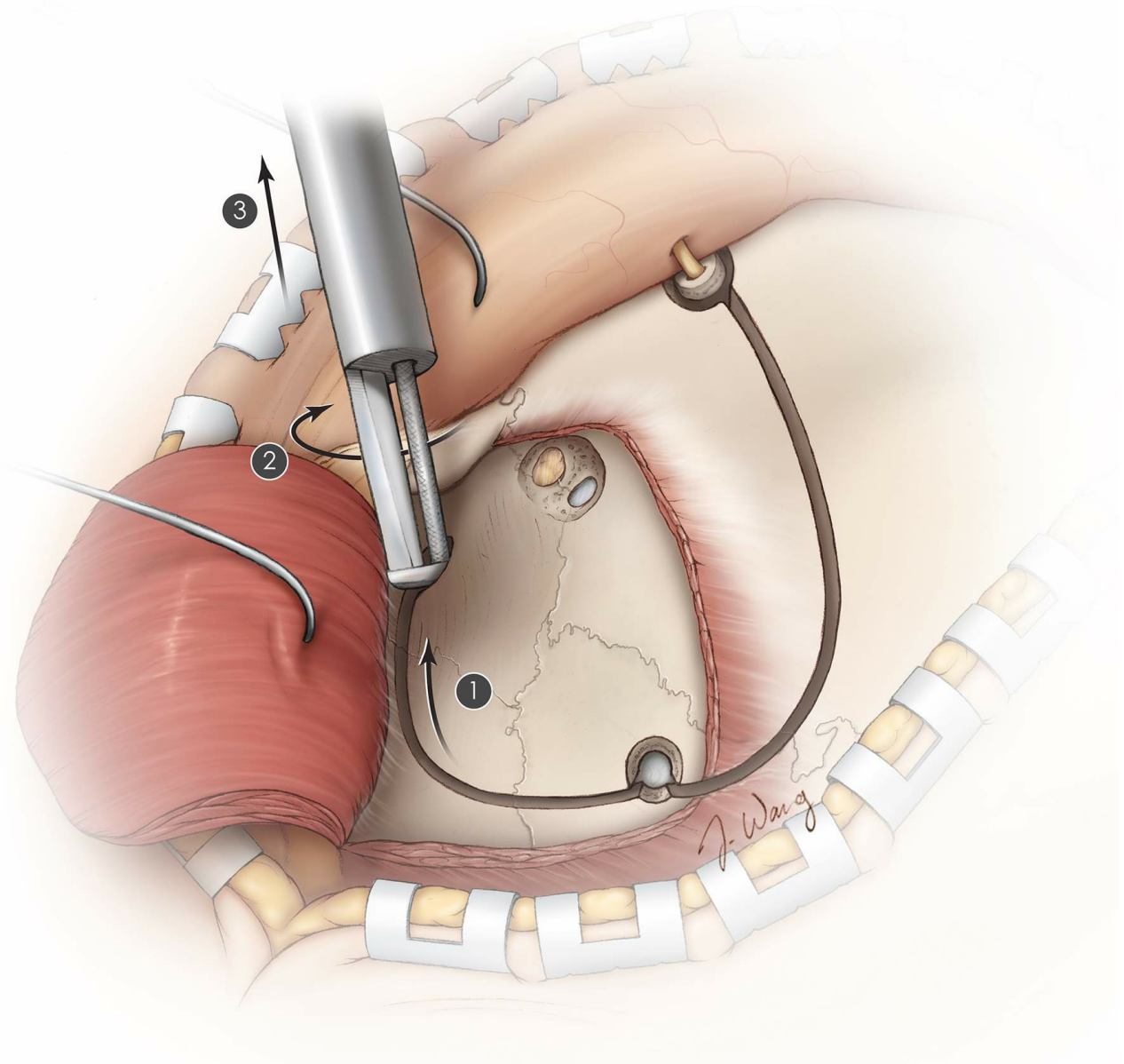


Figure 23: The footplate attachment is also used to create the inferior portion of the craniotomy. Starting at the temporal burr hole, the craniotome is directed inferiorly and then anteriorly until the progress of the footplate is stopped by the sphenoid wing. At this point, the drill is “turned around on itself” (steps 1 and 2) to expand the last few millimeters of the bony cut, creating enough space so that the footplate can be removed from the epidural space (step 3).

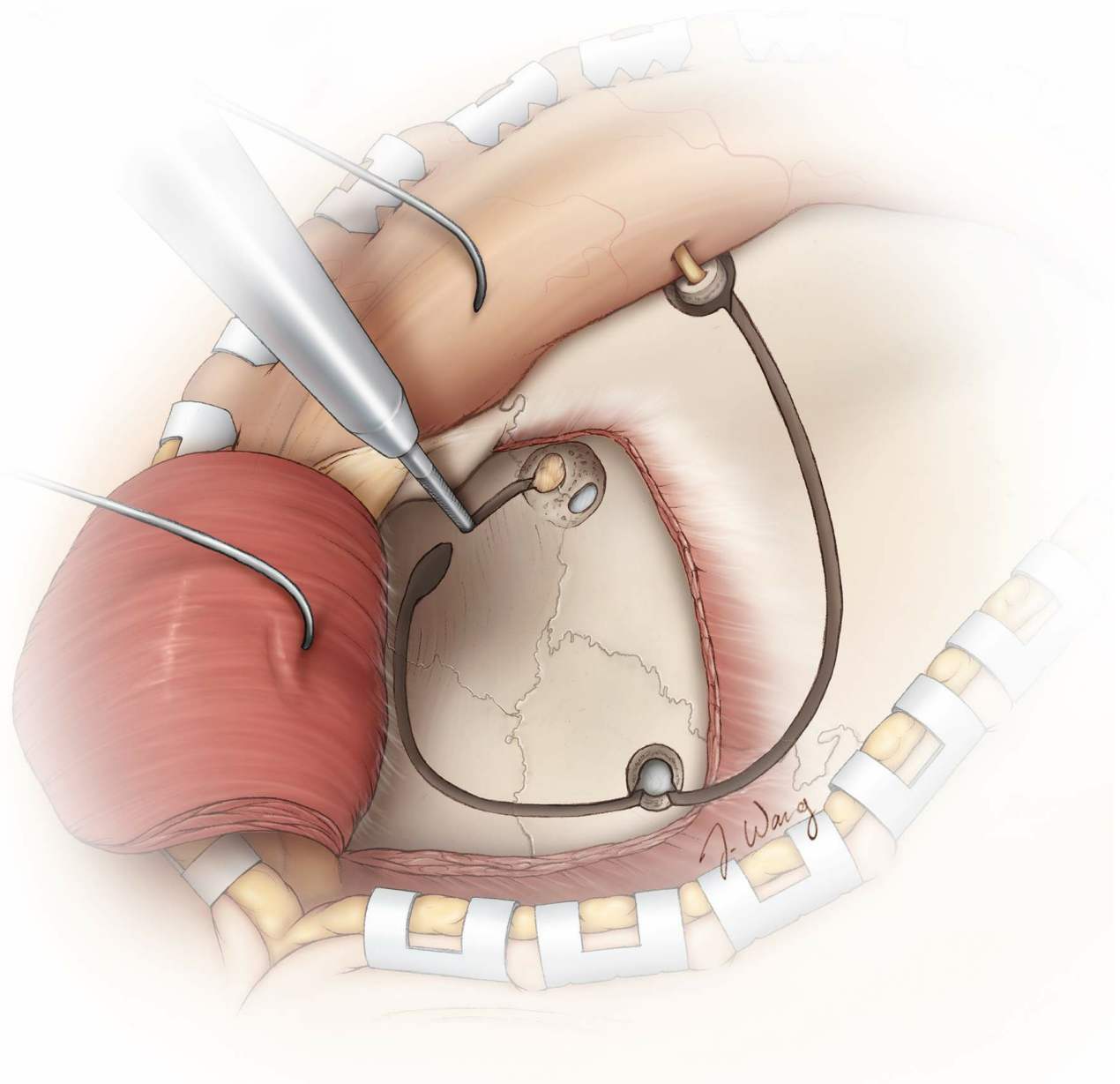


Figure 24: Next, I replace the footplate with a straight side-cutting B1 drill bit to perform the first orbital osteotomy. This cut involves connecting the orbital portion of the keyhole to the previous exit point of the craniotome via an osteotomy along the lateral wall of the orbit and sphenoid wing.

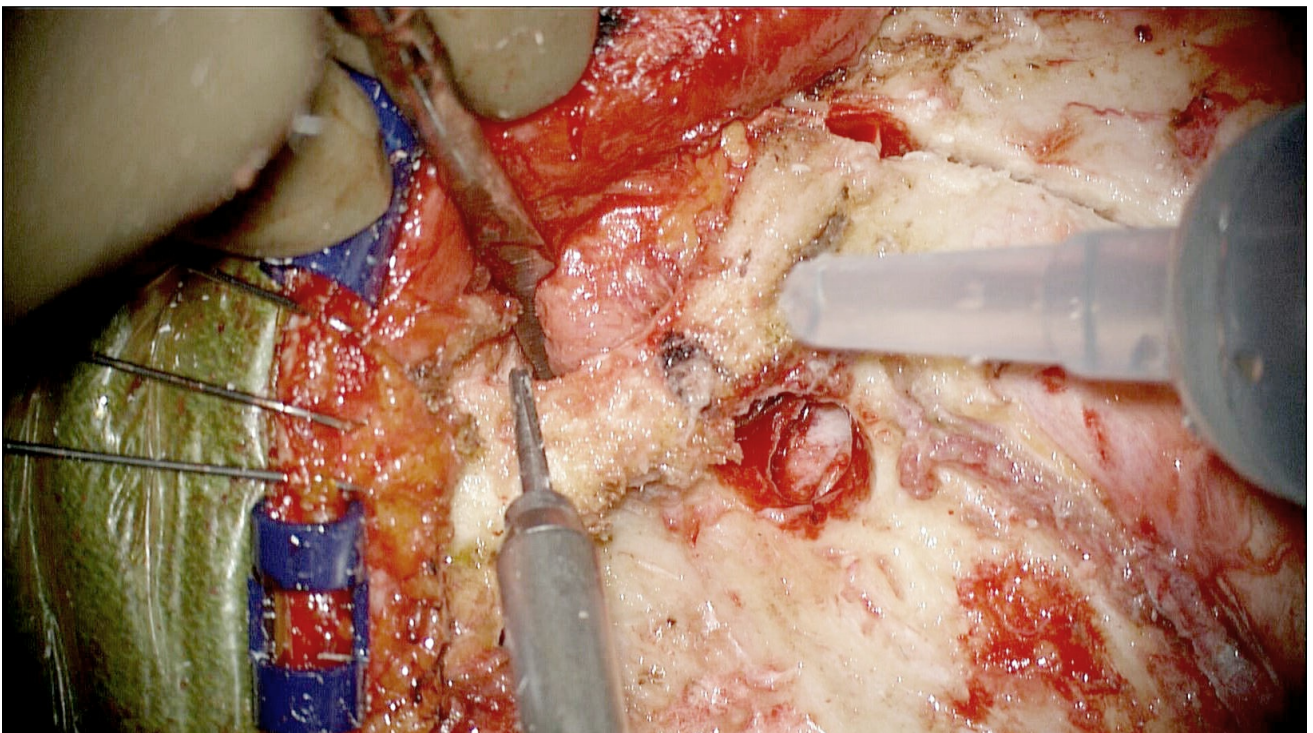
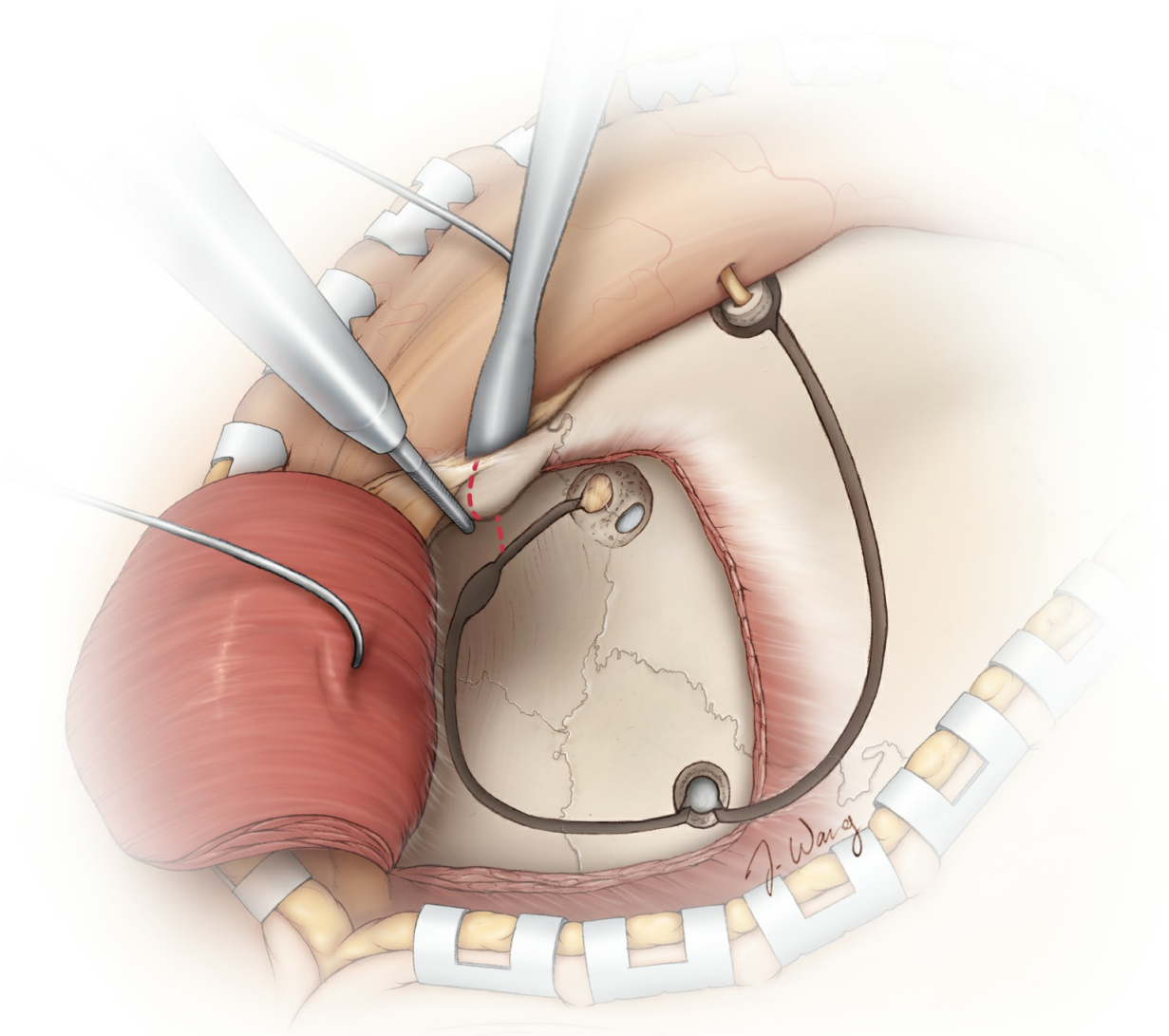


Figure 25: Next, the same straight side-cutting drill bit is used to cut the zygomatic process about 2 centimeters inferior to the frontozygomatic

suture. A spatula protects the intraorbital contents. The last two osteotomies disconnect the frontal zygomatic process.

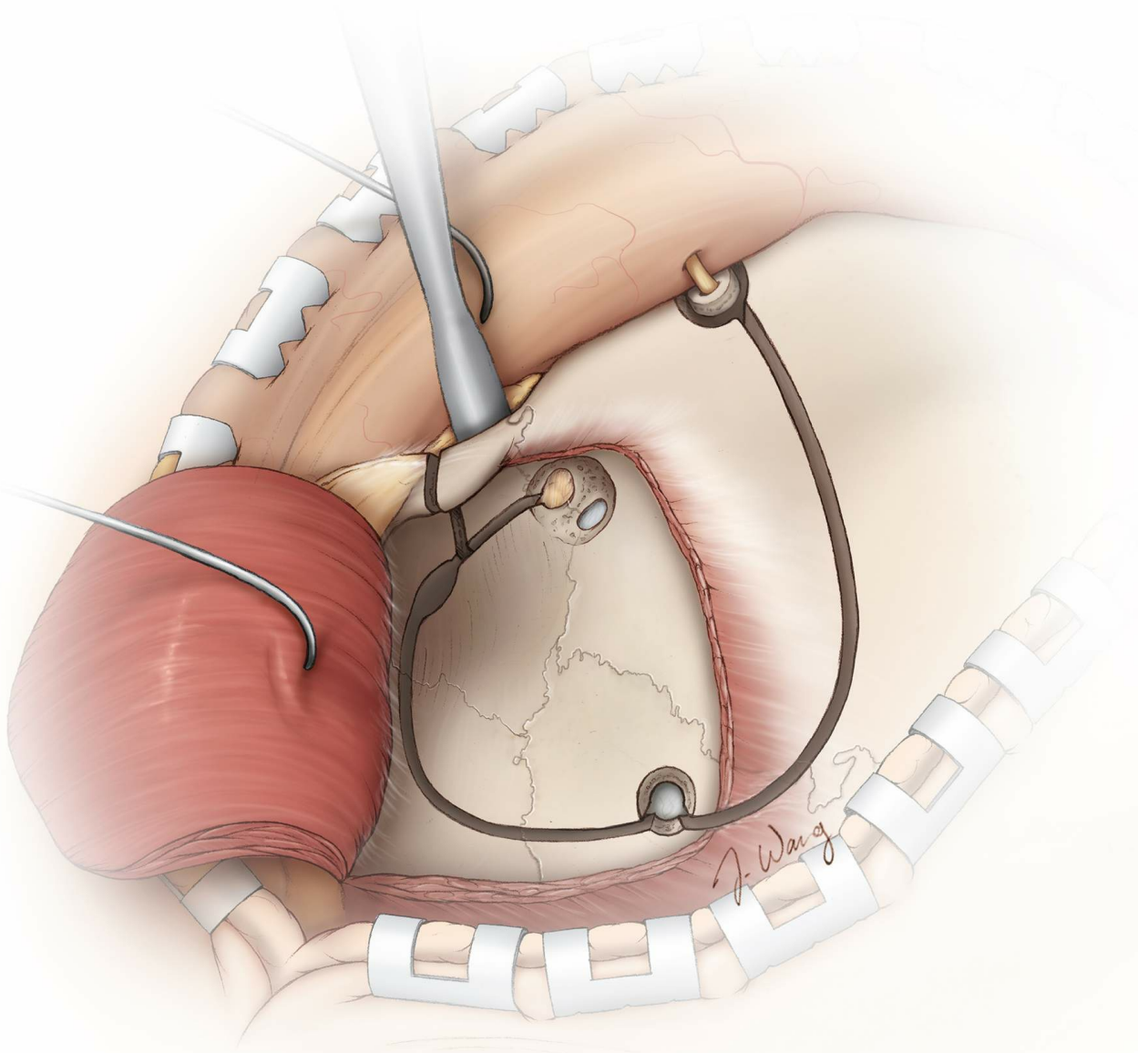


Figure 26: The periorbita is further dissected away from the lateral orbital wall and the roof in preparation for the next osteotomy.

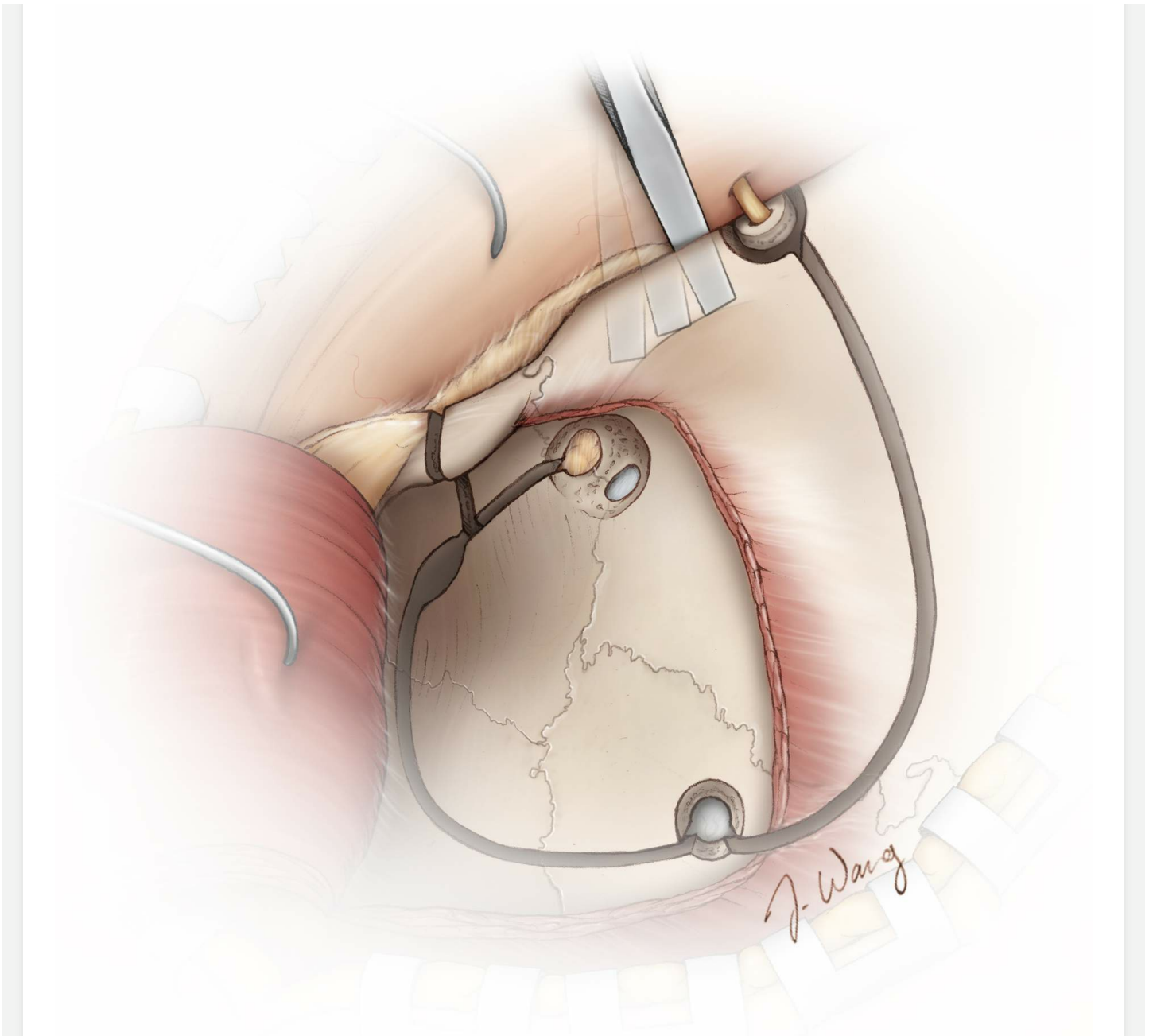


Figure 27: A thin, small osteotome is used to perform the final osteotomy along the orbital roof from medial to lateral direction, starting at the osteotomy that was used to release the supraorbital nerve. The bone of the orbital roof can be very thin, and excessive force while using the mallet should be avoided.

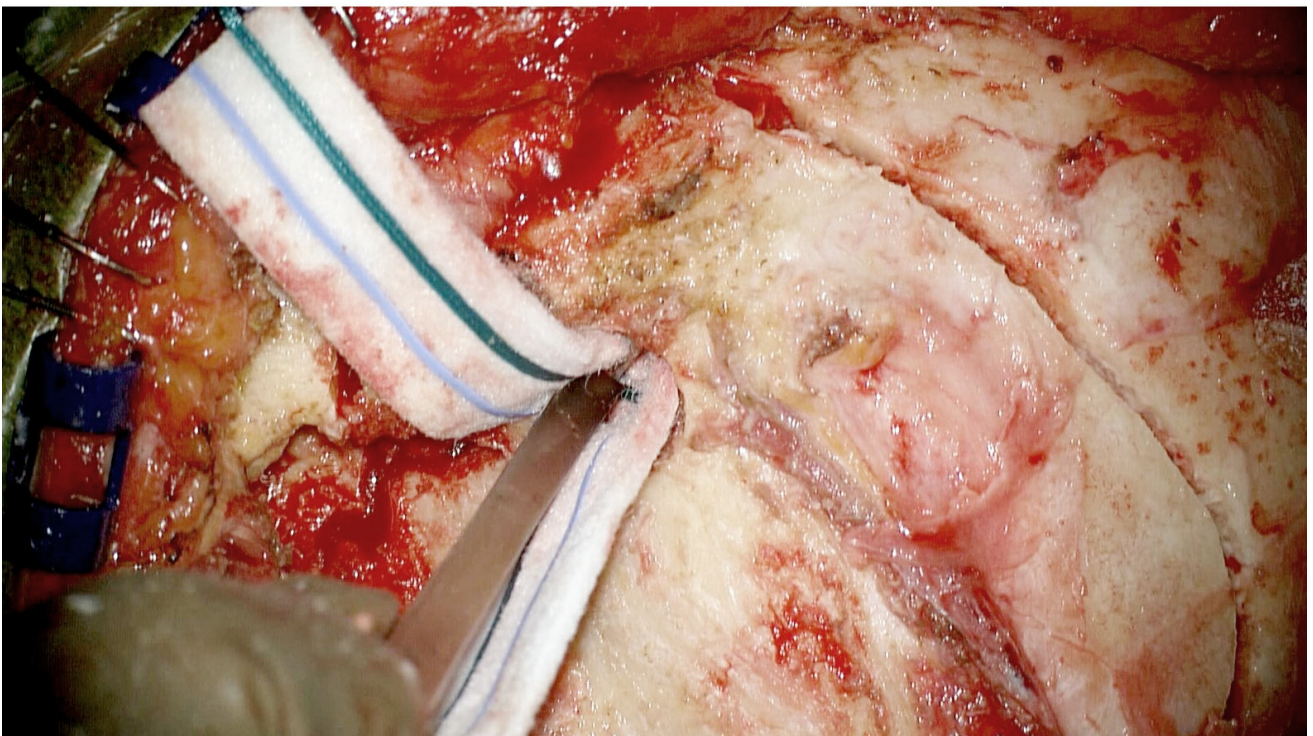
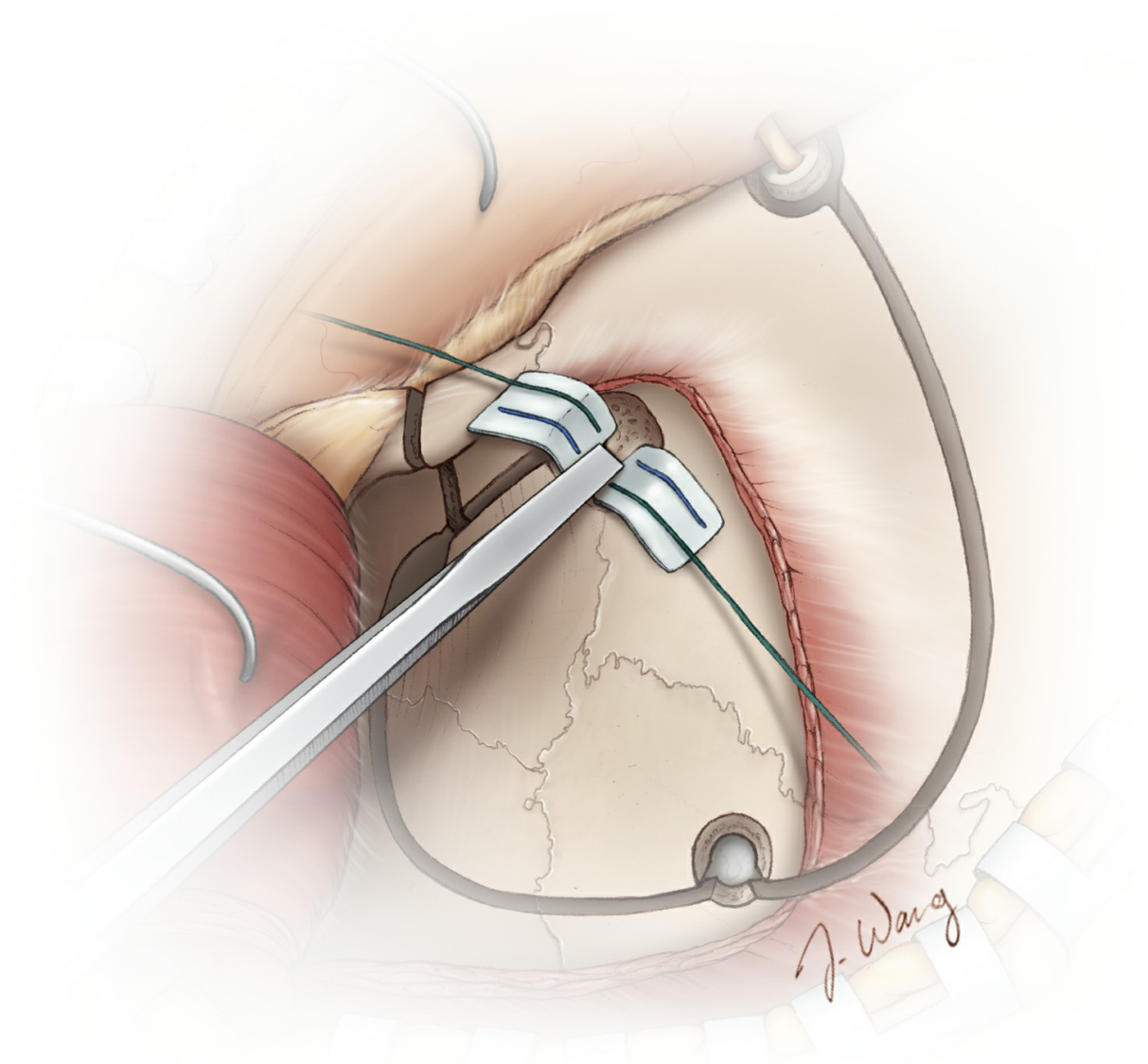


Figure 28: An alternative method for completing the orbital roof

osteotomy involves the use of a small thin osteotome to cut across the roof of the orbit through the keyhole. Two cotton patties may be used to protect the frontal dura posteriorly and the periorbital inferiorly from the osteotome.

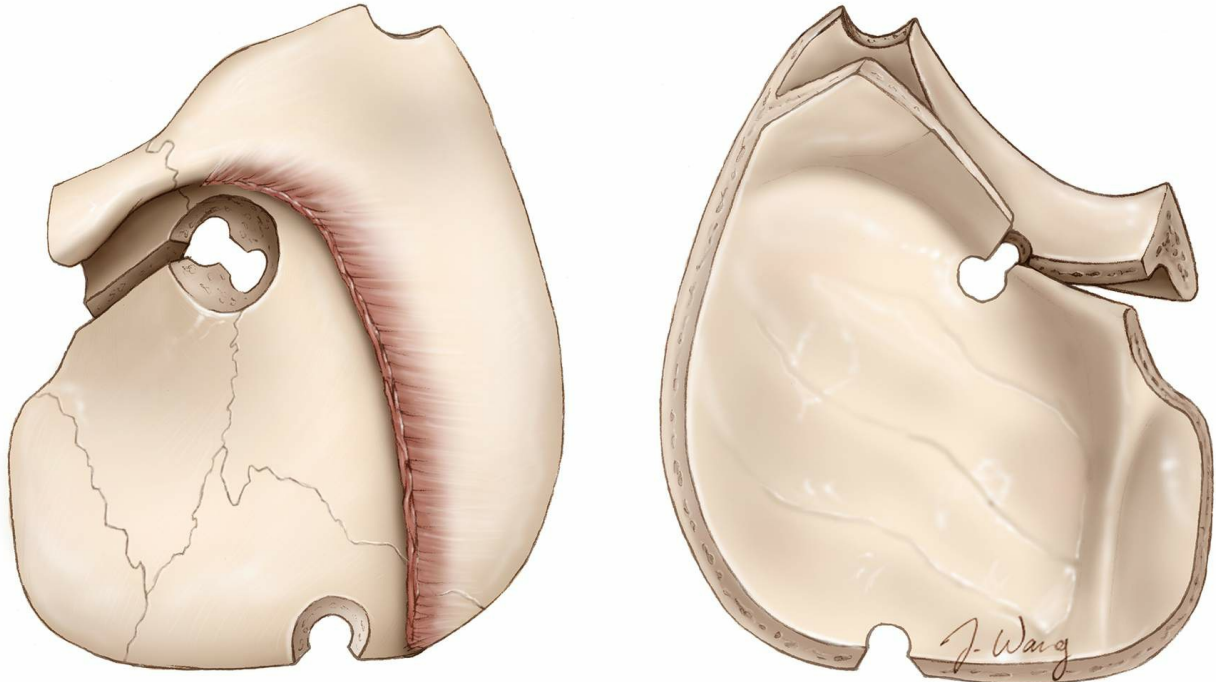


Figure 29: Once the craniotomy as well as the zygomatic and orbital osteotomies are complete, the one-piece modified OZ bone flap is free and can be carefully elevated. If the frontal sinus is entered, its mucosa should be thoroughly curetted away/removed and the sinus packed with muscle and bone wax. The vascularized pericranial flap may be used for its coverage during the closure stage.

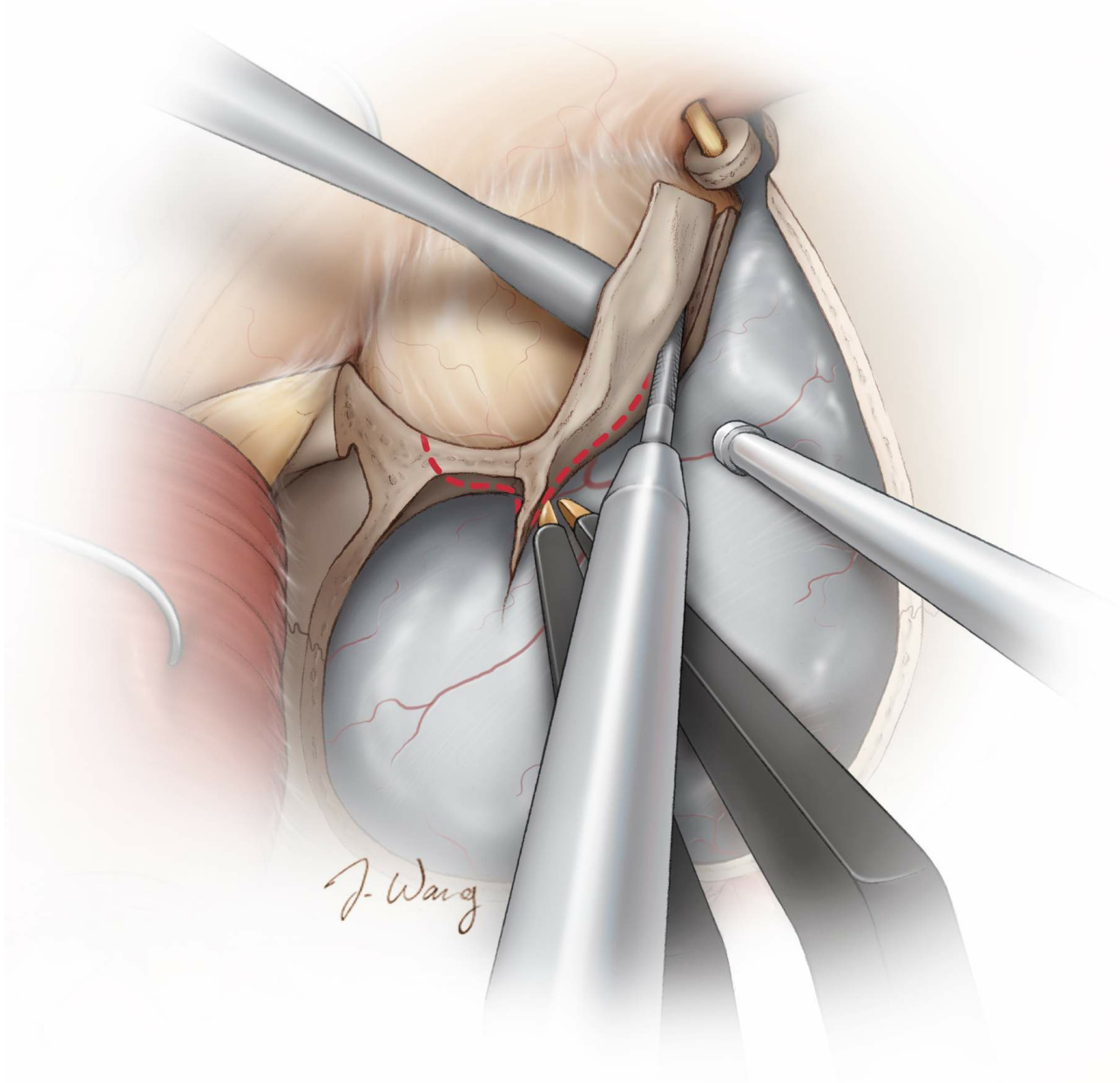


Figure 30: Once the cranio-orbital bone flap is elevated, additional bone from the anterolateral aspect of the orbital roof is removed and the lesser sphenoid wing is further reduced. A straight side-cutting B1 drill bit is used for this purpose. The orbital contents are protected. This small piece of orbital roof may not need to be replaced during closure.

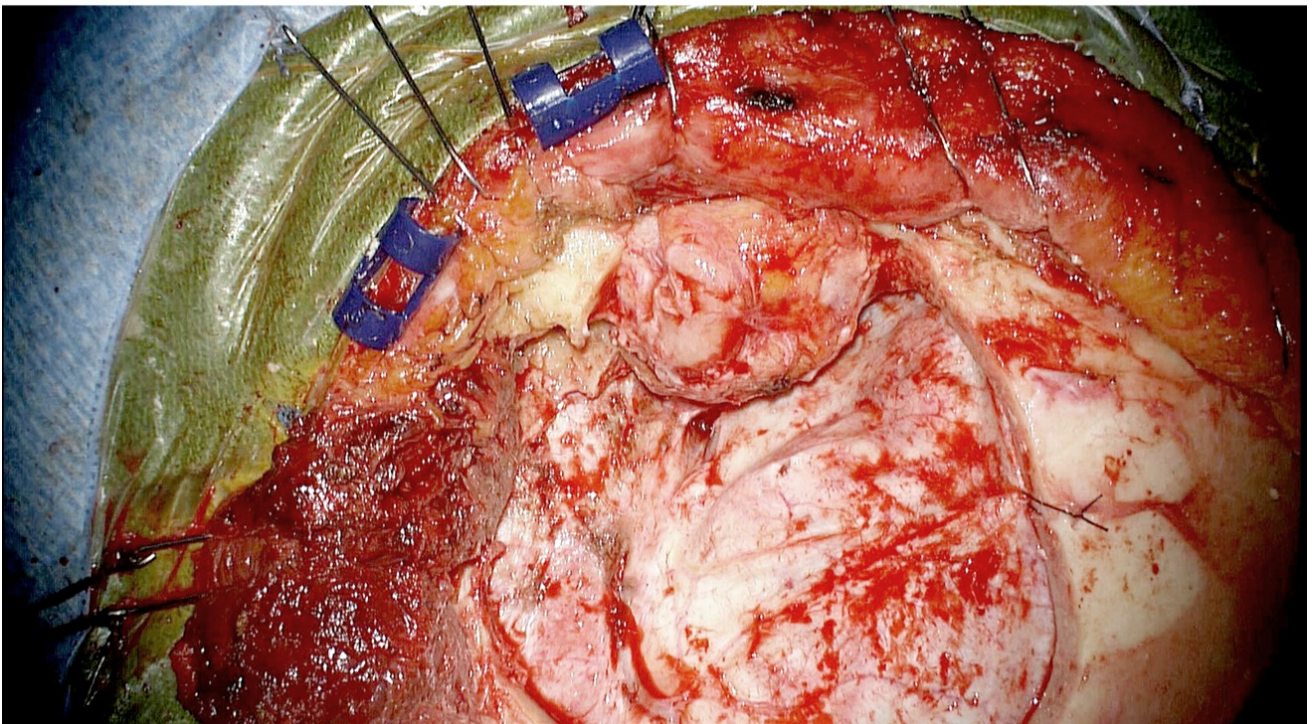
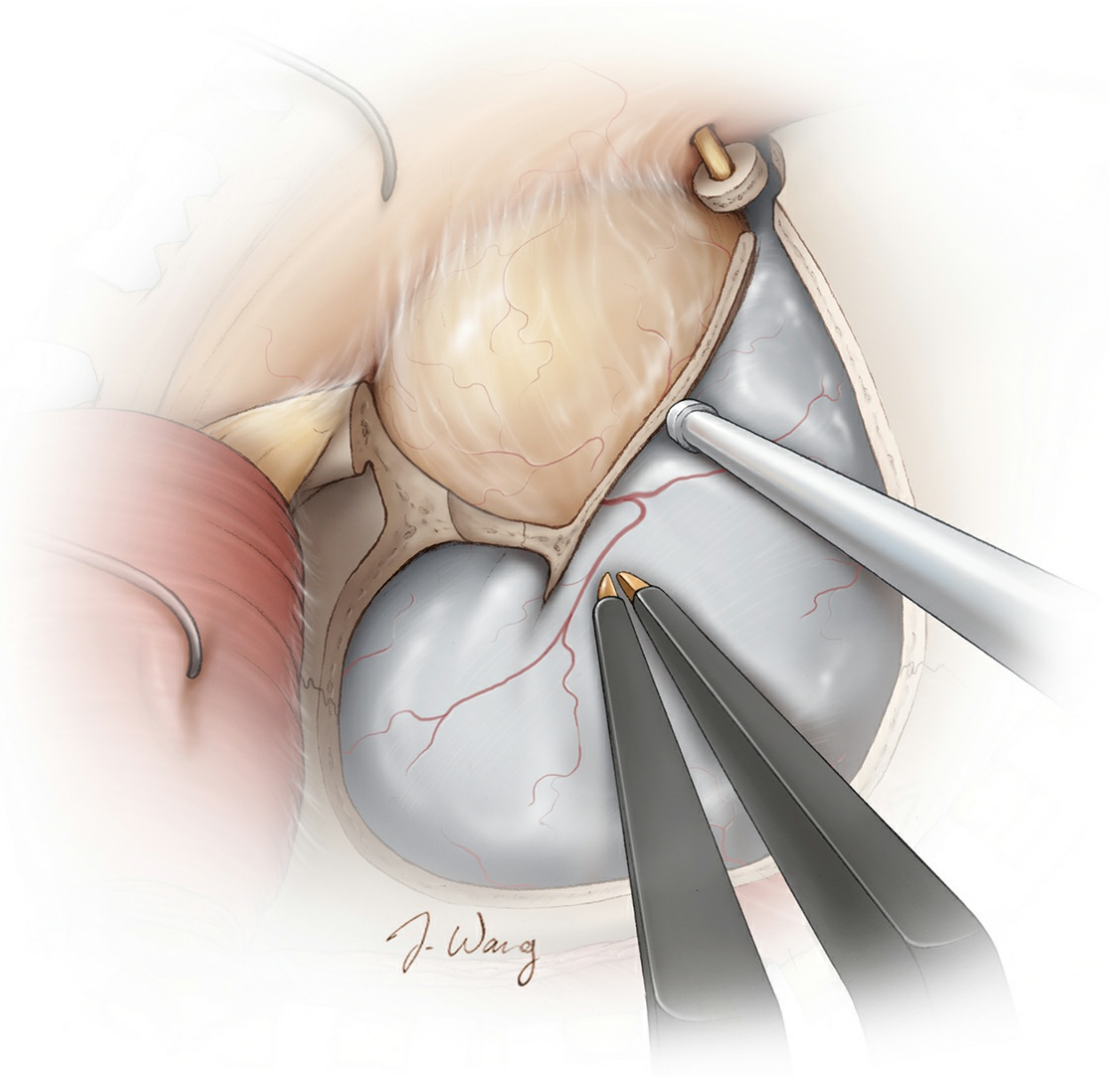


Figure 31: Additional bony removal along the subfrontal corridor can be

tailored based on the location of the lesion. An extradural clinoidectomy may be necessary for lesions round the proximal internal carotid artery along the skull base. The clinoidectomy provides an early decompression of the optic nerve at its foramen before the adjacent compressive tumor is manipulated.

Extradural Clinoidectomy

For more details regarding [extradural clinoidectomy](#), please refer to its dedicated chapter in the [Cranial Approaches](#) volume.

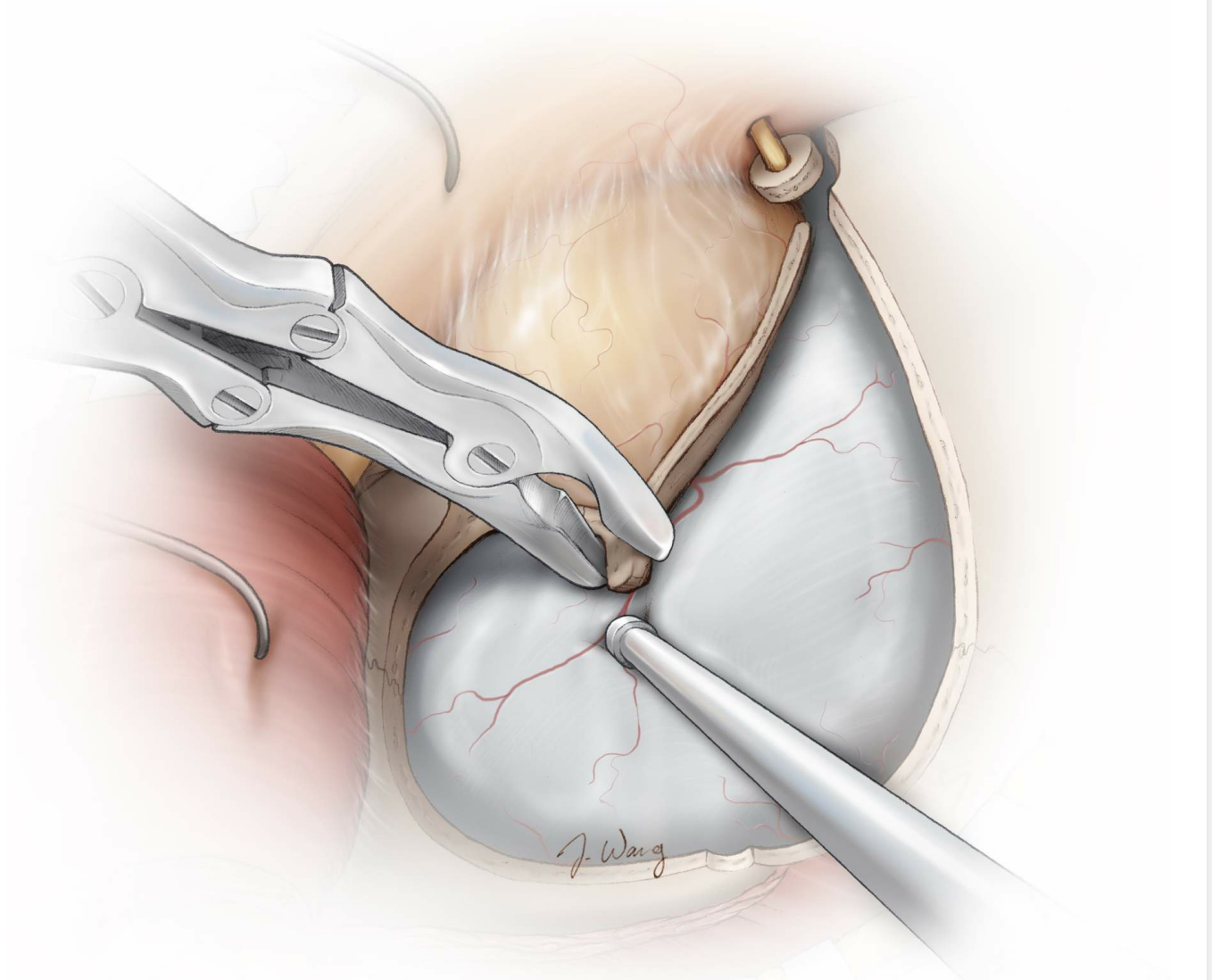


Figure 32: The dura is further dissected away from the floor of the anterior and middle fossa to expose the lesser sphenoid wing. A retractor may be used to protect the frontal lobe and facilitate further exposure. The lesser sphenoid wing is removed using rongeurs or a cutting burr. CSF drainage through the lumbar drain can significantly facilitate

mobilization of the dura at this and later stage(s).

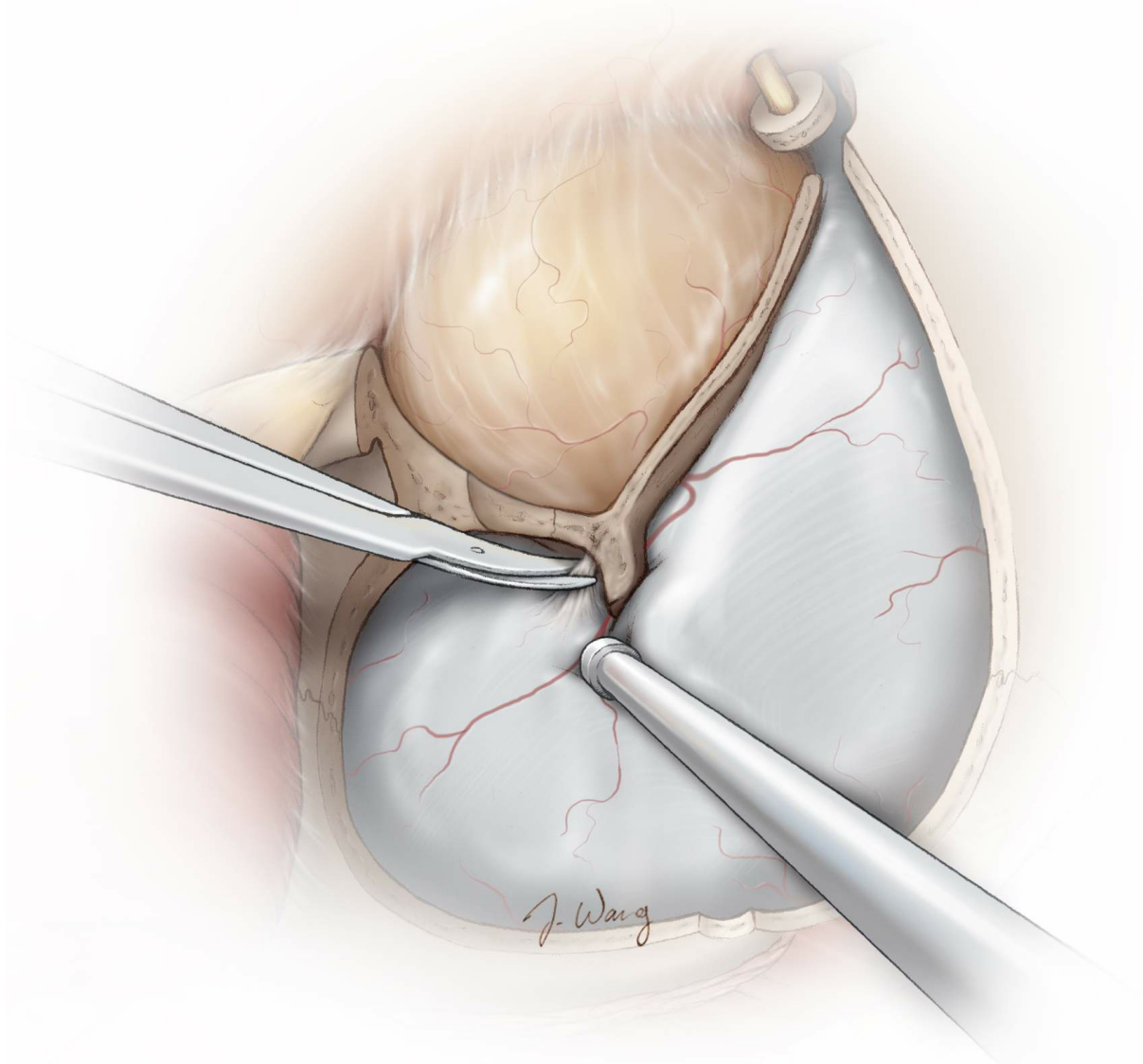


Figure 33: After further reduction of the lesser sphenoid wing, the superior orbital fissure is identified and the dura is detached further medially. At this point, the meningo-orbital band is encountered. This frontotemporal dural fold represents the connection between the dura of the middle fossa and periorbita through the superior orbital fissure. This band prevents further stripping of the dura medially and may be cut for ~5 mm to facilitate exposure of the anterior clinoid process through retraction of the frontotemporal dura.

The lateral 5 mm of the meningo-orbital band can be safely coagulated with bipolar electrocautery and divided using heavy microscissors. Further blunt reflection of the external dural fold of the cavernous sinus renders a wider exposure of the medial clinoid process.

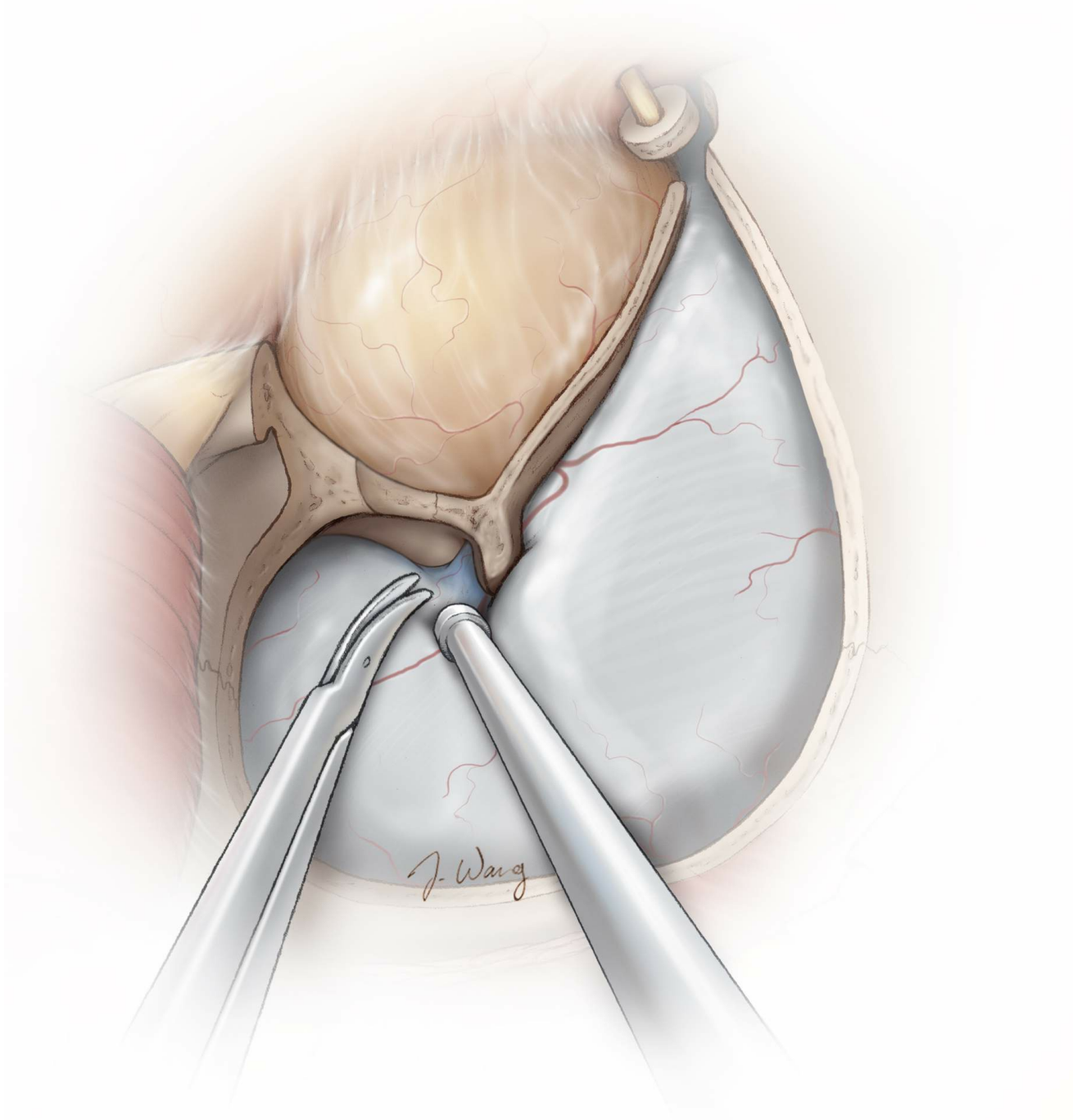


Figure 34: After the meningo-orbital band is released, further dural detachment along the superior orbital fissure can be performed to expand the exposure of the anterior clinoid process. On the temporal side, a plane between the temporal dura and the cavernous sinus dura can be developed. The temporal dura is peeled away from the anterior aspect of the cavernous sinus and the orbital apex. This maneuver facilitates further dural elevation along the medial aspect of the anterior clinoid process. This maneuver may not be necessary in all cases.

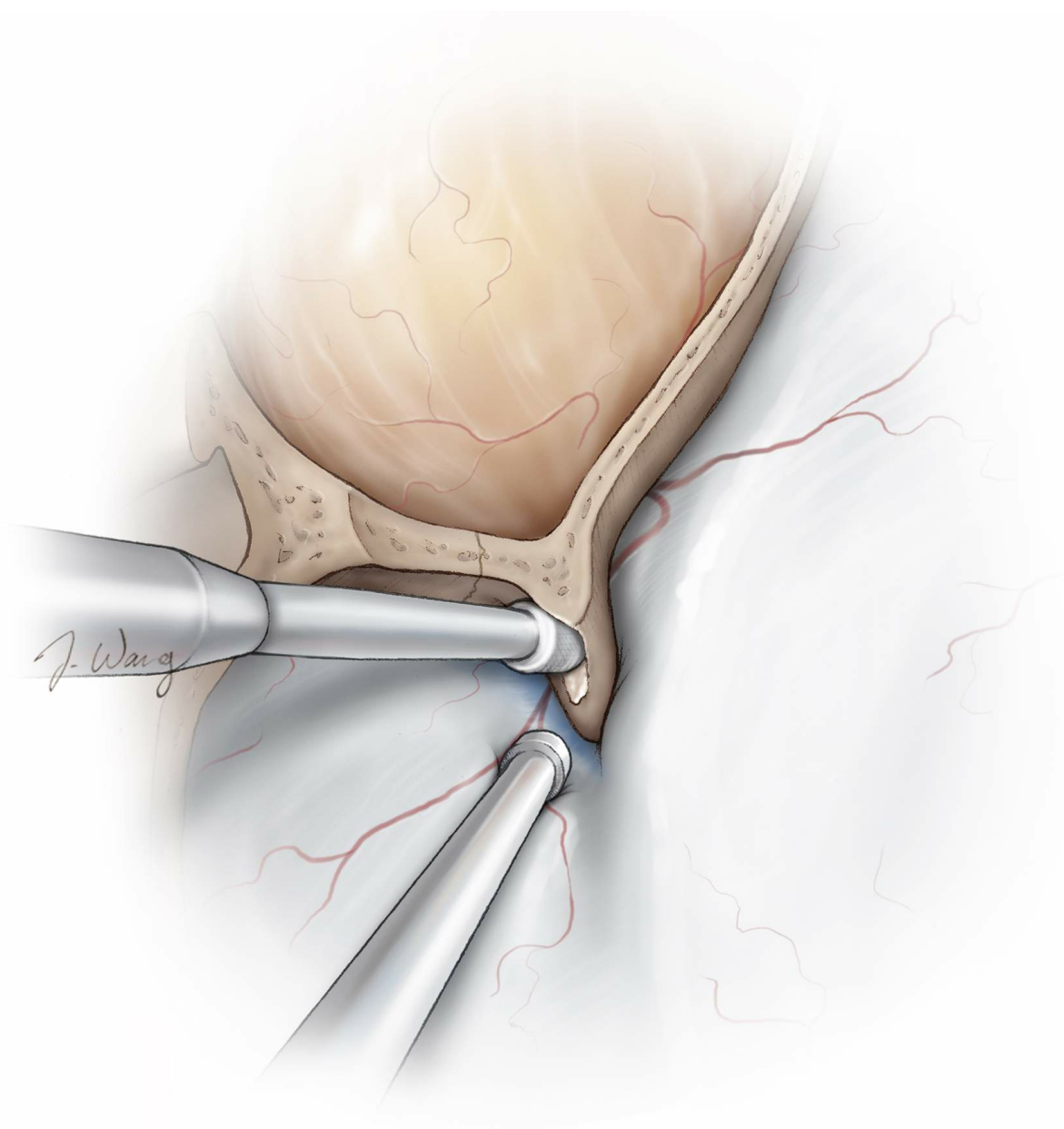


Figure 35: The remaining portion of the lesser sphenoid wing overlying the supralateral margin of the superior orbital fissure is resected. The portion of the greater sphenoid wing that forms the inferolateral wall of the superior orbital fissure is also partially removed. A diamond burr can be used for this purpose. Continuous cooling irrigation must be used to prevent overheating of the bone and thermal injury to the surrounding structures. Completion of this step provides further mobility for the contents of the superior orbital fissure.

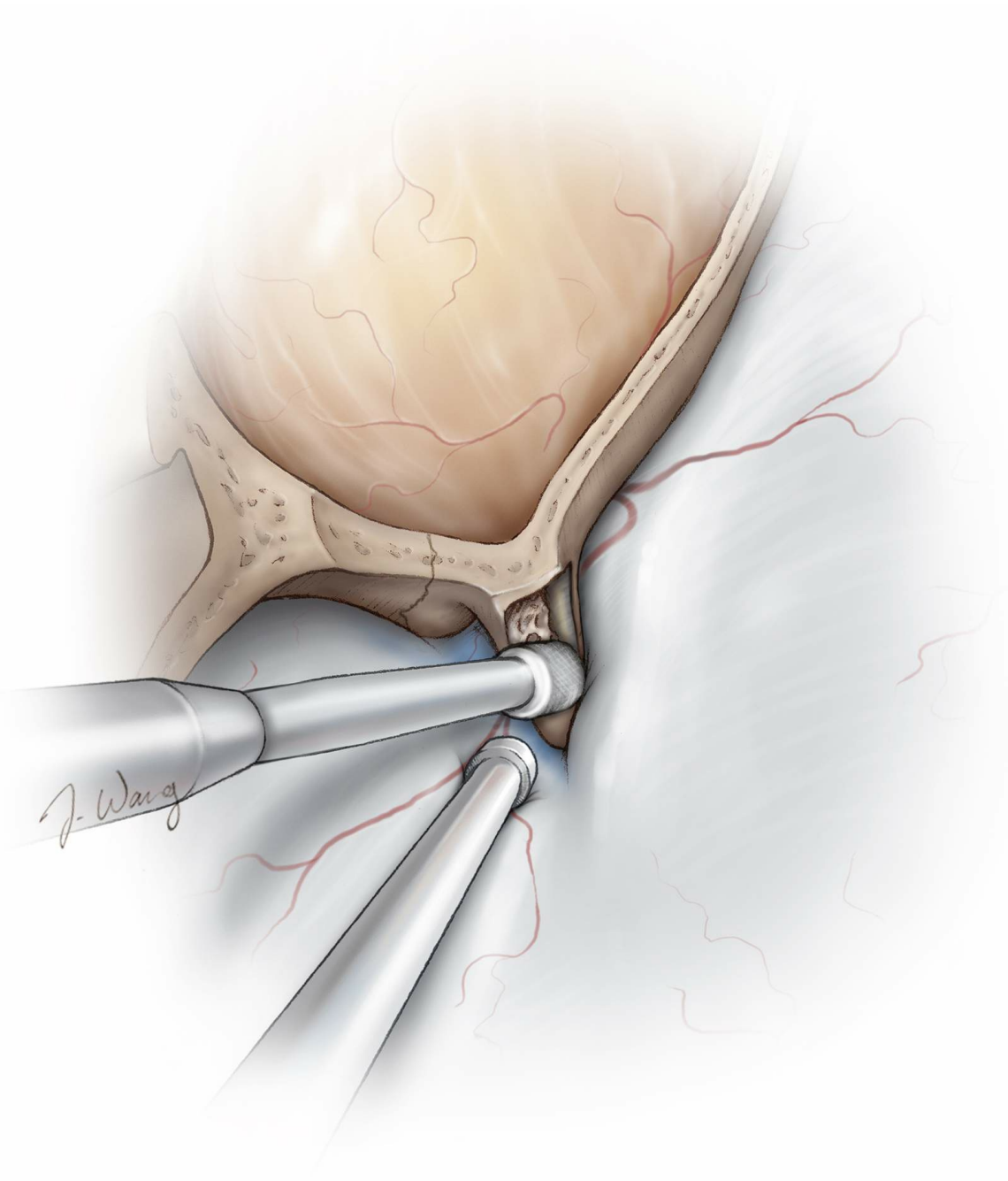


Figure 36: The bone medial to the clinoid process and over the optic foramen and is removed and the optic nerve is untethered before further manipulation of the clinoid process is attempted. The bone over the nerve is thin and often easily identified from the bone of the posterior and medial aspects of the anterior cranial fossa. This maneuver will release the nerve from its foramen and minimizes injury to the nerve during manipulation and mobilization of the clinoid process. Ample irrigation is used to avoid heat injury to the nerve. The anterior clinoid process is then generously and centrally cored out using a diamond burr to detach the process from the optic strut.

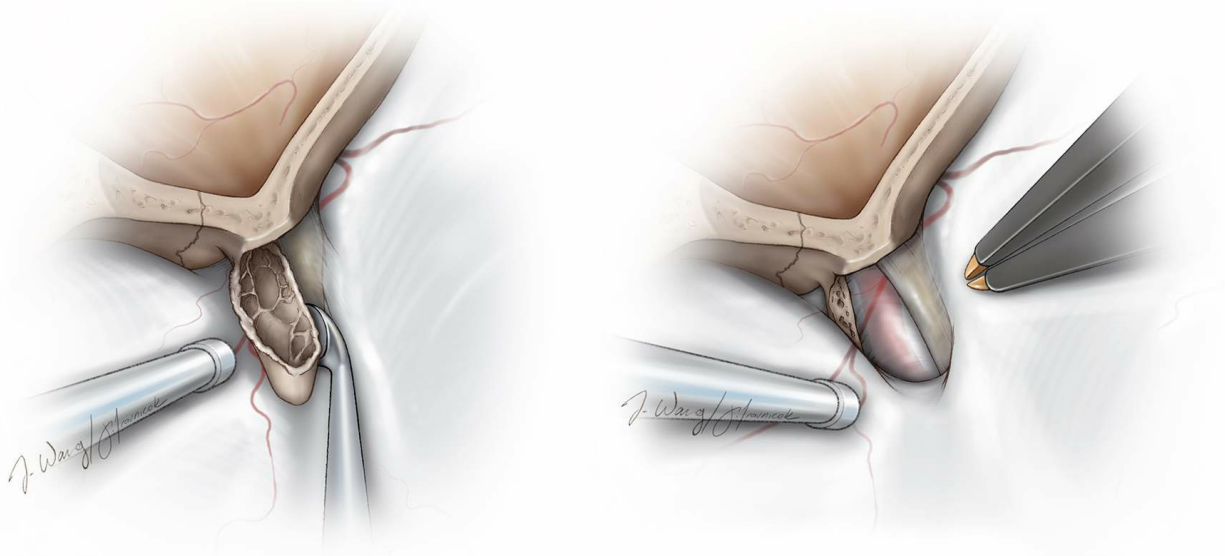


Figure 37: The centrally shelled clinoid is circumferentially dissected from the surrounding dural folds, including the clinoid ligaments, and can be removed using pituitary rongeurs. Venous bleeding from the cavernous sinus is easily controlled with thrombin-soaked Gelfoam packing.

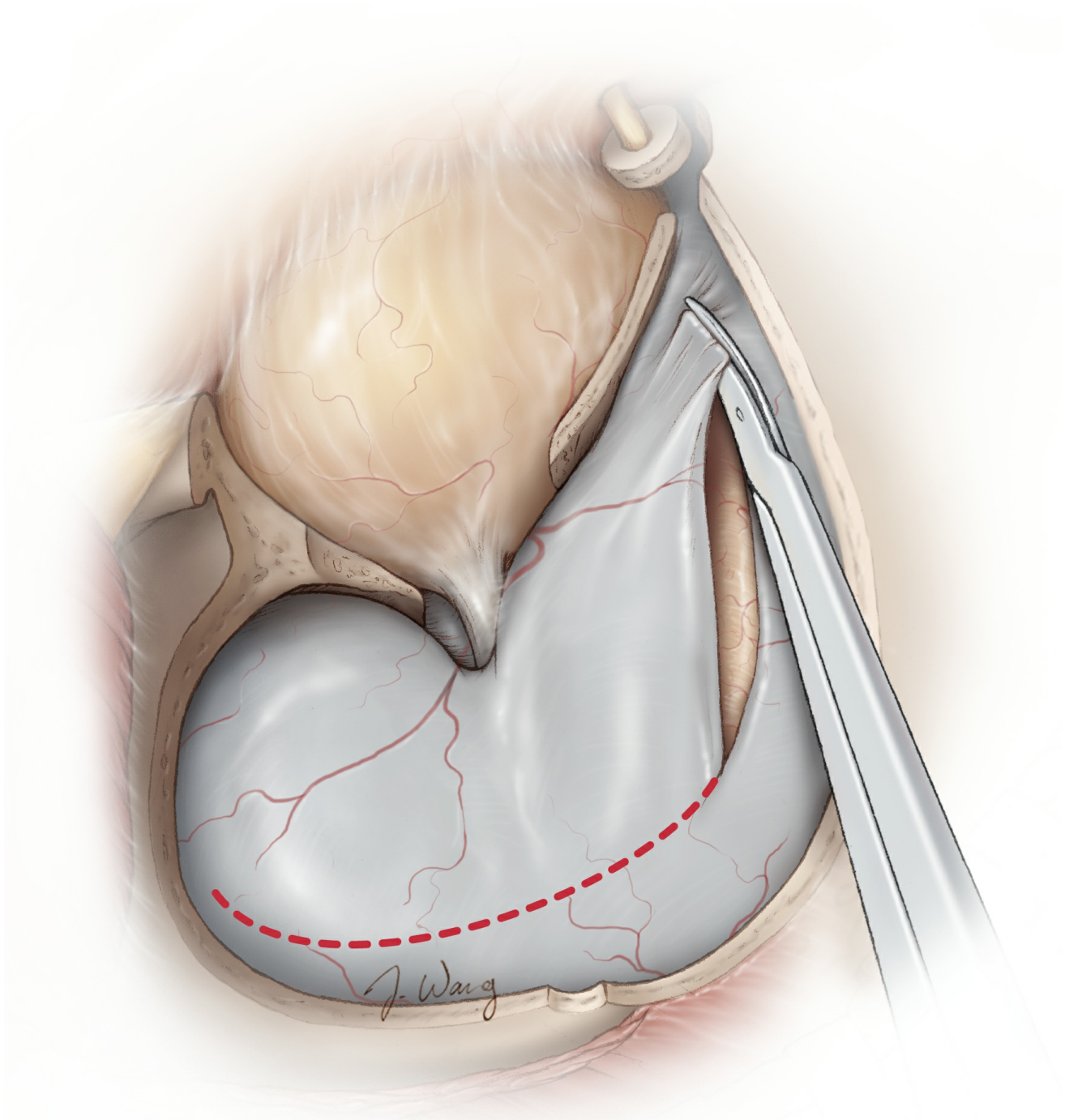


Figure 39: The dura is incised in a semicircular shape with its base toward the orbital apex. The goal of this incision is to expose the superior temporal gyrus, Sylvian fissure, and inferior frontal gyrus. It is important to extend the frontal incision to the corner of the craniotomy to facilitate subfrontal access.

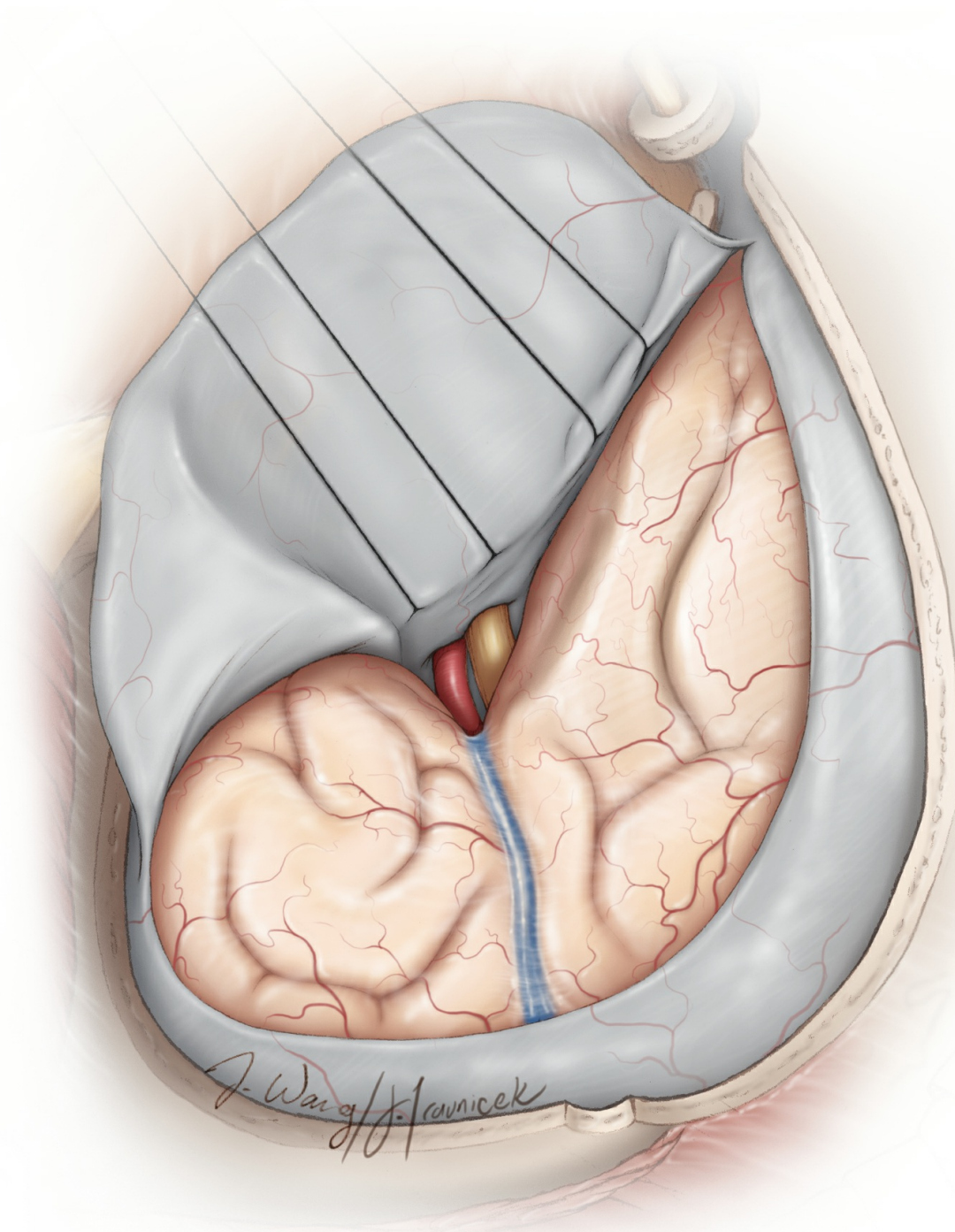


Figure 40: Several dural retention sutures are placed to improve exposure. These sutures are placed at the base of the dural flap rather than at its edge so that the intradural subfrontal trajectory is least affected by the orbital contents and other soft tissues including the temporalis muscle.

Closure

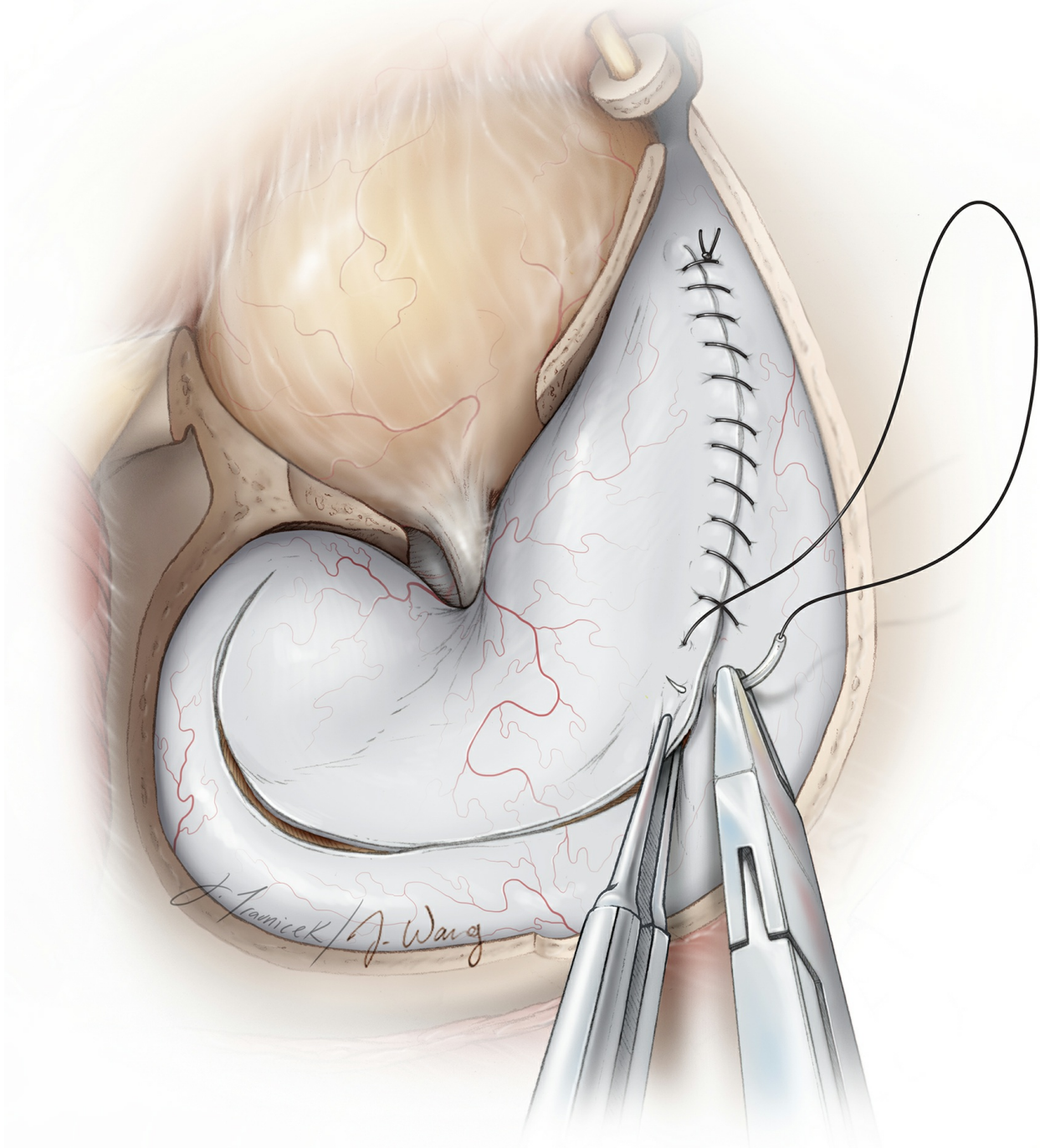


Figure 41: The dura is closed in standard fashion. If the frontal sinus had been entered, every attempt should be made to complete a watertight dural closure. The mucosa of the frontal sinus is completely removed and the sinus is filled with pieces of temporalis muscle. The routine use of a vascularized pericranial graft to cover the exenterated frontal sinus is recommended. Please refer to the [Bifrontal Craniotomy](#) chapter for further details.

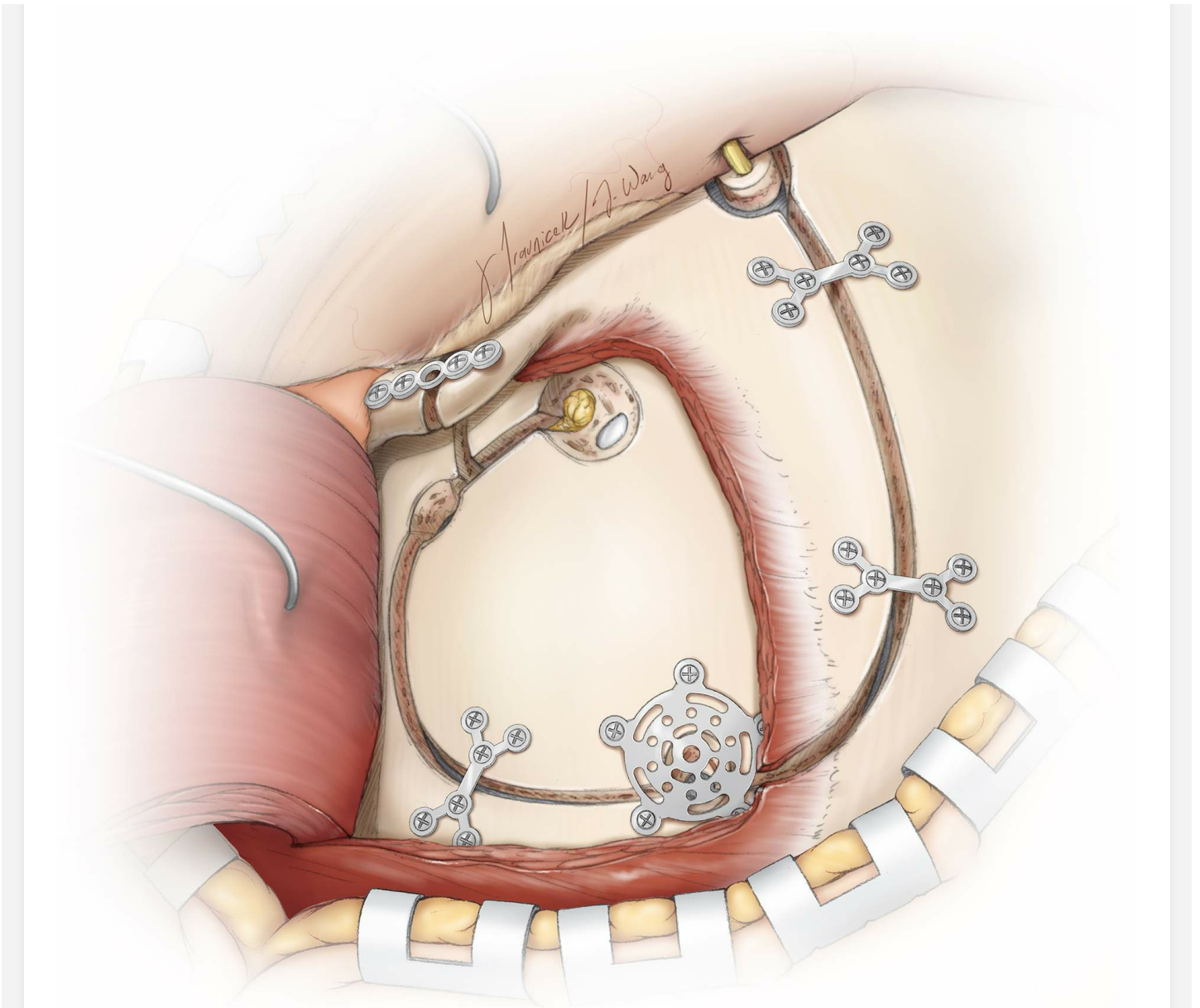


Figure 42: The bone flap is replaced and secured using miniplates. A small miniplate is used to secure the bone flap to the frontal process of the zygoma. Cranioplasty material may be used to fill in the bony defects.

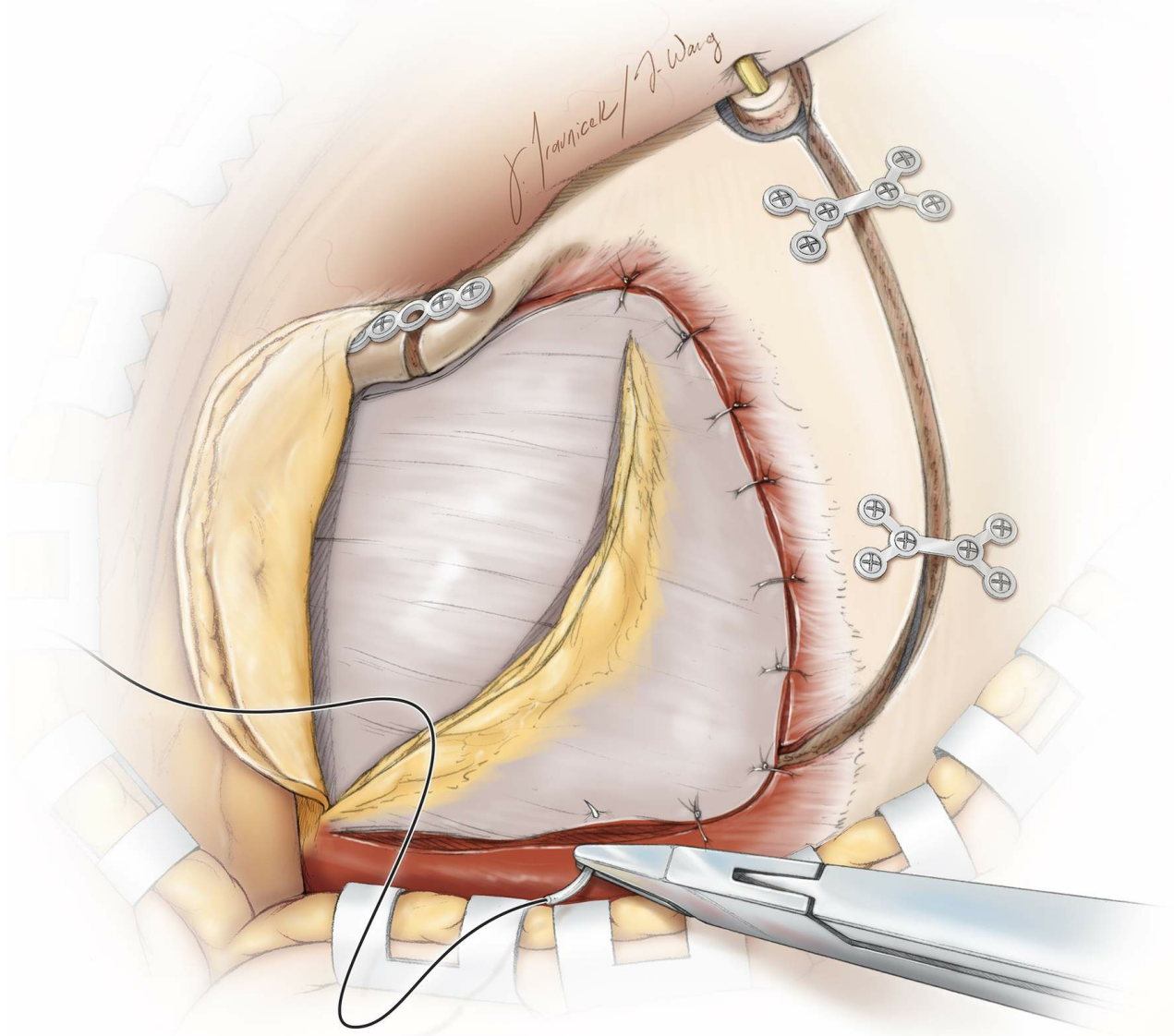


Figure 43: The muscle is secured in place using the tendon and muscle cuffs created at the time of exposure. The fat pad may be reflected back to its original position.

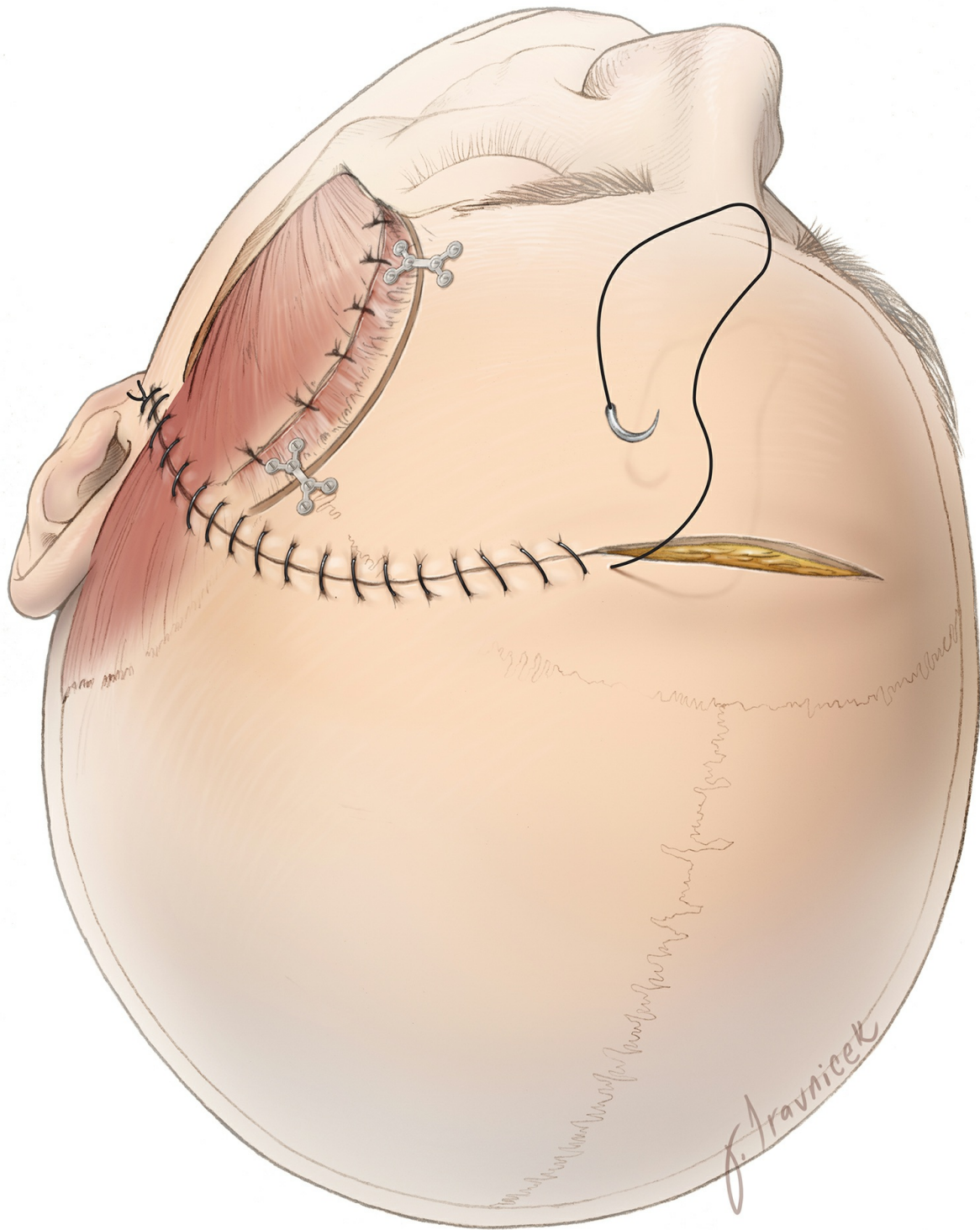


Figure 44: The scalp flap is approximated via closure of the galea and the skin is closed using absorbable sutures.

Important Considerations

The judicious indications for the use of an OZ osteotomy are important. The following clarifies the specific operative corridors expanded via the OZ.

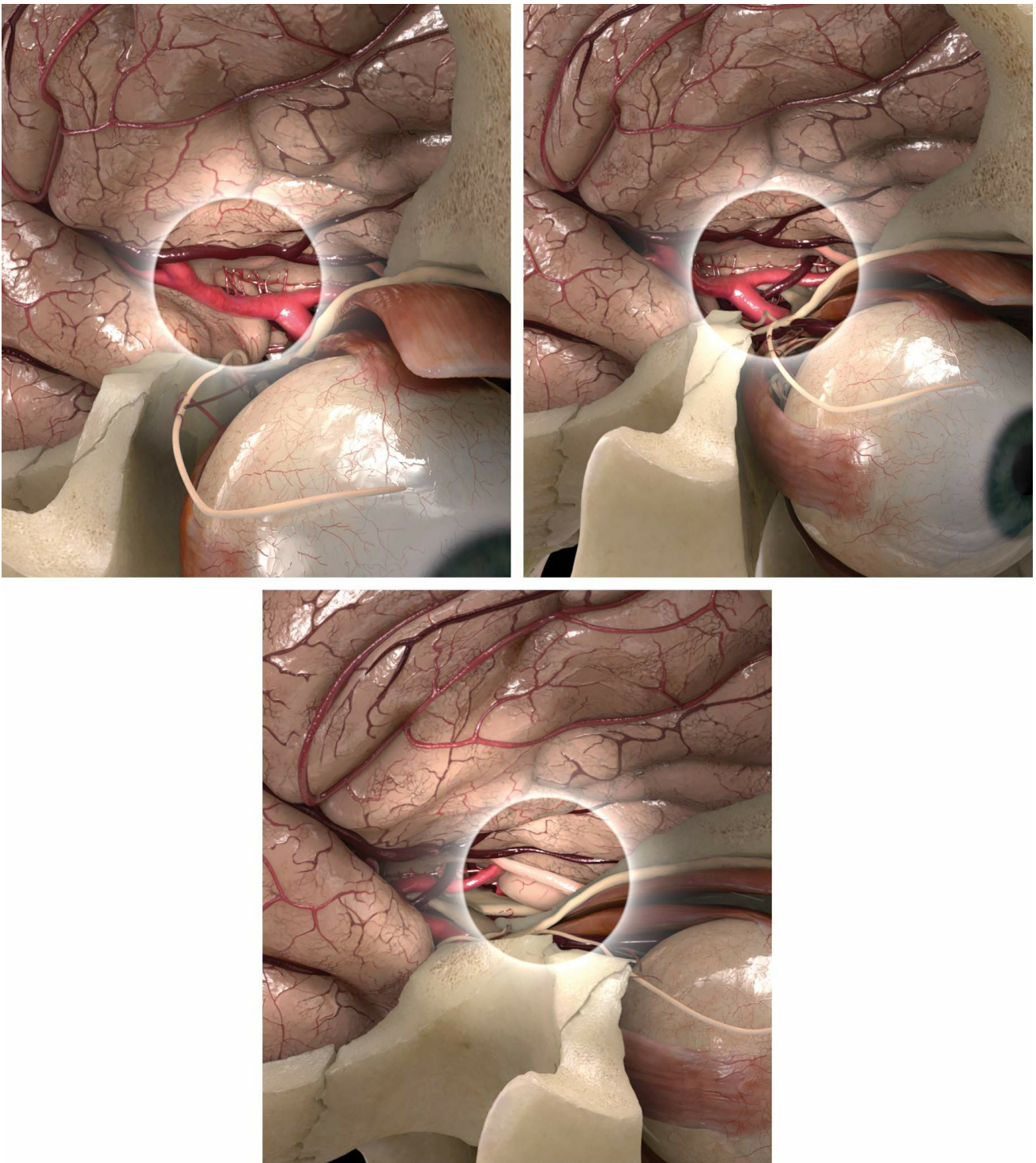


Figure 45: The OZ provides an expanded trajectory toward the anterior sylvian fissure and the M1 (top left image.) This corridor remains expanded for the region of the carotid bifurcation and proximal A1 (top right image.) However, expansion of the operative trajectory is significantly less effective for lesions anterior to the chiasm because of the bulk of the orbital contents and medial orbital roof (bottom image.)

Pearls and Pitfalls

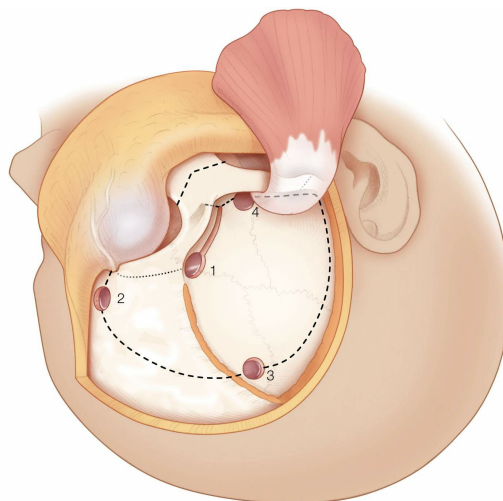
- Selective use of OZ is highly recommended. I use the modified OZ for “high-riding” lesions extending superiorly within the

parasellar/third ventricular/interpeduncular spaces and the posterior one-third of the orbit.

- Accurate placement of the keyhole is important for successfully completing a one-piece OZ.
- Indiscriminate and blind fracture of the orbital roof should be avoided during exposure of anterior skull base meningiomas. Due to resultant hyperostosis of the orbital roof, the fracture may extend to the level of the optic canal and result in optic nerve injury.

Contributor: Roberto Rey-Dios, MD

For additional illustrations of orbitozygomatic approaches, please refer to the Jackler Atlas by clicking on the image below:



DOI: <https://doi.org/10.18791/nsatlas.v5.ch04.1>

REFERENCES

Al-Mefty O. *Operative Atlas of Meningiomas*. Philadelphia: Lippincott-Raven, 1998.

Balasingam V, Noguchi A, McMenemy SO, Delashaw JB Jr. Modified osteoplastic orbitozygomatic craniotomy. Technical note. *J Neurosurg*. 2005; 102: 940-944

Lemole GM Jr, Henn JS, Zabramski JM, Spetzler RF. Modifications to the orbitozygomatic approach. Technical note. *J Neurosurg*. 2003; 99:

924-930.

Noguchi A, Balasingam V, Shiokawa Y, McMenomey SO, Delashaw JB Jr. Extradural anterior clinoidectomy. Technical note. *J Neurosurg*. 2005; 102: 945-950

Oikawa S, Mizuno M, Muraoka S, Kobayashi S. Retrograde dissection of the temporalis muscle preventing muscle atrophy for pterional craniotomy. Technical note. *J Neurosurg*. 1996; 84: 297-299

Seçkin H, Avcı E, Uluç K, Niemann D, Başkaya MK. The work horse of skull base surgery: orbitozygomatic approach. Technique, modifications, and applications. *Neurosurg Focus*. 2008; 25: E4.

Tew JM Jr, van Loveren HR, Keller JT. *Atlas of Operative Microneurosurgery, Vol 1*. Philadelphia: Saunders, 1994.

Tew JM Jr, van Loveren HR, Keller JT. *Atlas of Operative Microneurosurgery, Vol 2*. Philadelphia: Saunders, 2001.

Tubbs RS, Loukas M, Shoja MM, [Cohen-Gadol AA](#). Refined and simplified surgical landmarks for the MacCarty keyhole and orbitozygomatic craniotomy. *Neurosurgery*. 2010; 66(6 Suppl Operative): 230-233

Related Materials

Available Through the Atlas

 Orbitozygomatic craniotomy: Technical note

 Sphenoorbital meningiomas: Surgical limitations and lessons learn...

 Quantification of increased exposure resulting from orbital rim a...

 Subfascial and submuscular methods of temporal muscle dissection...

 Modifications to the orbitozygomatic approach: Technical note

 Anatomical and quantitative description of the transcavernous app...

 Anatomical study of the orbitozygomatic transsellar-transcavernou...

 Surgical nuances for removal of retrochiasmatic craniopharyngioma...

 The quiet revolution: Retractorless surgery for complex vascular...

 Modified orbitozygomatic craniotomy for craniopharyngioma resecti...

 Modified osteoplastic orbitozygomatic craniotomy: Technical note

 The extradural temporopolar approach: A review of indications and...


 The work horse of skull base surgery: Orbitozygomatic approach. T...

Unavailable Through the Atlas

 The Anterior and Middle Cranial Base

 Working area and angle of attack in three cranial base approaches...

 Orbitozygomatic temporopolar approach for a high basilar tip aneu...

 An anatomical evaluation of the mini-supraorbital approach and co...

 The pretemporal transcavernous approach to the interpeduncular an...

 The orbitozygomatic infratemporal fossa approach: A quantitative...

 The one-piece orbitozygomatic approach: The MacCarty burr hole an...

 Evolution of surgical approaches in the treatment of petroclival...



The Carotid-oculomotor Window in Exposure of Upper Basilar Artery...



MacCarty keyhole and inferior orbital fissure in orbitozygomatic...



One-piece versus two-piece orbitozygomatic craniotomy: Quantitati...



Evolution and advances of the lateral surgical approaches to cran...



"Tangential" Resection of Medial Temporal Lobe Arteriovenous Malf...



Orbitozygomatic approach to basilar apex aneurysms



One-piece pedunculated frontotemporal orbitozygomatic craniotomy...



Role of the zygomaticofacial foramen in the orbitozygomatic crani...



Orbitozygomatic approach by transposition of temporalis muscle an...



Transciliary orbitofrontozygomatic approach to lesions of the ant...



The frontotemporal-orbitozygomatic approach: Reconstructive techn...



Modified osteoplastic orbitozygomatic craniotomy in the pediatric...



The orbitozygomatic approach



Three-piece orbitozygomatic approach



Frontotemporal orbitozygomatic craniotomy to expose the cavernous...



Refined and simplified surgical landmarks for the MacCarty keyhol...



A surgical modification for performing orbitozygomatic osteotomie...



Modified orbitozygomatic craniotomy for large medial sphenoid win...



The supracarotid-infracfrontal approach: Surgical technique and cl...



An anatomical analysis of the mini-modified orbitozygomatic and s...



Quantification of the frontotemporal orbitozygomatic approach usi...
