



Tuberculum Sella Meningioma

Last Updated: May 3, 2021

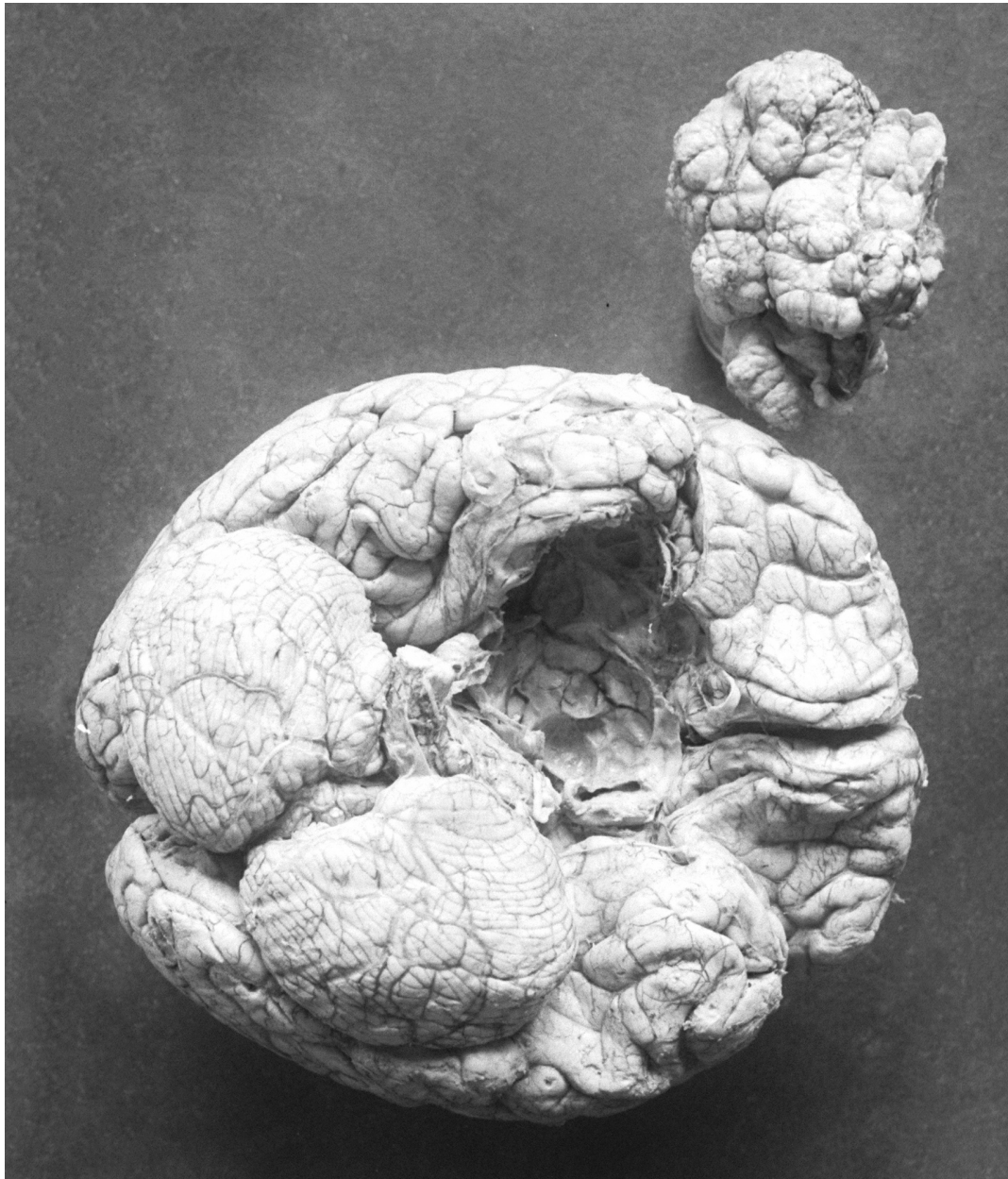


Figure 1: Harvey Cushing conducted the autopsy of one of his patients who had suffered most likely from a tuberculum sella or medial sphenoid wing meningioma (circa ~1913)(Image courtesy of the Cushing Brain Tumor Registry at Yale University).

This chapter reviews the techniques for transcranial resection of tuberculum sella meningiomas (TSMs). For details regarding endoscopic

transnasal removal of these tumors, please refer to the chapter on [Endoscopic Parasellar Meningioma Resection](#).

The TSMs comprise approximately 5% to 10% of all intracranial meningiomas and arise from the dura of the tuberculum sellae. This region includes the chiasmatic sulcus, limbus sphenoidale, and diaphragma sellae. The most common point of origin of these tumors is the junction of the optic canal and lateral aspect of the chiasmatic sulcus.

These tumors are anatomically closely related to the origin of olfactory groove meningiomas; however, TSMs differ from olfactory groove meningiomas in their clinical and radiologic presentation and thus demand different surgical considerations. In particular, since TSMs originate in the subchiasmatic region, they elevate the optic chiasm and laterally displace the optic nerves as they enlarge, as opposed to olfactory groove meningiomas, which typically depress the optic apparatus posteriorly.

Furthermore, the majority of TSMs show involvement of one or both optic canals, necessitating bony decompression and tumor removal of the intracanalicular tumor components. Larger tumors may exert mass effect on the pituitary stalk, hypothalamus, and third ventricle, causing hormone dysregulation and hydrocephalus.

The TSMs can also displace the carotid arteries laterally, and occasionally densely adhere to or encase the anterior communicating artery complex and its associated perforators. Hyperostosis of the underlying bone, and their firm, rubbery texture is not uncommon. They can also grow posteriorly into the sella, or erode inferiorly into the sphenoid or ethmoid sinuses.

Diagnosis

The TSMs are traditionally found above the sella, below the chiasm, and in the midline. Growth of these lesions is quite insidious, and as such, they are often diagnosed at advanced stages of growth in patients with significant symptomatic chiasmal compression.

Compression of the optic apparatus with subsequent visual dysfunction is

a common finding in patients with these lesions. The pattern of vision loss can be unilateral, or more commonly bilateral, and often progresses over years. Most patients experience decreased visual acuity and many suffer from optic atrophy.

As opposed to pituitary adenomas, the sellae turcica is usually not expanded. Differential diagnosis for these lesions includes tumors of the olfactory groove, clinoid process, and medial sphenoid wing, such as [craniopharyngiomas](#), [metastasis](#), and optic gliomas. Unusually placed prolactinomas and other pituitary adenomas can mimic TSMs.

Evaluation

A thorough history and physical examination, as well as a visual field exam, should be performed. The visual deficit, as mentioned, may be unilateral, but is more commonly bilateral, manifested as chiasmal syndrome (bitemporal hemianopsia due to superior and posterior displacement of the optic chiasm) or an enlarged blind spot.

Patients often complain of headaches. Patients with larger tumors may present with mental status changes as a result of frontal lobe and hypothalamic dysfunction induced by tumor mass effect and edema. These mental status changes may include any combination of the following: behavioral or personality changes, loss of motivation, apathy, short-term memory loss, depression, impulsivity, and confusion.

Patients may also present with nausea/vomiting, indicative of obstructive hydrocephalus, or with signs and symptoms of pituitary hormone dysregulation, due to mass effect on the hypothalamus or pituitary stalk.

An endocrinology work-up should be considered if there is intrasellar and pituitary gland involvement. **A prolactinoma may rarely present radiographically as a TSM, and should be recognized preoperatively to prevent unnecessary operative intervention.** Please see the chapter for [Pituitary Adenoma: Diagnosis and Operative Considerations](#) for further discussion regarding diagnostic pitfalls.

Imaging studies include enhanced magnetic resonance (MR) sequences to

clearly delineate the tumor margins, relationship to the optic apparatus, and the extent of surrounding edema and vascular encasement. Growth is generally in the superior and posterior direction toward the optic apparatus, and often there is extension down the medial aspect of one or both optic canals, best identified with fat-suppression high-resolution coronal enhanced sequences. Dural tails along the posterior basal frontal dura are evident.

MR angiography more reliably assesses the tumor's relationship to the vasculature, such as with large tumors involving the anterior cerebral vessels. However, I often find T2 sequences adequate for disclosure of this relationship.

Computed tomography (CT) scan can determine the extent of hyperostosis, bony invasion and pneumatization of the anterior clinoid processes. The presence of any of these radiologic findings may necessitate planning for skull base reconstruction after resection. Digital subtraction angiography has little role in evaluation of TSMs because the tumor's blood supply is largely from the posterior ethmoidal branches of the ophthalmic arteries and pial blood vessels. Therefore, preoperative embolization risks visual impairment and is generally not attempted.

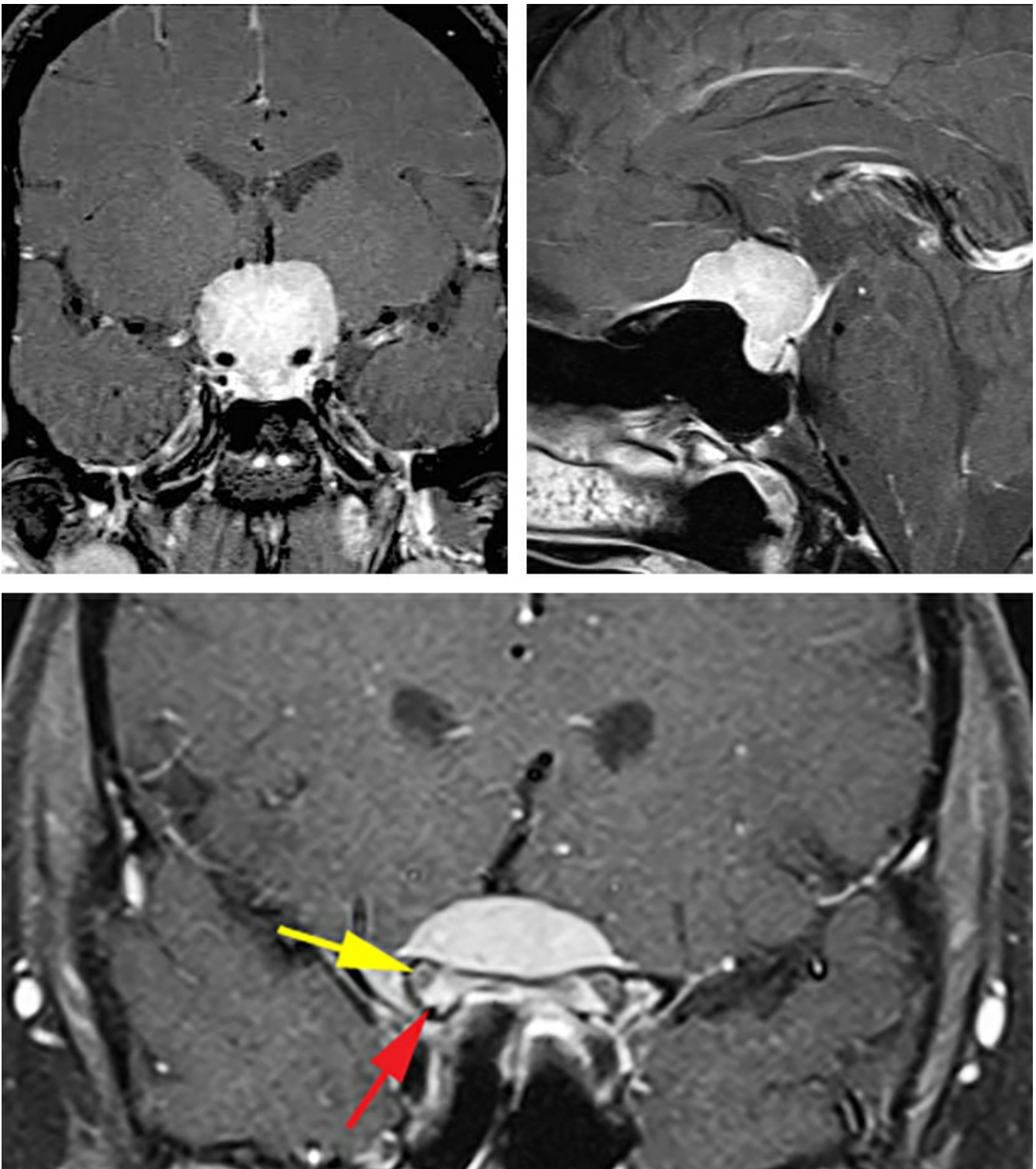


Figure 2: This classic large TSM is best suited for a transcranial approach rather than an endoscopic transnasal route due to its large size, expanse and significant encasement of the vasculature. Note the lack of sellar enlargement (left upper image) and presence of a dural tail (right upper image) as distinguishing features of the tumor. The tumor had infiltrated into bilateral optic canals with the right canal more affected than the left (lower image). The red arrow points at the intracanalicular enhancing tumor while the yellow arrow indicates the displaced optic nerve.

Indications for Surgery

Management options for TSMs include observation, microsurgical resection, and/or stereotactic radiosurgery. Microsurgical resection is typically the best treatment option for symptomatic TSMs. Diagnosis of these lesions usually occurs during an evaluation for vision impairment. The tumor's involvement with the optic apparatus at the time of diagnosis necessitates relieving the associated mass effect, and eliminates radiosurgery or observation as viable treatment options.

Small incidental TSMs without significant mass effect on the optic chiasm in patients with preserved vision may be observed with serial MRIs and visual field testing. However, stereotactic radiosurgery (SRS) is not a good option, even in patients with small lesions, due to the radiosensitivity of the adjacent optic apparatus. If imaging of symptomatic lesions reveals significant peritumoral cerebral edema, steroids are administered temporarily perioperatively.

Preoperative Considerations

During review of the preoperative imaging, particular attention should be directed to evidence of hyperostosis underlying the lesion, erosion of the ethmoid or sphenoid sinuses, or a pneumatized anterior clinoid. These factors should be considered when determining whether skull base reconstruction will be required to minimize the risk of cerebrospinal fluid (CSF) leakage.

High-resolution sequences of the MR images with fat suppression techniques identify tumor extension into the medial aspects of both optic canals. Although these special sequences are helpful, all patients should undergo careful inspection of their optic canals intraoperatively to definitively exclude compressive intraforaminal tumor fragments.

Preoperative use of seizure prophylaxis is indicated and continued for 7 days postoperatively. If the patient presented with seizures, anticonvulsants are continued for 6 months to a year. In the absence of seizure activity, the medication may be weaned off on the 7th postoperative day.

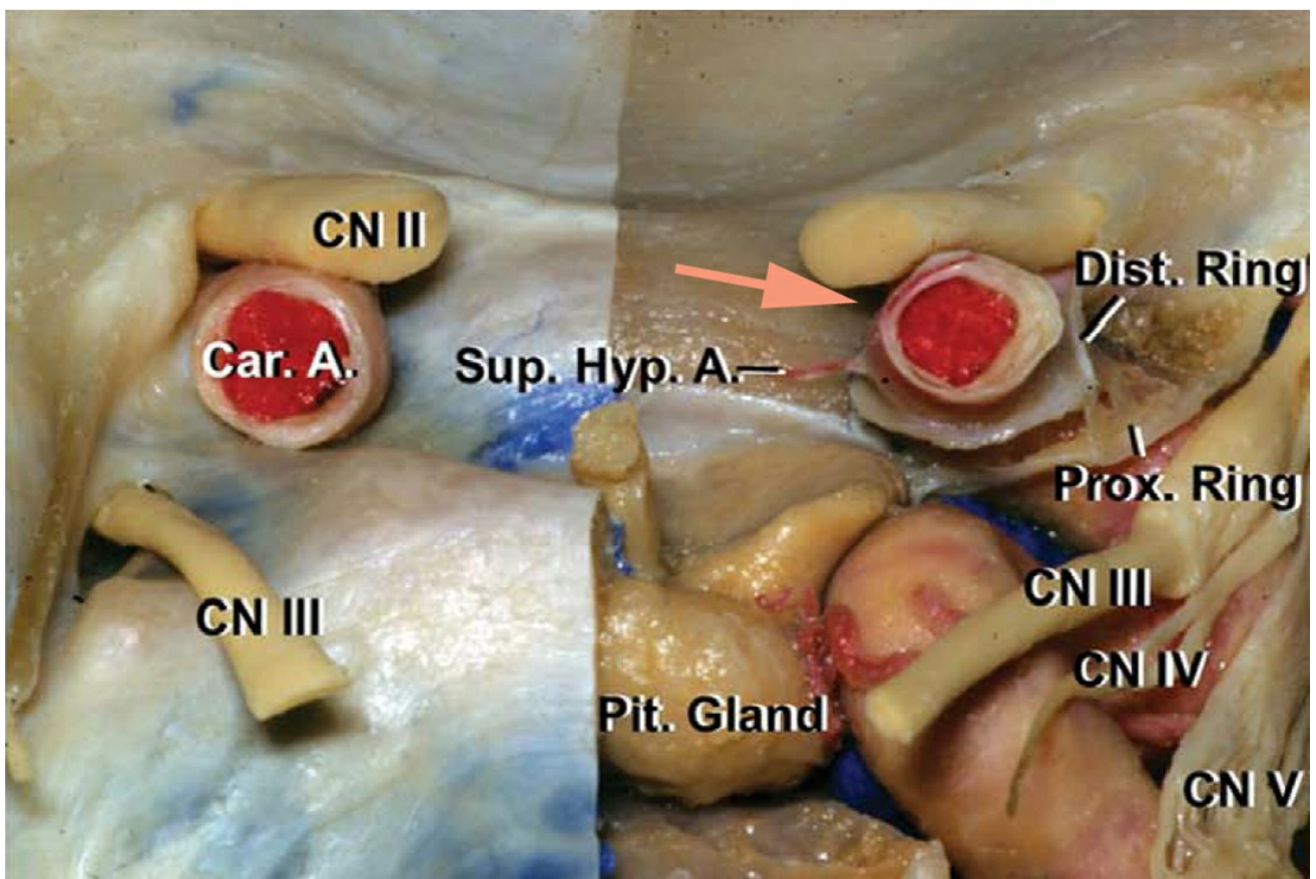
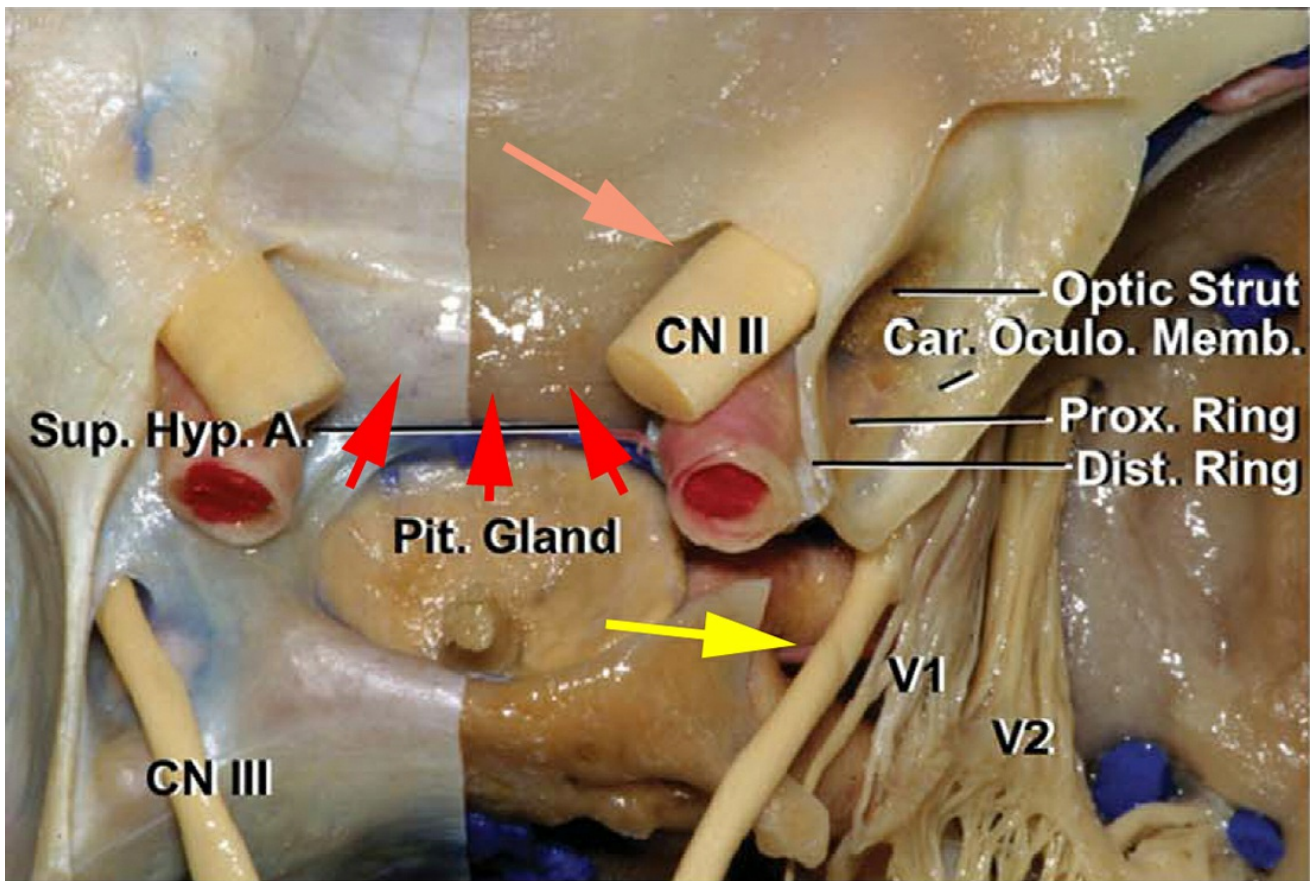
A lumbar drain is installed to provide early CSF decompression and facilitate [extradural clinoidectomy](#) before dural opening.

Operative Anatomy

The borders of the tuberculum sellae include the clinoid processes laterally, the pituitary stalk, Liliequist membrane, and infundibulum inferiorly, and the optic chiasm, lamina terminalis, and anterior cerebral arteries superiorly.

Tumors of this type generally extend anteriorly over the planum sphenoidale, laterally around the optic nerves and canal, and above the chiasm. The diaphragm sellae stretches from the tuberculum sellae to the upper border of the posterior clinoid processes, with an average length of 8 mm and width of 11 mm.

With their continued growth, these tumors involve important adjacent structures, including the carotid arteries, lamina terminalis, and the interpeduncular cisterns. Vascular supply to TSMs tends to derive from perforating branches of the posterior ethmoidal, ophthalmic, superior hypophyseal, and anterior communicating arteries (ACA).



[Click here](#) to view the interactive module and related content for this image.

Figure 3: The regional anatomy pertaining to the resection of the TSMs is

shown (upper image). The red arrows point to the typical location for the origin of TSMs. The brown arrow demonstrates the common location, medial to the nerve and within the operator's blind spot, where the tumor infiltrates the optic canal. The vicinity of the oculomotor nerve (yellow arrow) to the area of clinoidectomy is indicated. A coronal view of the tuberculum sella and its anatomic relationships to the surrounding cerebrovascular structures are also demonstrated (lower image)(images courtesy of AL Rhoton, Jr). The small perforating vessels arising from the medial wall of the carotid artery supply the chiasm; their sacrifice can lead to postoperative visual deterioration or loss.

RESECTION OF A TUBERCULUM SELLA MENINGIOMA THROUGH THE TRANSCRANIAL ROUTE

For small to medium sized TSMs (less than 3cm), I prefer the endoscopic transnasal route. However, for larger and multicompartmental lesions, I advocate the [extended pterional approach](#). The bifrontal approach is unnecessary and avoidable.

Extension of the tumor lateral to the optic nerves indicates the need for a transcranial reach to effectively remove the tumor. Significant growth lateral to the carotid arteries and their encasement is another reason to consider the subfrontal corridor.

The advantages of a unilateral frontotemporal craniotomy over a bifrontal route include identification of the optic nerve and carotid artery early in surgery and avoidance of frontal air sinuses and bilateral frontal lobe retraction. In addition, this corridor preserves the sagittal sinus and is familiar to neurosurgeons.

Other surgical approaches have been advocated for resection of TSMs, including the orbitozygomatic, lateral subfrontal, and supraorbital keyhole corridors. Since I usually use the transcranial route for large lesions, I use the pterional corridor. However, the supraorbital craniotomy via an eyebrow incision is reasonable for small to medium size lesions that I prefer to reach through the endoscopic transnasal pathway.

I approach this primarily midline tumor from the side of the more affected optic nerve. **The ipsilateral nerve is more prone to surgical manipulation. The contralateral nerve is readily decompressed via removal of the intracanalicular portion of the tumor that primarily enters the optic foramen along the potential space within the medial aspect of the nerve.** Nonfunctioning nerves are not sacrificed because some recovery of vision, even after complete blindness, has been reported.

Transnasal versus Transcranial Approach

Most TSMs grow within the medial aspect of the optic canals, making an endonasal endoscopic resection more desirable than the lateral operative trajectory afforded through the transcranial routes. The use of angled endoscopes improves adequate visualization around the corners along the lateral infrachiasmatic space, and vascularized nasoseptal flaps facilitate reconstruction of large cranial base defects. *Occasionally the tumor extends lateral to the optic nerve, an area inaccessible to the endonasal approach.* Tumors in this location are candidates for pterional and supraorbital eyebrow keyhole approaches.

The location of the chiasm in relation to the tumor is another consideration, with a superiorly displaced prefixed chiasm allowing more flexible operative working angles through the endonasal rather than transcranial approach. Lastly, significant vascular involvement of the internal carotid and anterior cerebral arteries has traditionally contraindicated the application of the endonasal approach. For giant tumors with significant superior extension, an orbitozygomatic craniotomy can be advantageous

I prefer the [endoscopic transnasal route](#) for resection of most TSMs. Size (up to 3 cm), mild to moderate vascular encasement, and pial invasion (as evidenced by intracerebral edema) are not considered strong contraindications for using an endoscopic approach based on the **experience of the surgeon.** Microsurgical techniques are readily possible through this route to dissect the engulfed arteries.

Simpson grade 1 resection is possible through the transnasal route for

smaller lesions as the affected bone is removed during the transnasal exposure, whereas this grade of resection is difficult to achieve through the transcranial route. Retraction of the optic apparatus and brain parenchyma is avoided and the optic canals are generously decompressed along their medial aspects via the endoscopic endonasal approach. The risk of CSF leak remains approximately 10% using this approach. In summary, an infrachiasmatic tumor demands an infrachiasmatic operative route to prevent retraction injury to the optic apparatus.

However, for large lesions (>3-4 cm), I prefer to use the pterional craniotomy. During the past decade, I have not used the bilateral subfrontal approach for any primary intradural tumors and have reserved this extensive craniotomy for extradural tumors involving the anterior skull base and extending into the nasal cavity (such as esthesioblastomas and chondrosarcomas).

When using the pterional approach, I osteotomize the lateral sphenoid wing and perform an extradural anterior clinoidectomy to thoroughly decompress the ipsilateral optic nerve early in dissection in order to facilitate its mobilization during the intradural portion of the operation.

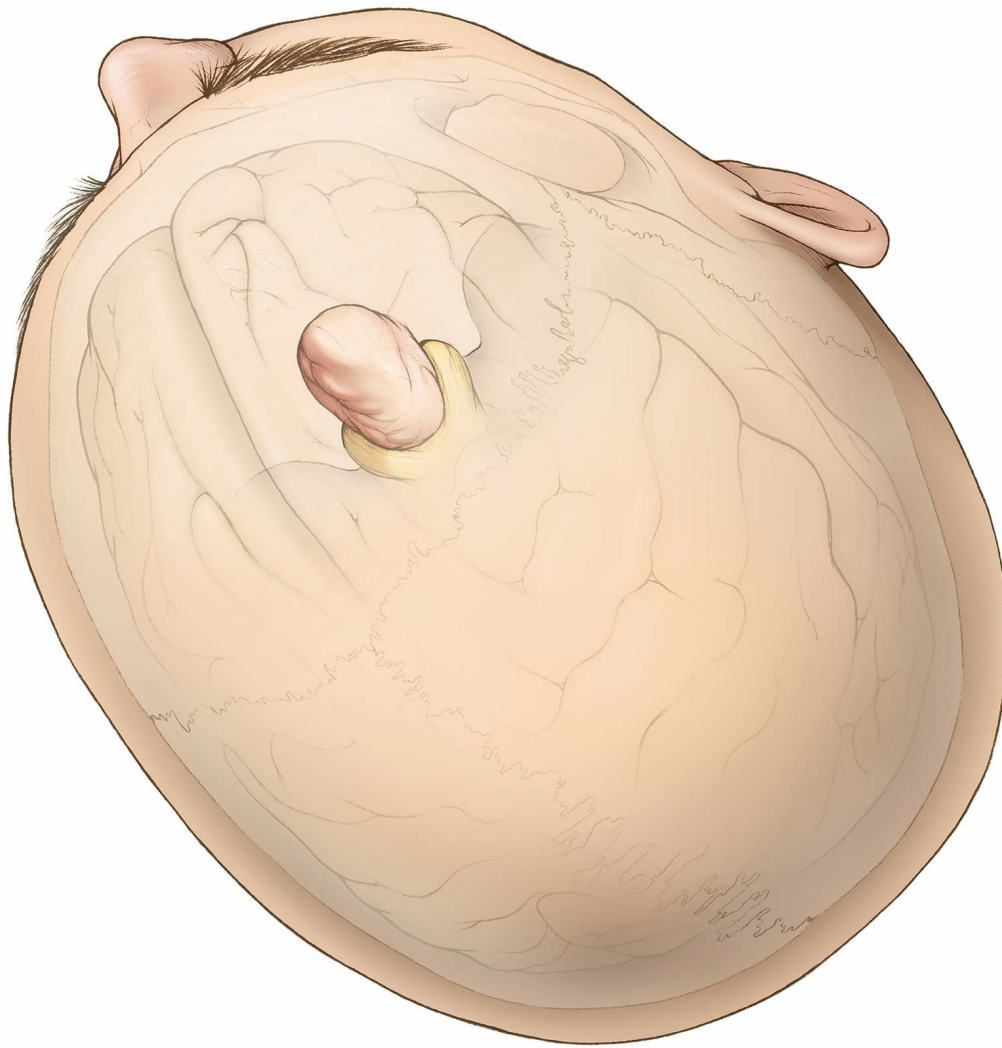


Figure 4: A roadmap to the tumor in relation to the external and internal landmarks is illustrated. The lateral pterional trajectory provides an early access to the vital cerebrovascular structures along the posterior aspect of the tumor.

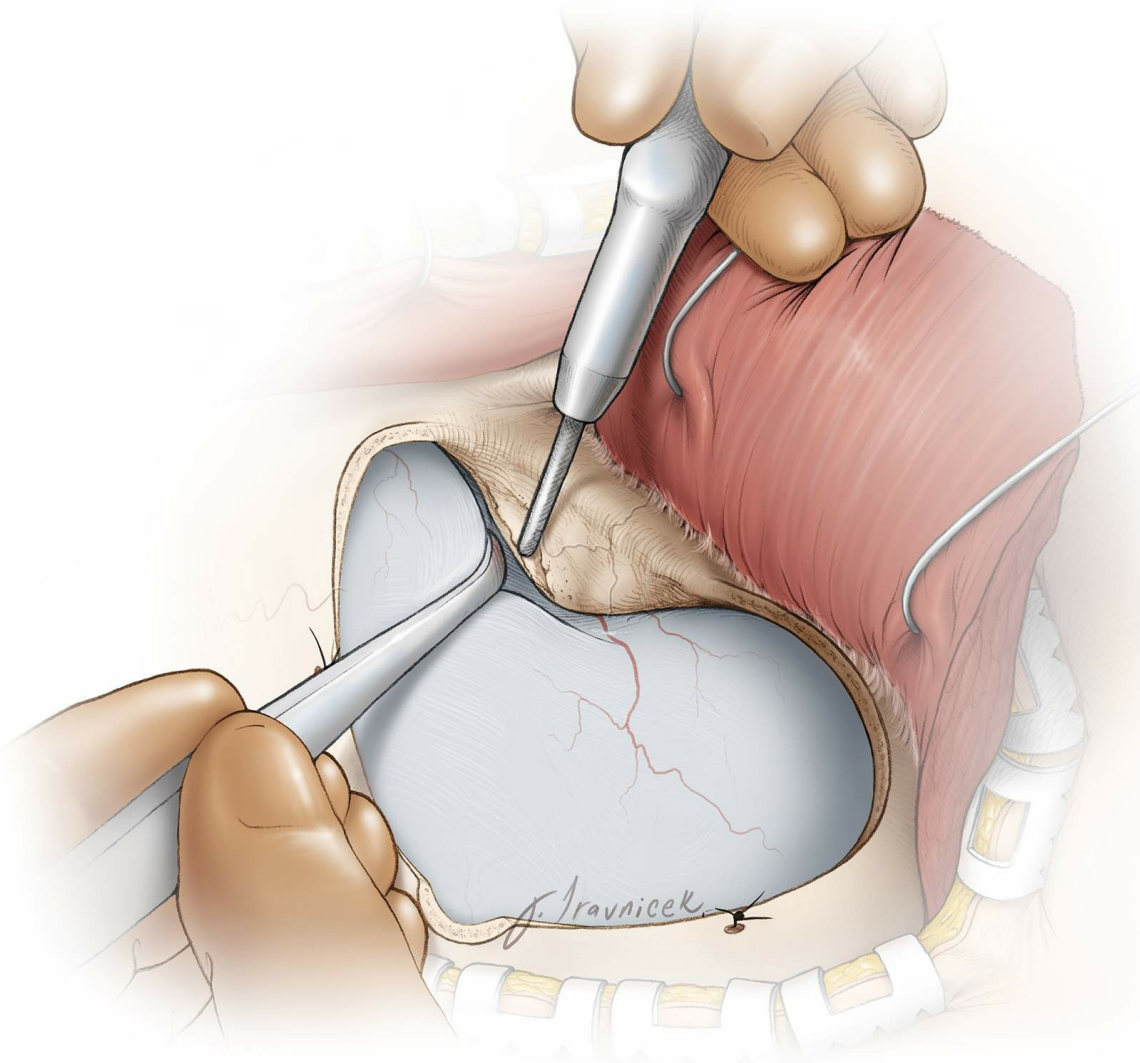


Figure 5: The lateral sphenoid ridge is initially removed using a rongeur, and the roof of the orbit is then flattened. The edge of the craniotomy along the supraorbital region is drilled flat and parallel to the roof of the orbit; this maneuver provides an unobstructed view to the parasellar area through the subfrontal corridor. An [extradural clinoidectomy](#) is then completed.

INTRADURAL PROCEDURE

After extradural decompression of the ipsilateral optic nerve via clinoidectomy, the dura is incised.

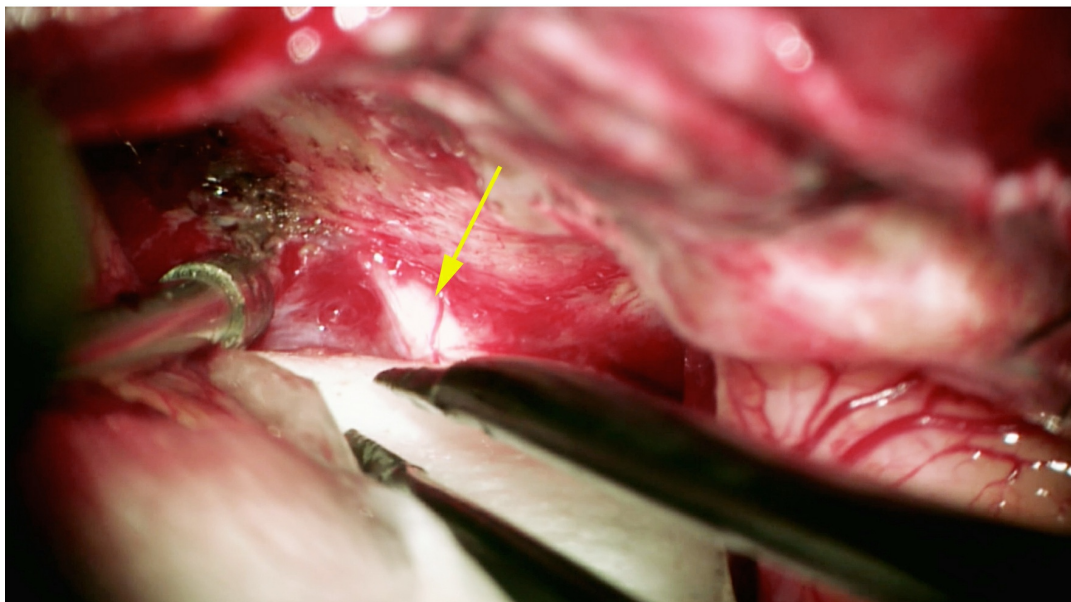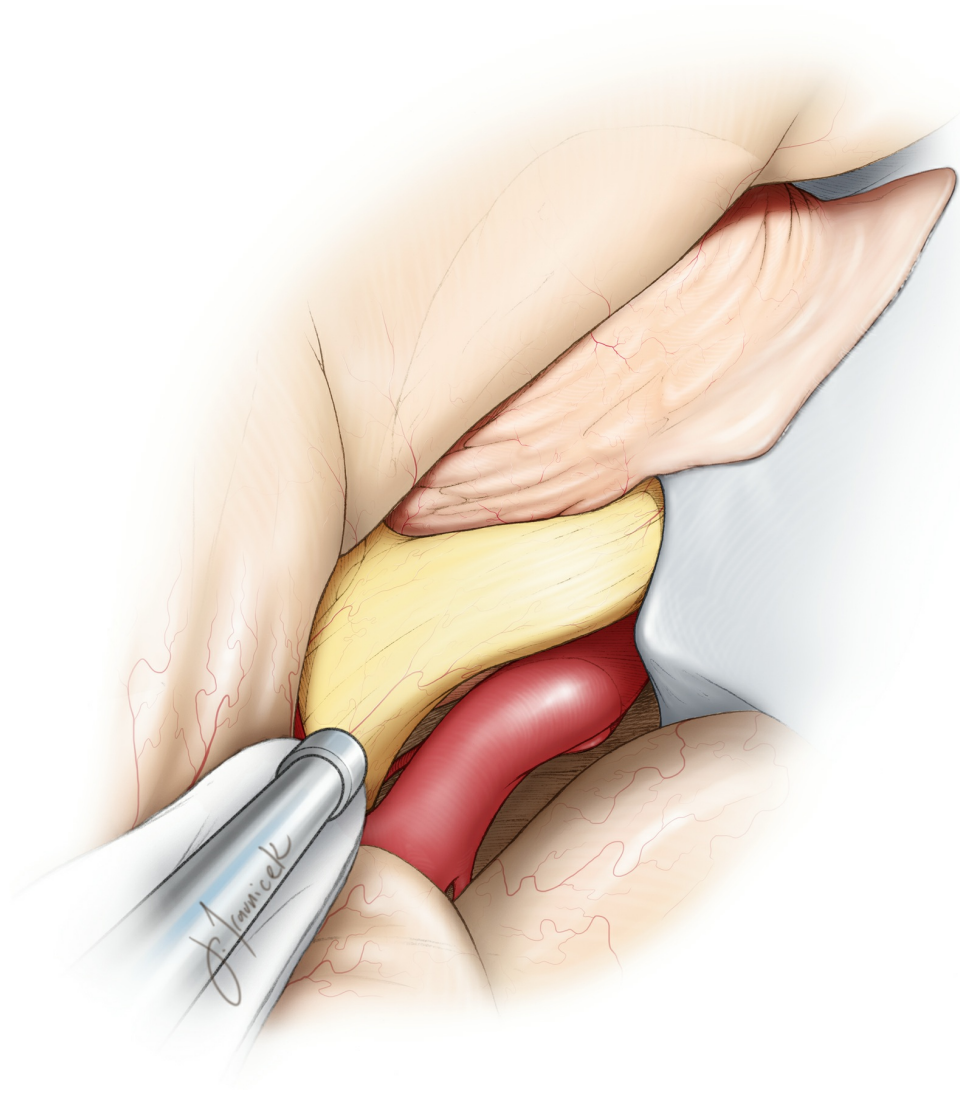


Figure 6: The Sylvian fissure is dissected open along its anterior limb. In this illustration, a right subfrontal exposure demonstrates the tumor in relation to the right optic nerve (arrow), chiasm, and internal carotid artery. Early identification of these neurovascular structures keeps them out of harm's way. Wide dissection of the regional arachnoid membranes

and release of CSF from the opticocarotid cisterns will promote brain relaxation and obviate the need for rigid retractors.

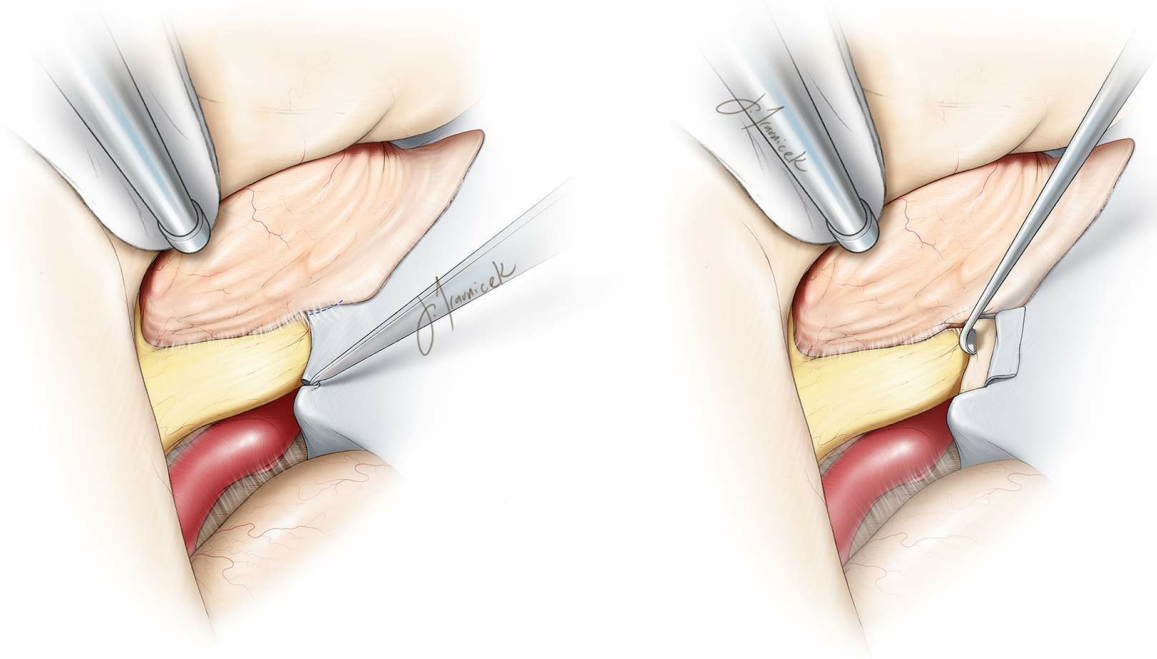


Figure 7: Since an extradural clinoidectomy was completed during the earlier stages of the operation, the falciform ligament can be readily cut (left), leading to generous decompression of the ipsilateral optic nerve. Alternatively, an [intradural clinoidectomy/osteotomy](#) will allow unroofing of the nerve (right). Diamond burrs and angled currettes are used through copious irrigation to prevent thermal injury to the optic nerve. Aggressive bipolar coagulation of the tumor around the nerve is avoided.

It is beneficial to approach resection of meningiomas using the following algorithm (4Ds of meningiomas): 1)Dedress the tumor, 2)Devascularize the base of the tumor, 3)Debulk the tumor, and finally, 4)Dissect the tumor along its preserved arachnoid planes.

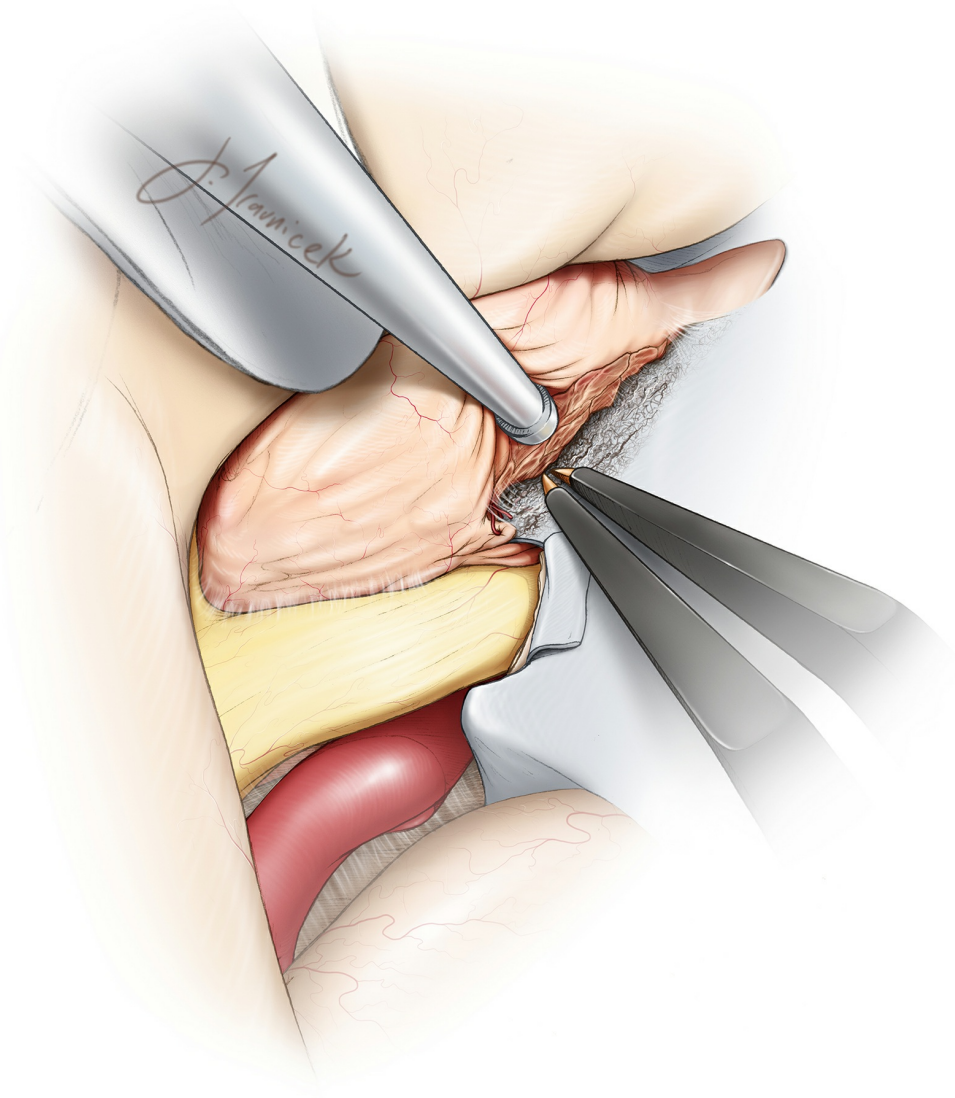


Figure 8: Next, the tumor is devascularized along its base centered over the tuberculum sellae and extending over the planum sphenoidale. **Dissection should stay along the paramidline to prevent inadvertent injury to the contralateral optic nerve that is within the surgeon's blind spot behind the tumor.** Note the extension of the tumor into the ipsilateral medial optic foramen. This devascularization extends posteriorly into the sella.

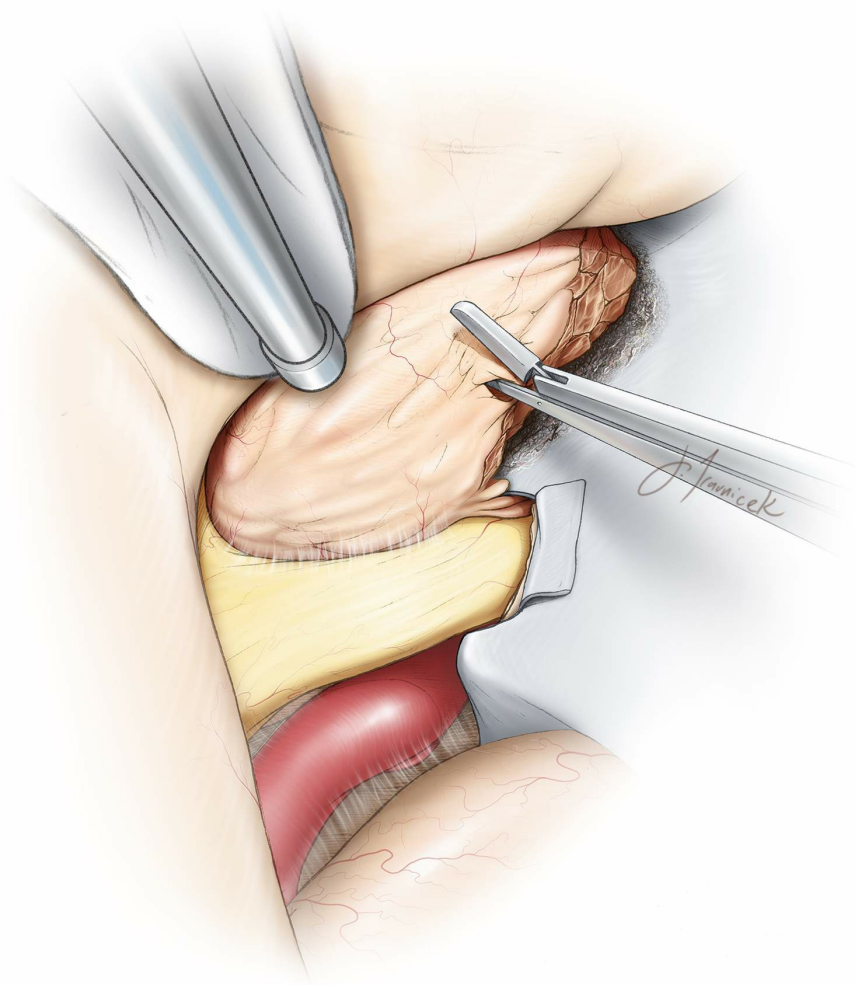


Figure 9: Next, the tumor is debulked using an ultrasonic aspirator or pituitary rongeurs. All manipulations are executed within the tumor capsule and along the paramidline skull base to prevent injury to the vital extracapsular structures including the perforators of the internal carotid arteries or ACA branches.

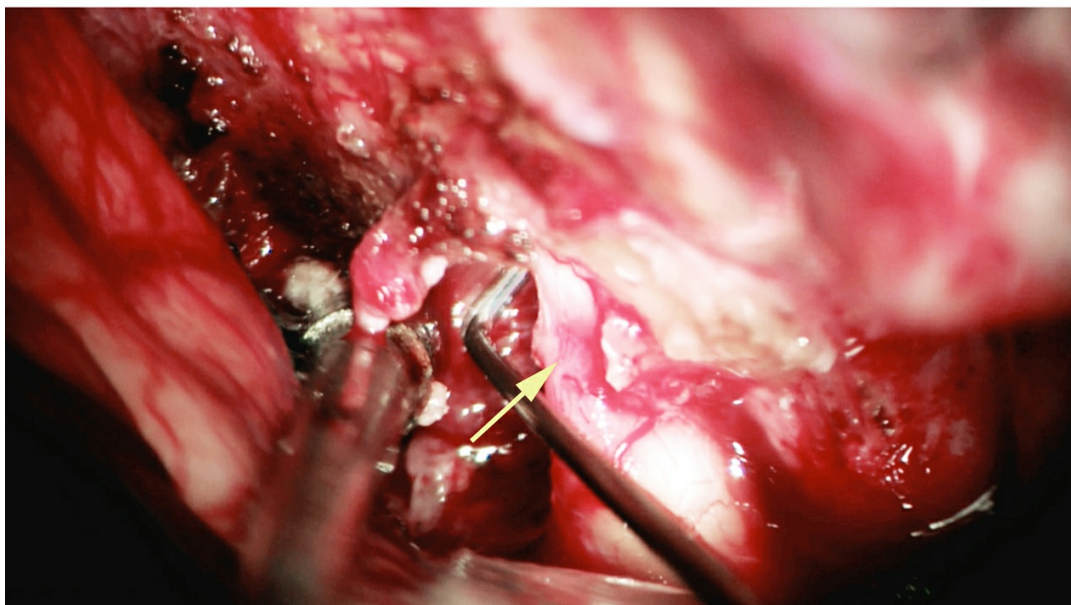
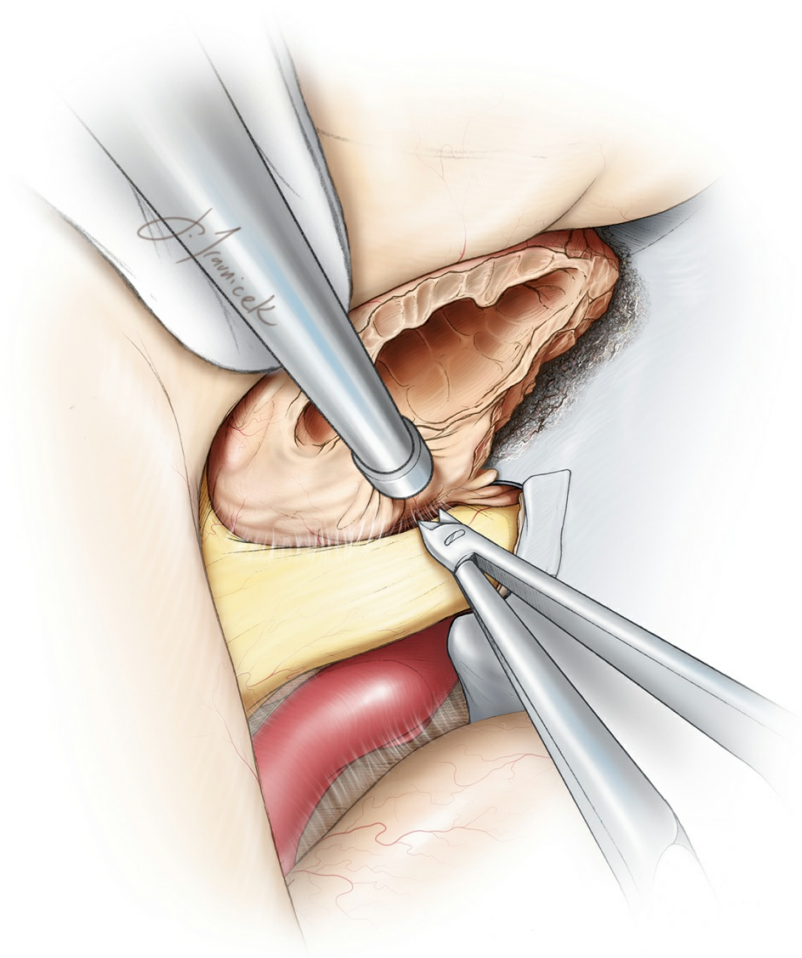


Figure 10: After aggressively debulking the tumor, I use sharp microsurgical techniques to dissect the arachnoid planes between the tumor capsule and ipsilateral optic nerve and chiasm. The tumor can flatten and attach to the nerve, complicating creation of a safe dissection plane between the nerve and the tumor. In this circumstance, the surgeon should patiently dissect and gently mobilize the tumor away

from the nerve. If dissection planes cannot be safely developed, a thin sheet of tumor is left on the nerve and the optic foramen is unroofed. The site of nerve compression after opening of the falciform ligament is demonstrated (lower photo, arrow).

The anterior cerebral and internal carotid arteries are usually not densely adherent to the tumor and are readily dissected away. **Care is taken to preserve the small branching vessels originating from the medial aspect of the internal carotid artery supplying the optic nerves and chiasm. These small perforating vessels also arise from the superior hypophyseal artery complex.**

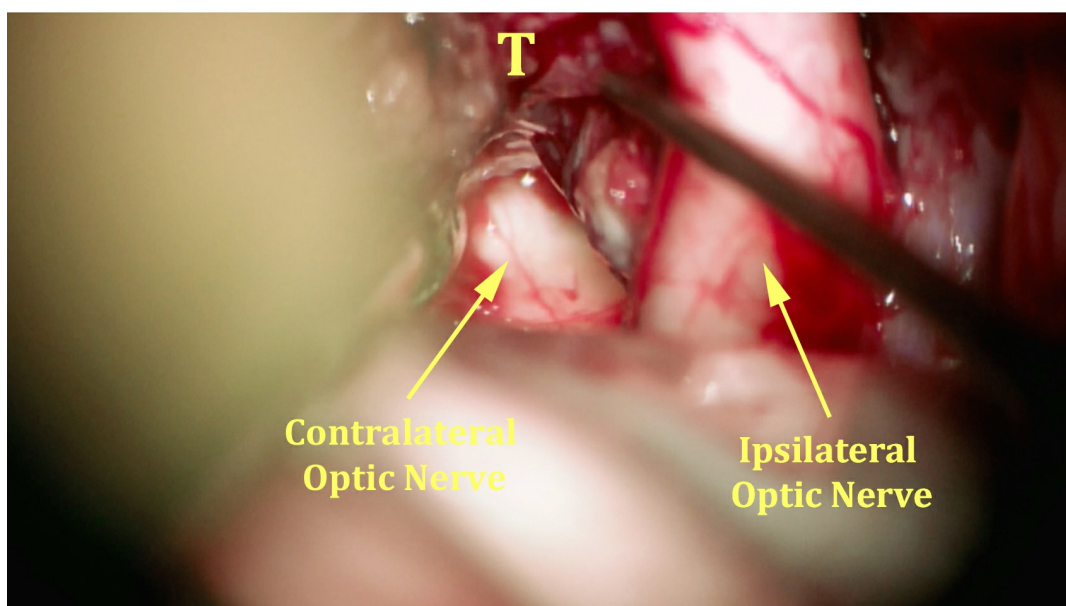
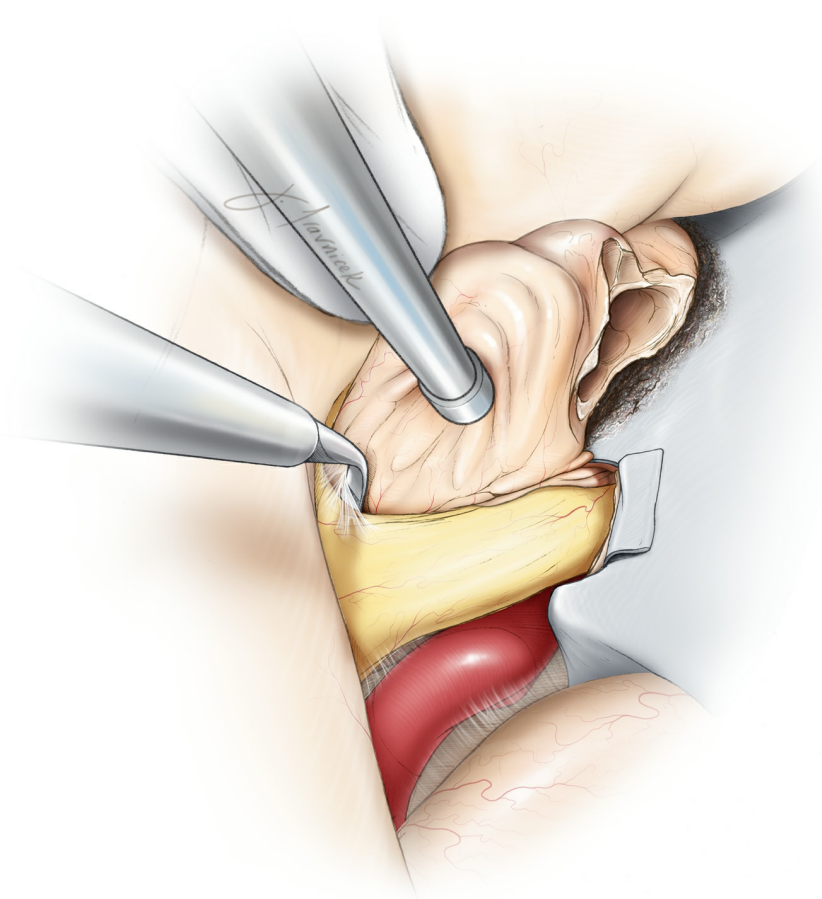


Figure 11: Continuing sharp arachnoid dissection while preserving all pial planes, I carefully extract the tumor away from the ipsilateral optic nerve and chiasm from the anterior to posterior direction (top illustration). **This critical step leads to the exposure of the contralateral chiasm and posterior aspect of the contralateral optic nerve (bottom photo, T:Tumor).** Aggressive manipulation of the chiasm invariably leads to worsening of vision. The tumor should be mobilized away from the

chiasm, not vice versa. Anterior cerebral arteries are also released from the superior pole of the tumor capsule at this step of the operation. Extra-pial capsular dissection will detach the tumor from the base of the frontal lobe.

The interoptic and the optico-carotid cisterns are employed as operative corridors to dissect and mobilize the tumor capsule. When working in the optico-carotid space, I retract the carotid artery intermittently using the hand held suction device rather than retracting the optic apparatus. The pituitary stalk is readily dissected from the posterior aspect of the tumor. Its careful preservation is pertinent for preventing postoperative pituitary gland dysfunction. The portion of the tumor invading the sella can be gently pulled into the resection cavity.

I usually avoid going across the anterior pole of the tumor to find the contralateral optic nerve at its foramen as this maneuver can be hazardous during tumor bleeding, potentially necessitating blind dissection.

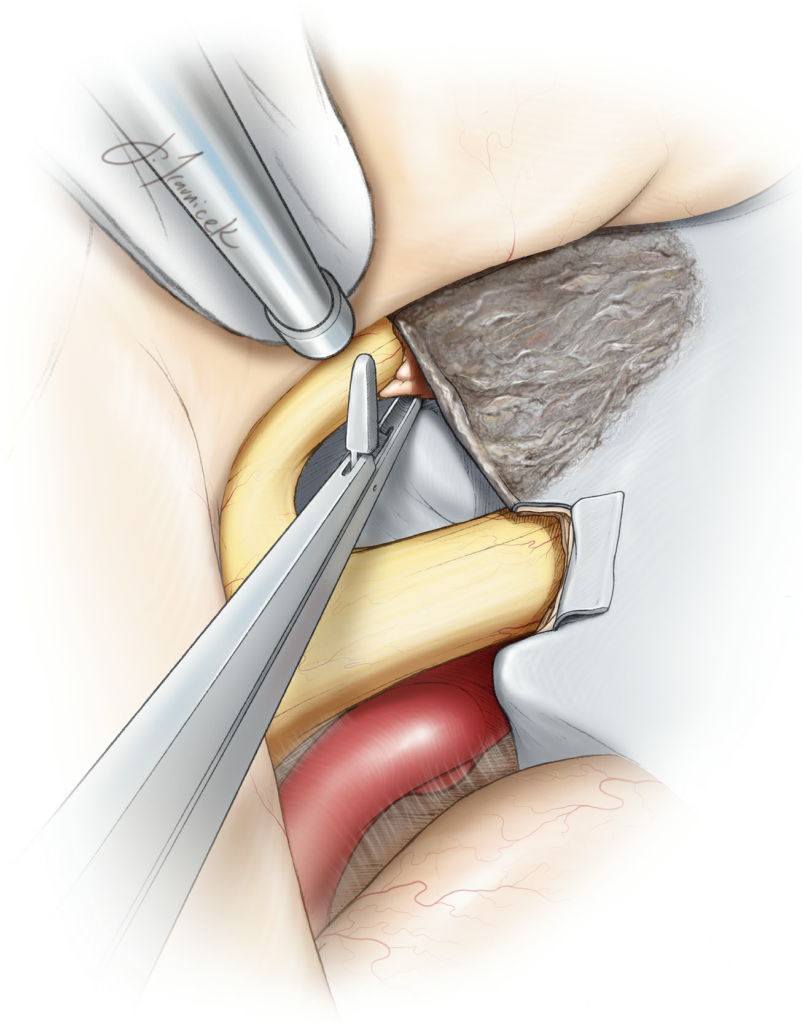
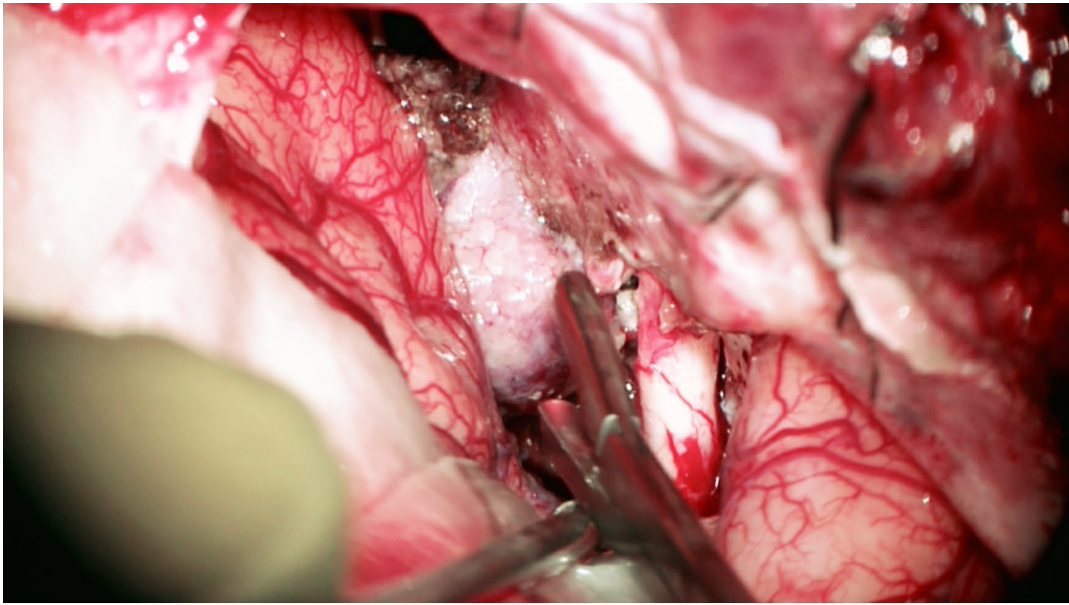


Figure 12: The bulk of the tumor is removed (upper photo). It is necessary to inspect both optic canals for presence of any residual or overlooked tumor. The medial aspect of the canal is most easily inspected along the contralateral optic nerve by using a cross-court approach (bottom illustration). Inadequate removal of the tumor may potentially account

for delayed visual deterioration due to swelling of the residual tumor within the canal. The intracanalicular components of the tumor are typically nonadherent and can be dislodged using fine pituitary rongeurs.

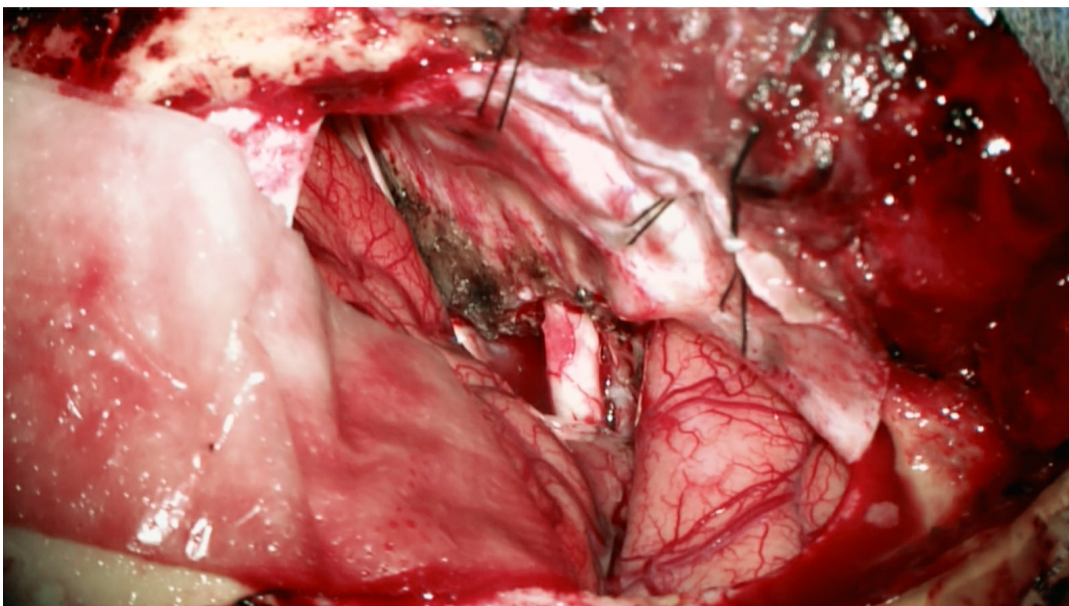
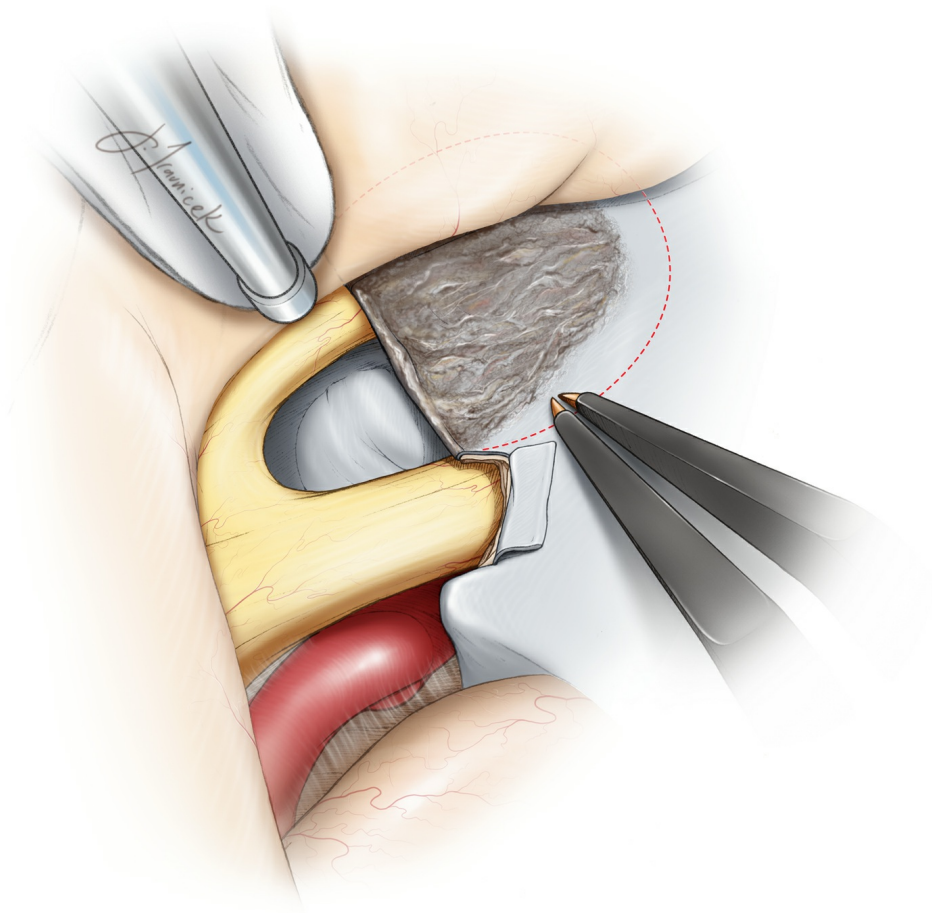
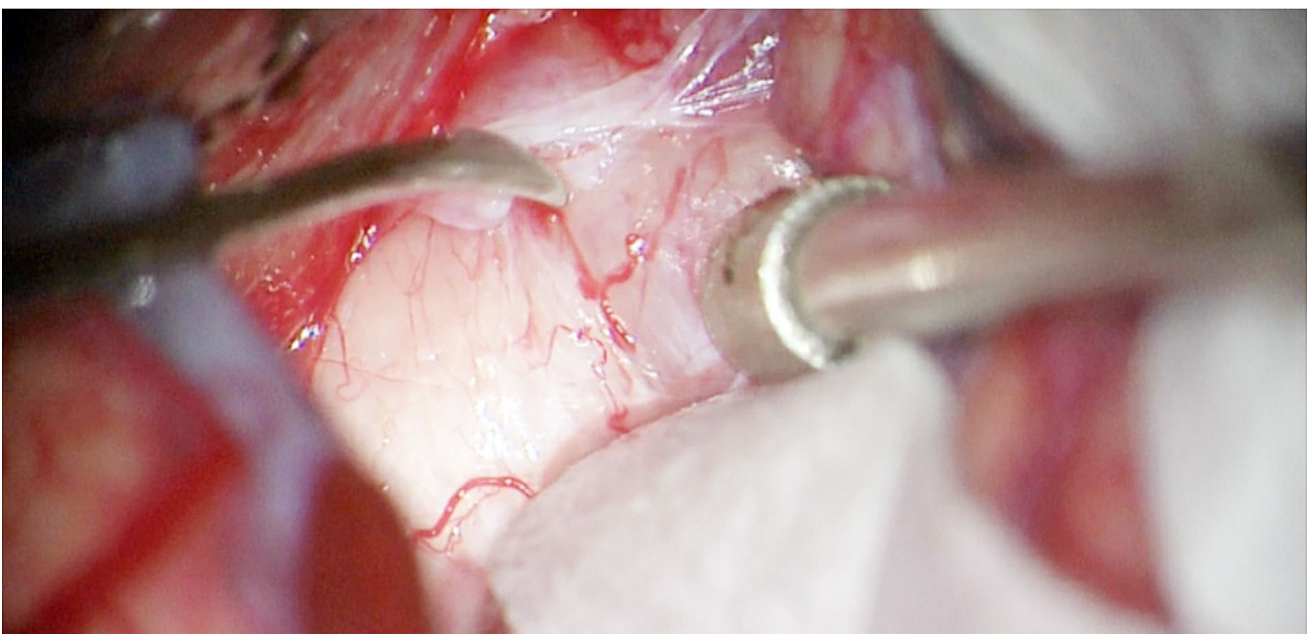
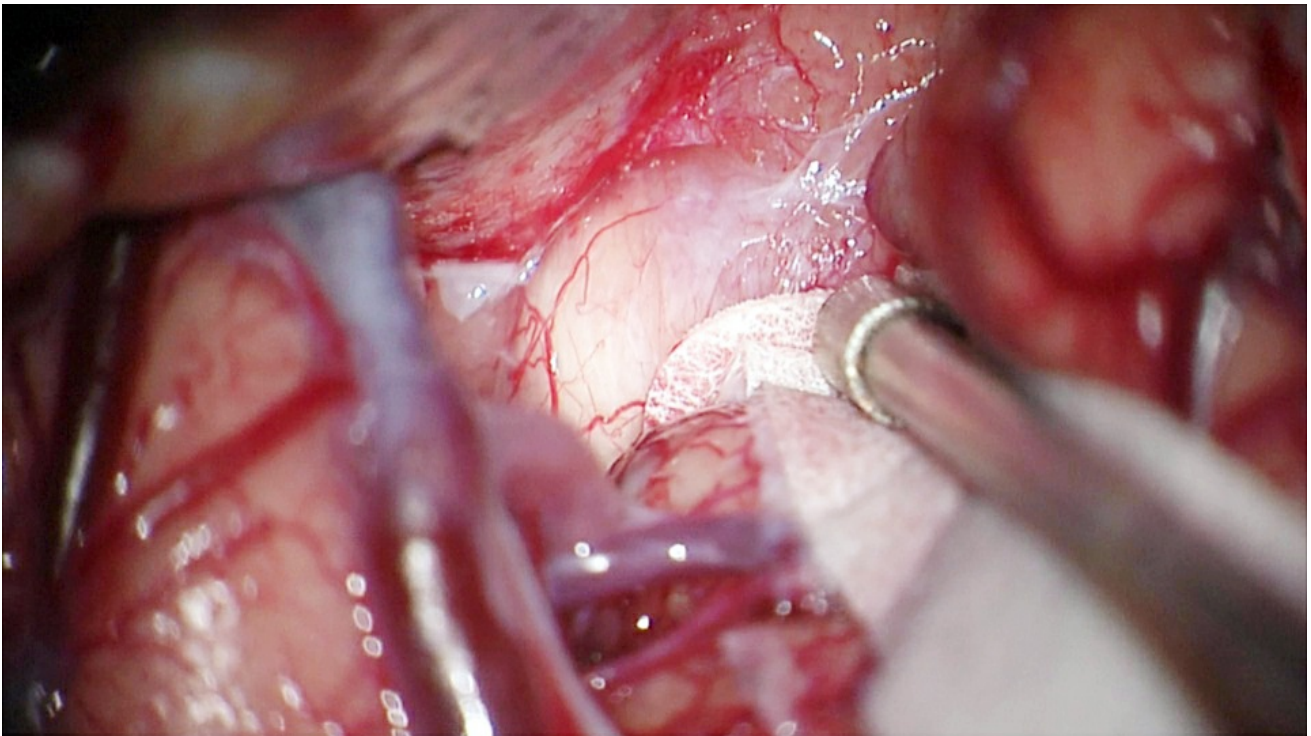


Figure 13: The infiltrated dura along the anterior skull base is cauterized using bipolar electrocautery. If the underlying bone is involved, it is resected using a diamond burr. CT-guided neuronavigation can determine the extent of bony drilling. If the ethmoid air sinuses are

encountered, their mucosa is exenterated and filled with a large piece of fat graft. A generous piece of pericranium is placed to cover the defect. I usually avoid entry into the air sinuses as reconstruction of the anterior skull base in the region of the tuberculum sella via the transcranial approach can be challenging.

Additional Considerations

The optic nerve can be quite attenuated and bowed by the tumor, making the surgeon believe a safe plane of dissection between the two is unattainable. The extent of safe persistence needed to dissect the two away from each other depends on the experience of the surgeon.



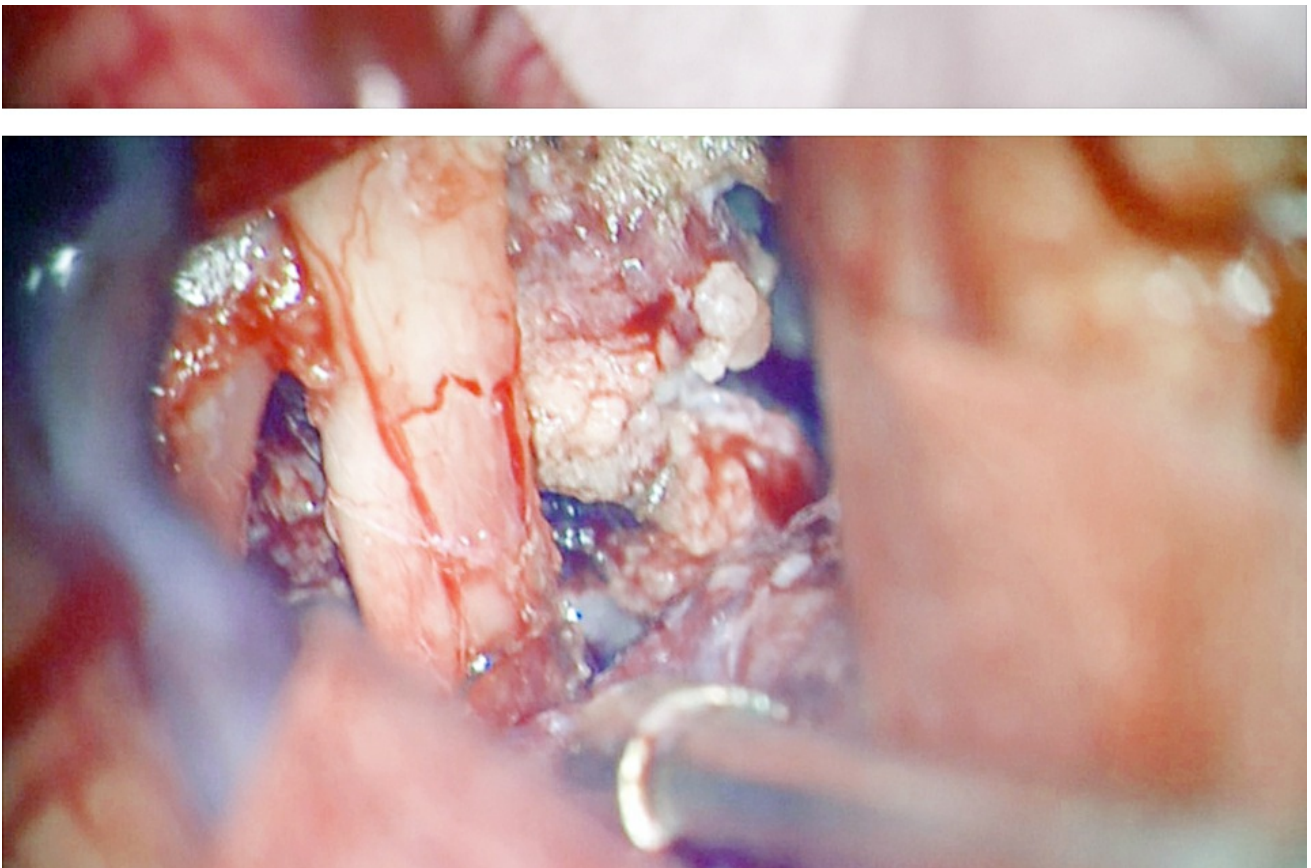


Figure 14: This large TSM was exposed through a left-sided pterional craniotomy. Upon initial inspection, the optic nerve, I found the nerve very adherent to the tumor (top image). Further dissection of the overlying arachnoid membranes revealed a more distinguishable plane between the tumor and the nerve (middle photo). Tumor decompression followed by sharp dissection allowed safe mobilization of the tumor away from the nerve (bottom photo).

Postoperative Considerations

A follow-up MRI is obtained within 48 hours of surgery. Visual field and pituitary hormonal axis evaluation is conducted approximately 6 weeks after surgery.

Immediate postoperative visual deterioration is related to optic apparatus retraction and/or devascularization. Patients who suffer blindness after surgery are unlikely to improve long-term. Delayed postoperative deterioration is potentially related to the swelling of the residual tumor within the canal or vasospasm of regional perforators. Therefore, if manipulation of perforators is noted intraoperatively, I irrigate the resection cavity with papaverine or verapamil solution before closure.

Pearls and Pitfalls

- Most TSMs present in a smaller size than their counterpart cribriform plate meningiomas and can be resected through endoscopic endonasal surgery.
- Preservation of perforating feeders to the chiasm is critical for success. Aggressive manipulation of the optic apparatus should be avoided at all costs.
- The intraforaminal portion of the tumor typically resides medial to the optic nerve and should be removed for optimal outcomes.

DOI: <https://doi.org/10.18791/nsatlas.v5.ch05.2>

Contributor: Andrew R. Conger, MD, MS

REFERENCES

Al-Mefty O. *Operative Atlas of Meningiomas*. Philadelphia: Lippincott-Raven, 1998.

Al-Mefty O. Tuberculum sellae and olfactory groove meningiomas, in Sekhar LN, Janecka IP (eds): *Surgery of Cranial Base Tumors*. New York: Raven Press, 1993, 507-520.

Bowers C, Altay T, Couldwell W. Surgical decision-making strategies in tuberculum sellae meningioma resection. *Neurosurgical Focus*. 2011;30:E1.

McDermott MW, Parsa AT. Surgical management of olfactory groove meningiomas, in Badie B (ed): *Neurosurgical Operative Atlas: Neuro-Oncology*, 2nd Ed. Rolling Meadows, IL: Thieme Medical Publishers and the American Association of Neurological Surgeons, 2006, 161-169.

Nanda A, Ambekar S, Javalkar V, Sharma M. Technical nuances in the management of tuberculum sellae and diaphragma sellae meningiomas. *Neurosurgical Focus*. 2013;35:E7.

Sughrue M, Sanai N, McDermott M. Tuberculum sellae meningiomas, in DeMonte F, McDermott M, Al-Mefty O (eds): *Al-Mefty's Meningiomas*. 2nd ed. New York: Thieme Medical Publishers, 2011, 196-205.

Tew JM, van Loveren HR, Keller JT. *Atlas of Operative Microneurosurgery*. Philadelphia: Saunders, 1994-2001.

Related Materials

Unavailable Through the Atlas



Microsurgical Anatomy of the Carotid Cave