



Cerebellopontine Angle and Cranial Nerves

Last Updated: April 8, 2021

Introduction

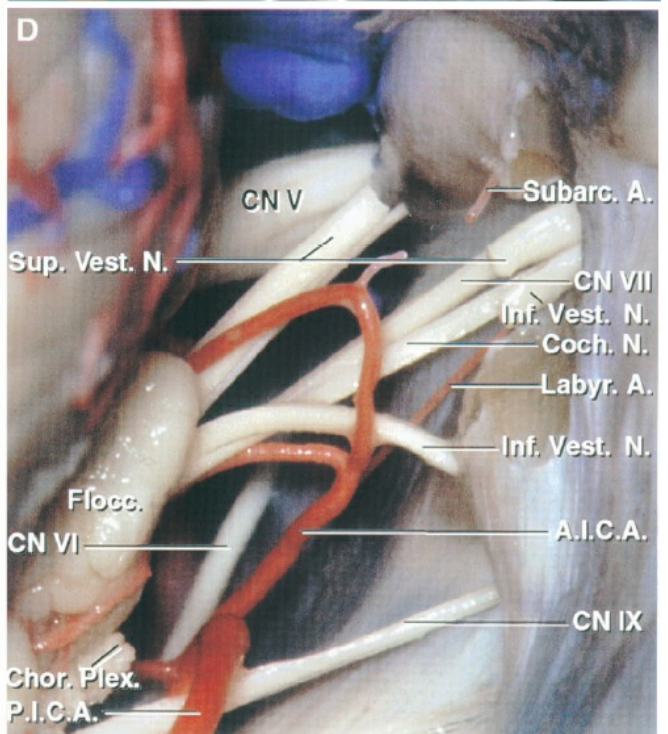
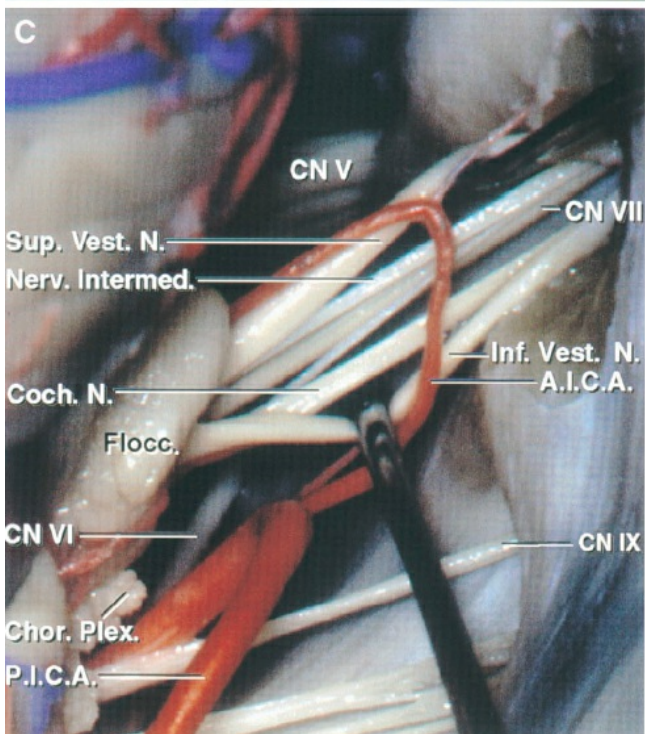
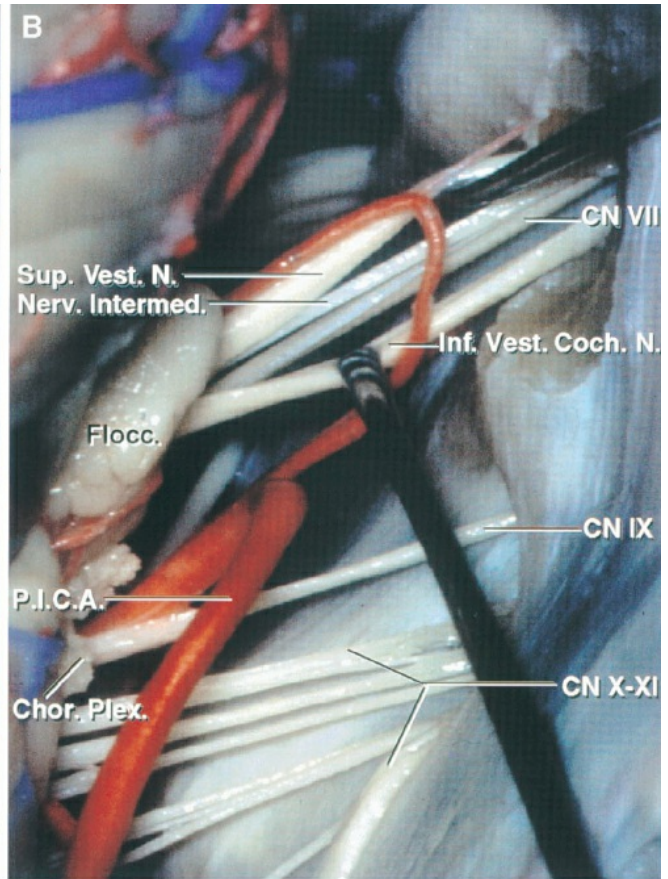
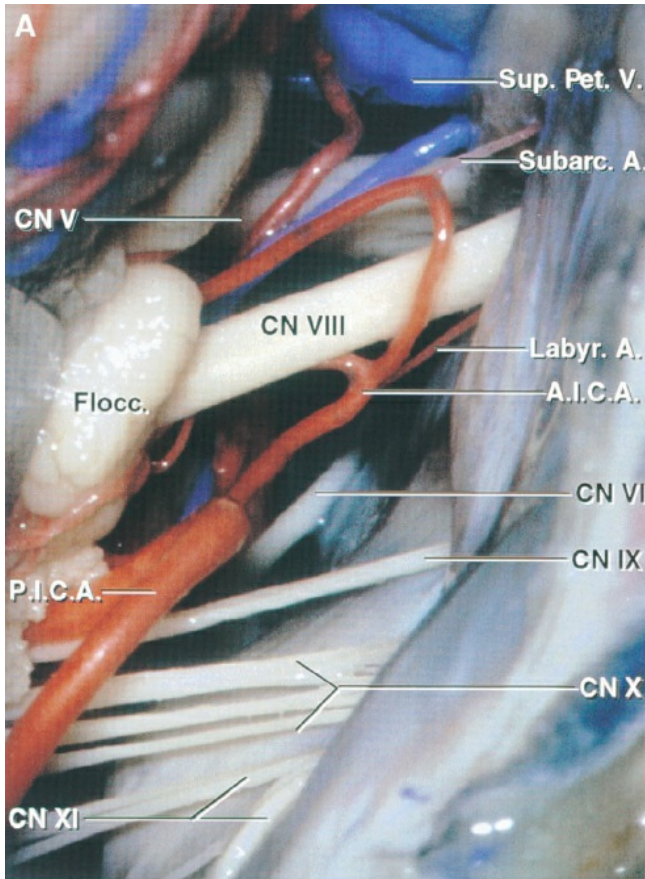
The cerebellopontine angle is located between the superior and inferior limbs of the angular cerebellopontine fissure formed by the petrosal cerebellar surface folding around the pons and middle cerebellar peduncle (Fig. 4.1). The cerebellopontine fissure opens medially and has superior and inferior limbs that meet at a lateral apex. The fourth through the eleventh cranial nerves are located near or within the angular space between the two limbs commonly referred to as the cerebellopontine angle (Fig. 4.1). The trochlear and trigeminal nerves are located near the fissure's superior limb and the glossopharyngeal, vagus, and accessory nerves are located near the inferior limb. The abducens nerve is located near the base of the fissure, along a line connecting the anterior ends of the superior and inferior limbs.

This description of the cranial nerves and operative approaches to the cerebellopontine angle is organized around the three neurovascular complexes, defined in the chapter on the cerebellar arteries, and focuses on the retrosigmoid approach, which is the most frequently selected approach for lesions in the angle. The microsurgical anatomy of acoustic neuromas, vascular compression syndromes, and other disorders involving the nerves in the cerebellopontine angle are the subjects of this section.

Upper Neurovascular Complex

The most common operation directed to the upper neurovascular complex is the exposure of the posterior root of the trigeminal nerve. The posterior trigeminal root joins the brainstem about halfway between the lower and upper borders of the pons (Fig. 4.2). Frequently, a lip of cerebellum projects forward and obscures the junction of the posterior root with the

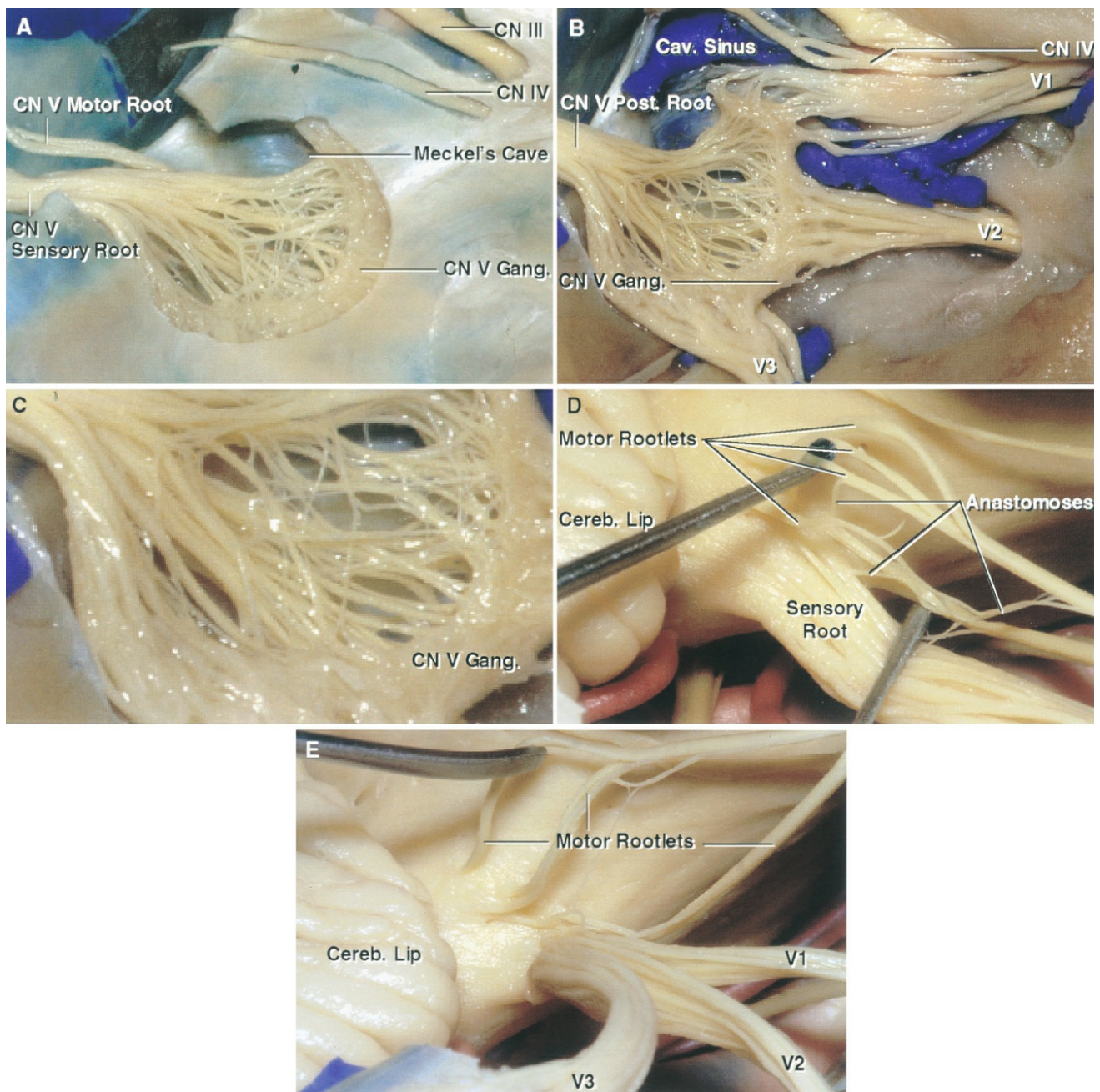
pons. In its intradural course, the trigeminal nerve uniformly runs obliquely upward from the lateral part of the pons toward the petrous apex. It exits the posterior fossa to enter the middle cranial fossa by passing forward beneath the tentorial attachment to enter Meckel's cave, which sits in the trigeminal impression on the upper surface of the petrous part of the temporal bone.





[Click here](#) to view the interactive module and related content for this image.

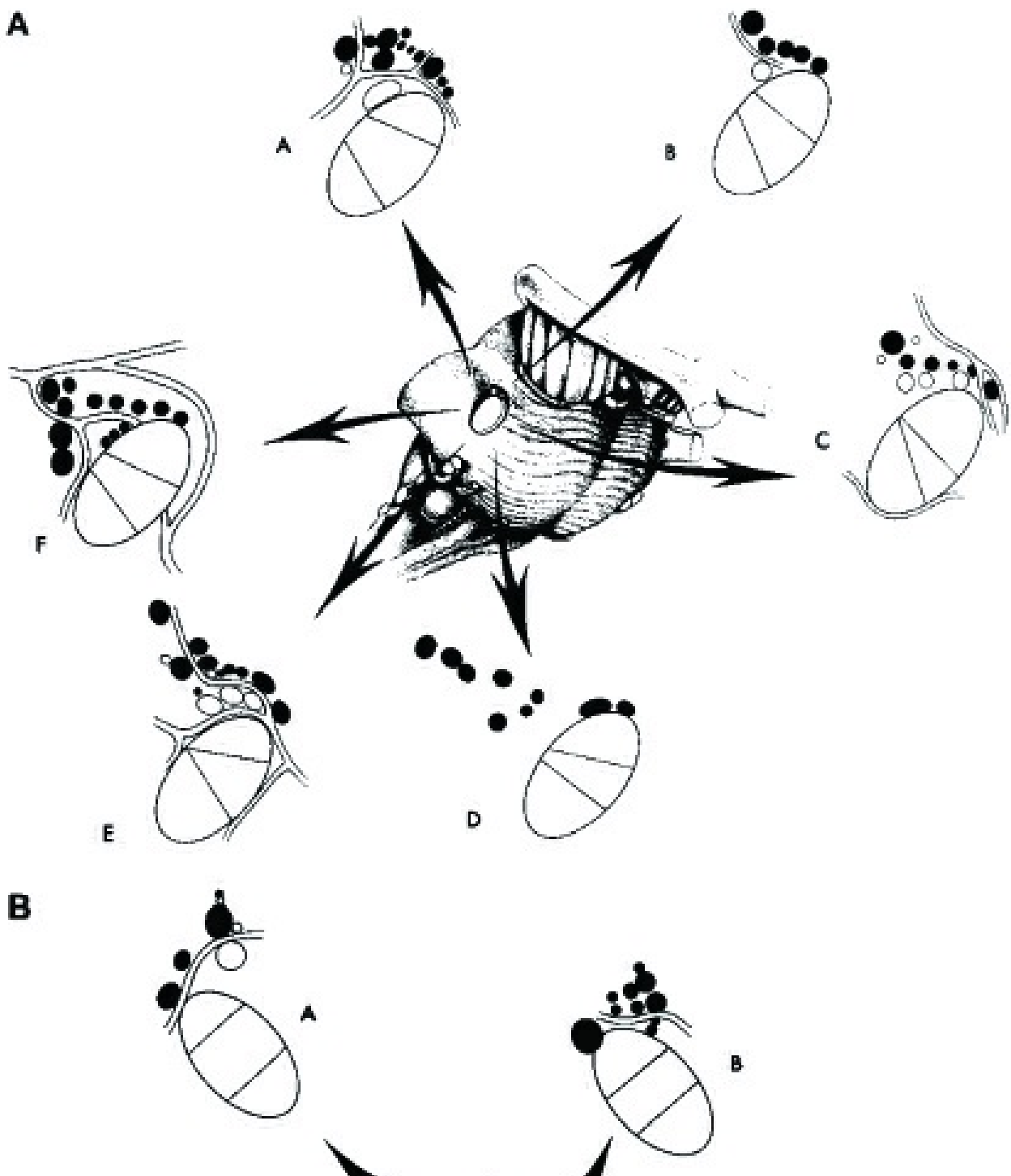
FIGURE 4.1. Retrosigmoid exposure of the nerves in the right cerebellopontine angle. A, the vestibulocochlear nerve enters the internal acoustic meatus with a labyrinthine branch of the AICA. The PICA courses around the glossopharyngeal, vagus, and accessory nerves. The abducens nerve ascends in front of the pons. A subarcuate artery enters the subarcuate fossa superolateral to the porus of the meatus. Choroid plexus protrudes into the cerebellopontine angle behind the glossopharyngeal and vagus nerves. B, the posterior wall of the internal acoustic meatus has been removed. The cleavage plane between the upper bundle, formed by the superior vestibular nerve, and the lower bundle, formed by the inferior vestibular and cochlear nerves, was begun laterally where the nerves have separated near the meatal fundus and extended medially. The nervus intermedius arises on the anterior surface of the vestibulocochlear nerve, has a free segment in the cistern and/or meatus, and joins the facial nerve distally. The facial nerve is located anterior to the superior vestibular nerve and the cochlear nerve is anterior to the inferior vestibular nerve. C, the cleavage plane between the cochlear and inferior vestibular nerves, which is well developed in the lateral end of the internal acoustic meatus, has been extended medially. Within the cerebellopontine angle, the superior vestibular nerve is posterior and superior, the facial nerve anterior and superior, the inferior vestibular nerve posterior and inferior, and the cochlear nerve anterior and inferior. D, the superior and inferior vestibular nerves have been divided to expose the facial and cochlear nerves. A labyrinthine branch of the PICA enters the internal meatus. A., artery; A.I.C.A., anteroinferior cerebellar artery; Chor. Plex., choroid plexus; CN, cranial nerve; Coch., cochlear; Flocc., flocculus; Inf., inferior; Intermed., intermedius; Labyr., labyrinth; N., nerve; Nerv., nervus; Pet., petrosal; P.I.C.A., posteroinferior cerebellar artery; Subarc., subarcuate; Sup., superior; V., vein; Vest., vestibular.



[Click here](#) to view the interactive module and related content for this image.

FIGURE 4.2. Lateral views, right trigeminal nerve. A, Meckel's cave, the cistern, which extends forward from the posterior fossa along the posterior trigeminal root to the level of the mid portion of the ganglion, has been exposed by removing the lateral dural wall of the cave. The motor root arises rostral to the sensory root and passes through Meckel's cave on the medial side of the posterior sensory root and ganglion. B, the dura has been removed to expose the posterior root and ganglion and the three trigeminal divisions. There are diffuse anastomoses between the rootlets posterior to the ganglion. C, enlarged view of the diffuse

anastomosis in the region of Meckel's cave. D, four motor rootlets, which arise around the rostral margin of the sensory root, have been elevated to expose the anastomoses between the motor and sensory roots. The cerebellar lip projects forward and may hide the junction of the sensory root with the pons in the retrosigmoid approach. E, a cleavage plane has been started anteriorly and extended backward to the level of the posterior root. The first-division fibers are rostromedial within the posterior root and the third-division fibers caudolateral with the second division being in an intermediate location. Cav., cavernous; Cereb., cerebellar; CN, cranial nerve; Gang., ganglion; Post., posterior; V., vein.



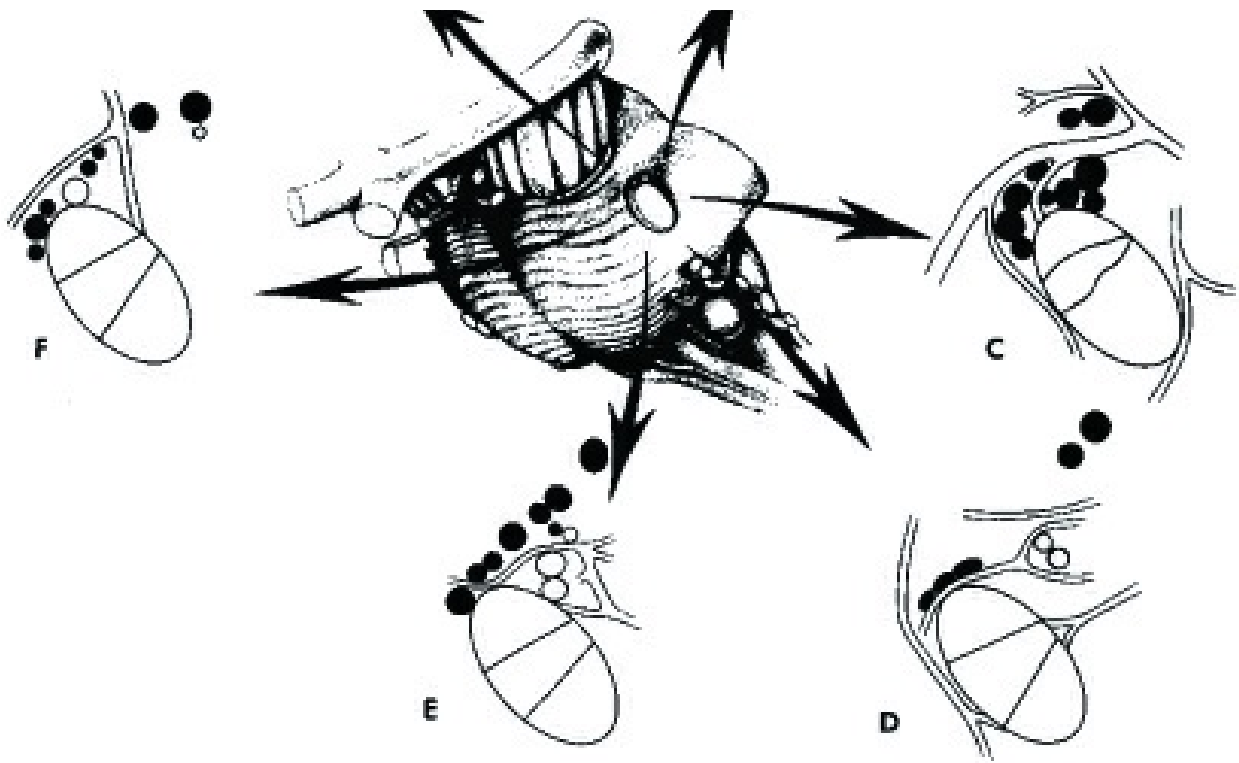
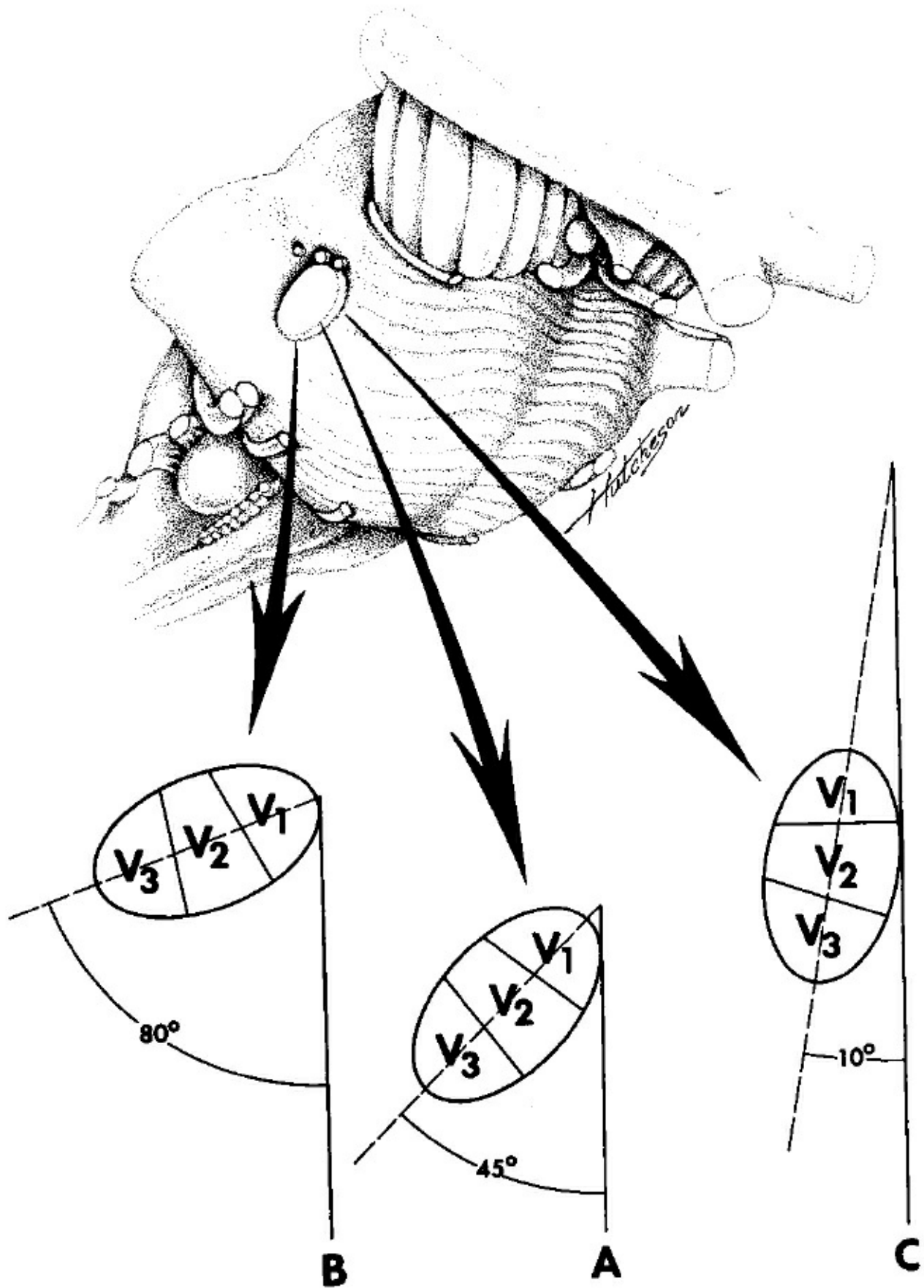


FIGURE 4.3. Diagrams of 12 trigeminal nerves showing the relationship of the trigeminal sensory root, motor rootlets, and aberrant sensory rootlets at the site of entry into the pons. The central diagrams are for orientation and show the elliptical cross section of the sensory root. The large ovals (A–F) represent the sensory root and are oriented in the same manner as the sensory root in the central diagram. The sites of origin of the motor rootlets are black. Upper: Nerves on the right. Only 5 motor rootlets are present in B, but 13 are seen in F. The aberrant sensory rootlets are shown by the dark outline with clear center. None are present in D and F. In C and E, some aberrant rootlets arise farther from the sensory root than some of the motor rootlets. Lower, nerves on the left. Only 4 motor rootlets are present in A, but there are 10 in B and C. Aberrant sensory rootlets are shown by the dark outline with clear center. None are present in B and C. In A, D, E, and F, some aberrant rootlets arise farther from the sensory root than some of the motor rootlets. Lines through the oval representing the main sensory root show portions of the nerve from each of the three divisions. In all diagrams, the rostromedial portion is from the first division, the caudolateral portion is from the third division, and the second division is in an intermediate position. In all these nerves, except A and B in the left nerve, the second division fibers make up a greater portion of the medial than the lateral

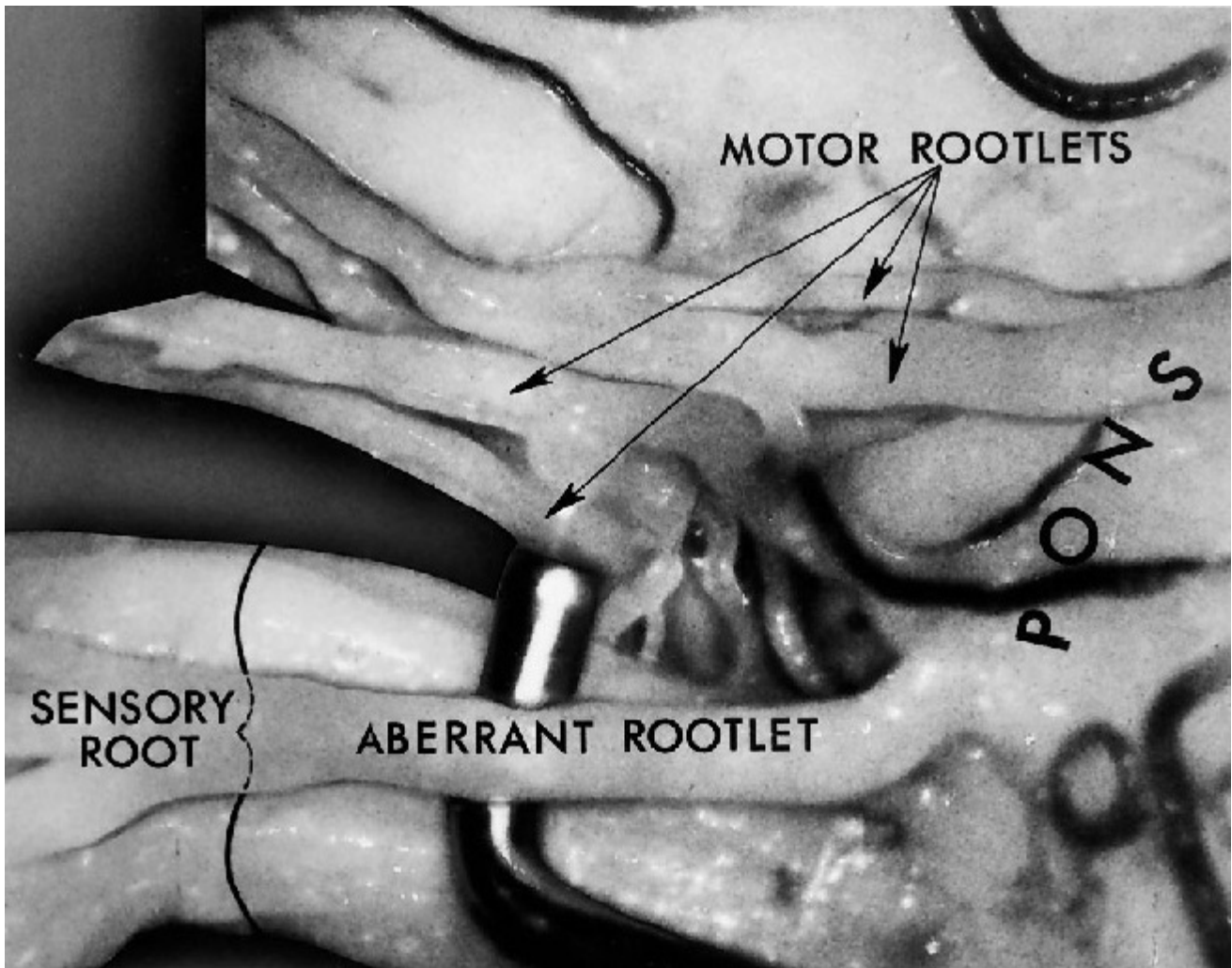
portion of the sensory root. Small arteries or veins coursing between the rootlets at the level of entry into the pons are shown in all diagrams of both nerves, except D in the right nerve (upper). (From, Gudmundsson K, Rhoton AL Jr, Rushton JG: Detailed anatomy of Surgical approach, the intracranial portion of the trigeminal nerve. *J Neurosurg* 35:592-600, 1971 [12].)



[Click here](#) to view the interactive module and related content for this image.

FIGURE 4.4. Variability of the longest axis of the elliptical cross section of

the trigeminal nerve at the pons (broken line) to the longitudinal axis of the body (solid line). The long axis of most nerves makes a 40- to 50-degree angle with the longitudinal axis of the body (A); however, this can vary from 10 degrees (C) to 80 degrees (B). In B, the third division is almost directly lateral to the first division, and in C, it is almost directly caudal. (From, Gudmundsson K, Rhoton AL Jr, Rushton JG: Detailed anatomy of the intracranial portion of the trigeminal nerve. J Neurosurg 35:592-600, 1971 [12].)



[Click here](#) to view the interactive module and related content for this image.

FIGURE 4.5. Lateral view of the left trigeminal nerve. A nerve hook is between the large aberrant sensory rootlet and the main sensory root. An aberrant rootlet arises from the pons directly lateral to the sensory root and joins the sensory root about 1 cm from the brainstem. Four motor rootlets are seen above the sensory root. (From, Gudmundsson K,

Rhoton AL Jr, Rushton JG: Detailed anatomy of the intracranial portion of the trigeminal nerve. *J Neurosurg* 35:592-600, 1971 [12].)

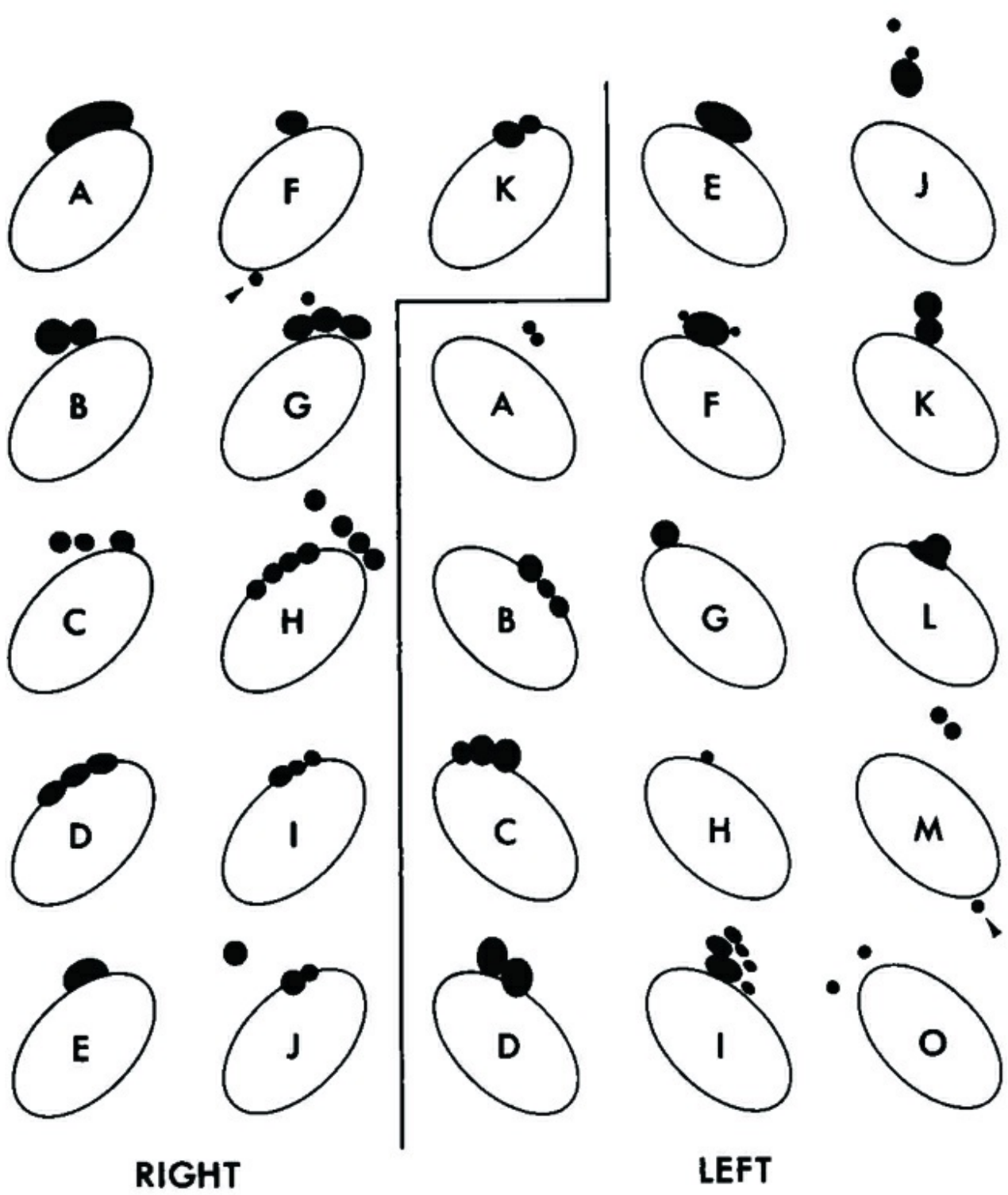
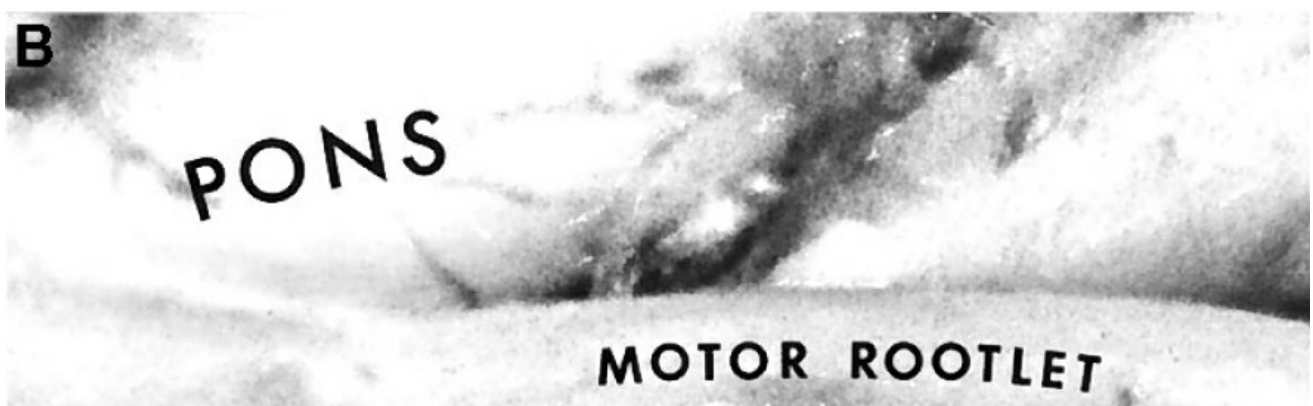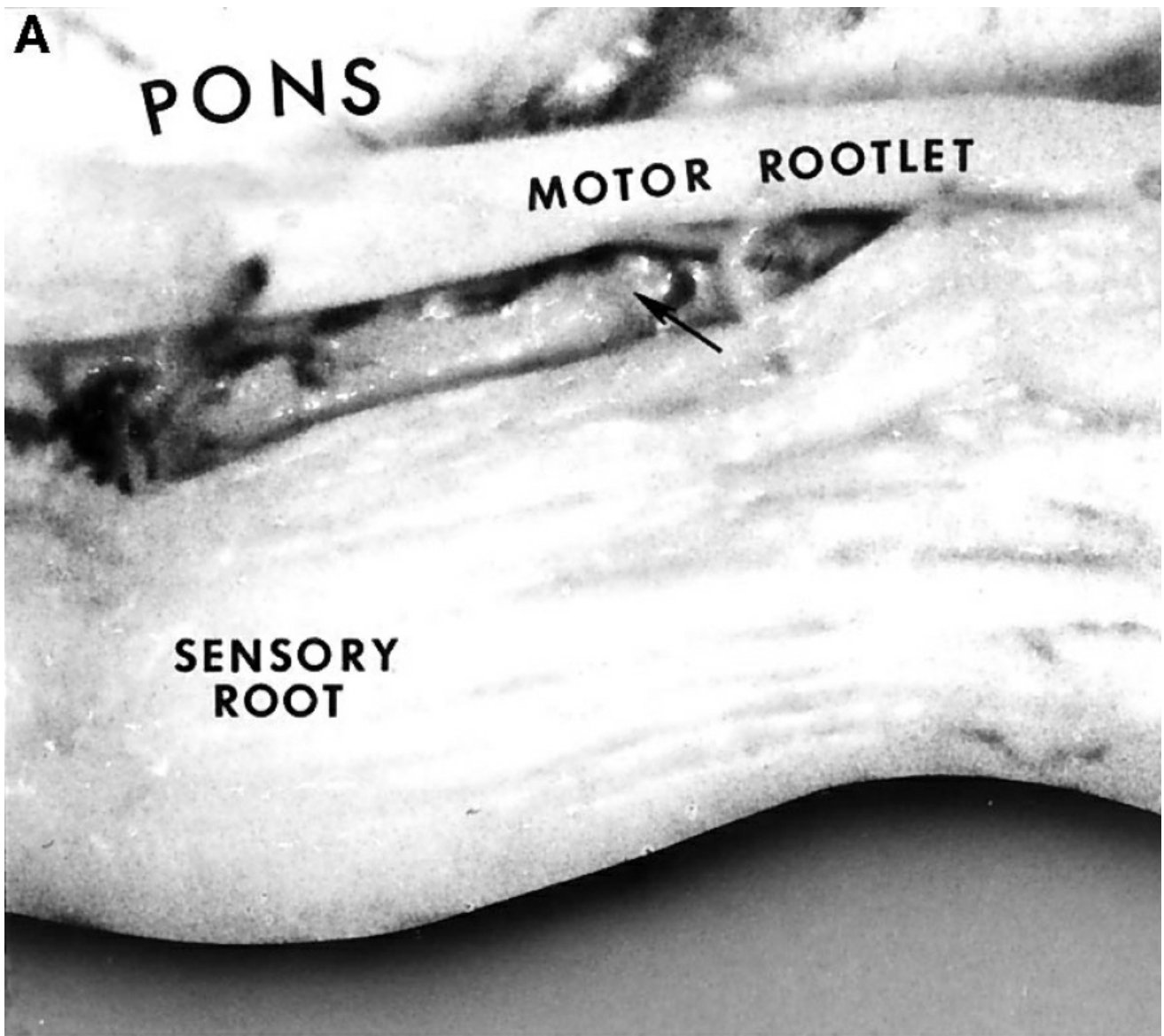


FIGURE 4.6. Origin of the aberrant sensory rootlets in relation to the main sensory root. The large, clear oval represents a cross section of the sensory root at the level of entry into the pons. Origin of aberrant rootlets is in solid black. All nerves to the left of the solid line are from the right side and are oriented the same as the nerves shown in Figure 4.3 (upper). Those to the right of the line are from the left side and are

oriented as shown in Figure 4.3 (lower). The rootlet origin shown with the arrow below F (right) goes with sensory root G, and the rootlet origin shown with the arrow below M (left) goes with sensory root O. The rostral margin of the root is superior and the caudal margin is inferior on the diagrams. No aberrant sensory root originates caudal to the main sensory root. (From, Gudmundsson K, Rhoton AL Jr, Rushton JG: Detailed anatomy of the intracranial portion of the trigeminal nerve. J Neurosurg 35:592-600, 1971 [12].)



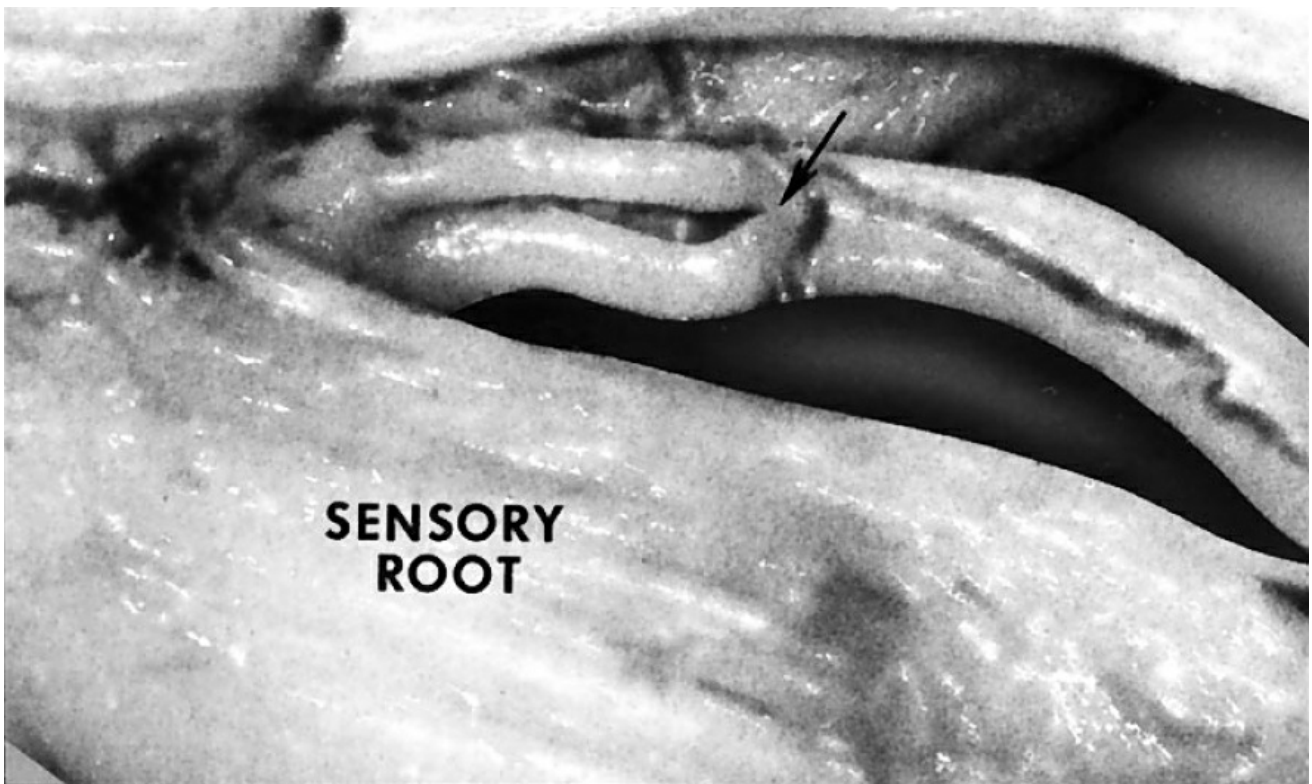


FIGURE 4.7. A, lateral view of the right trigeminal nerve near its junction with the pons. The arrow points to the intermediate group of fibers between the motor rootlet and the sensory root. B, the same trigeminal nerve. The arrow points to the intermediate group of fibers that proved to be a motor rootlet when traced distally. This illustrates the difficulty in telling whether an intermediate group of fibers is motor or sensory unless the nerve bundles can be separated and examined individually. (From, Gudmundsson K, Rhoton AL Jr, Rushton JG: Detailed anatomy of the intracranial portion of the trigeminal nerve. *J Neurosurg* 35:592–600, 1971 [12].)

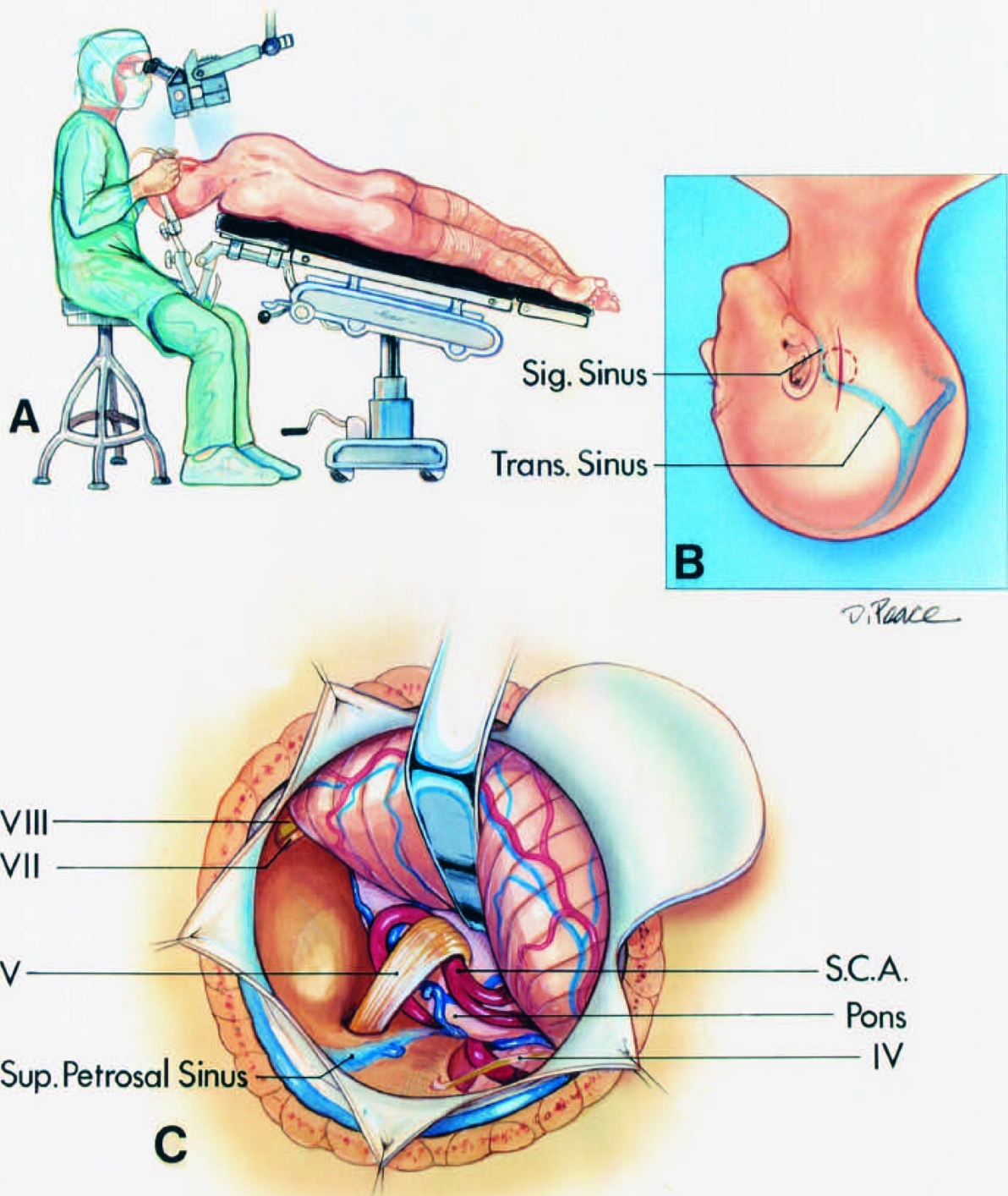


FIGURE 4.8. Retrosigmoid approach to the trigeminal nerve for a microvascular decompression operation. A, (upper left), the patient is positioned in the three-quarter prone position. The surgeon is seated at the head of the table. The table is tilted so that the feet are lower than the heart. B, the vertical paramedian incision crosses the asterion. The superolateral margin of the craniotomy is positioned at the junction of the transverse and sigmoid sinuses. C, the superolateral margin of the

cerebellum is gently elevated using a brain spatula tapered from 10 mm at the base to 3 or 5 mm at the tip to expose the site at which the trigeminal nerve enters the pons. The brain spatula is advanced and aligned parallel to the superior petrosal sinus. The trochlear nerve is at the superior margin of the exposure and the facial and vestibulocochlear nerves are at the lower margin. The dura is tacked up to the adjacent muscles to maximize the exposure along the superolateral margin of the cerebellum. The main trunk of the SCA loops down into the axilla of the trigeminal nerve. (From, Rhoton AL Jr: Microsurgical anatomy of decompression operations on the trigeminal nerve, in Rovit RL, Murali R, Jannetta PJ (eds): Trigeminal Neuralgia. Baltimore, Williams & Wilkins, 1990, pp 165-200 [34].) S.C.A., superior cerebellar artery; Sig., sigmoid; Sup., superior; Trans., transverse.

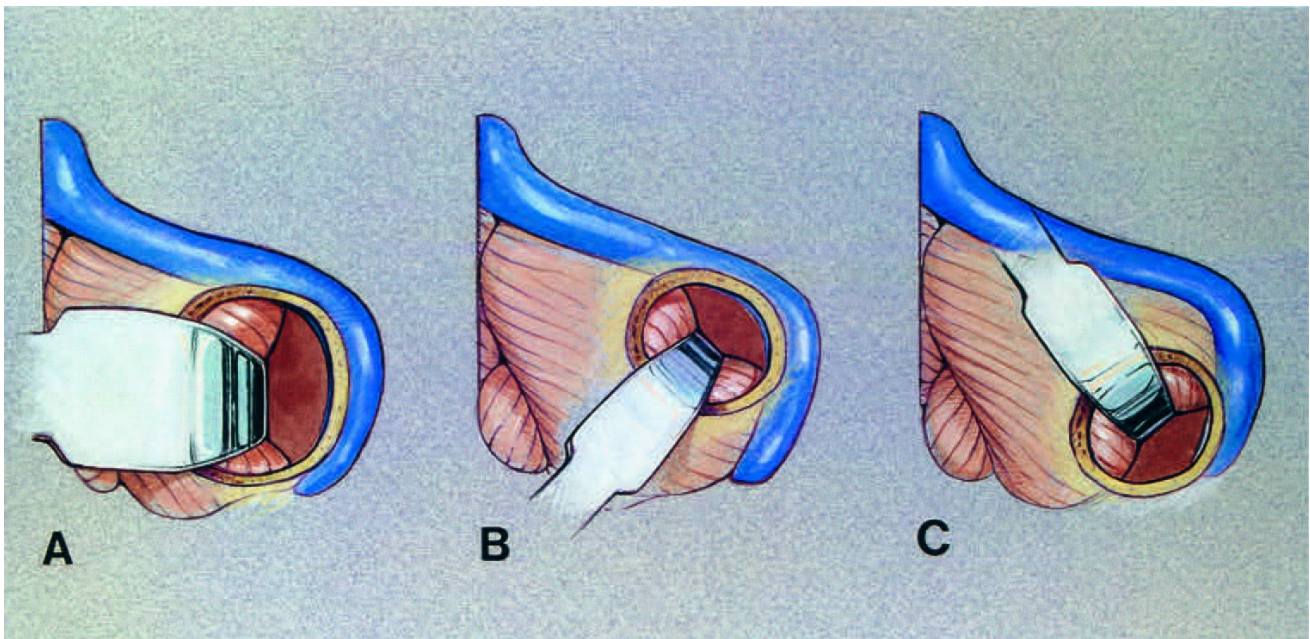


FIGURE 4.9. Direction of the application of brain spatulas for surgery in the various compartments of the cerebellopontine angle. **A**, lateral exposure for a lesion in the midportion of the cerebellopontine angle, such as an acoustic neuroma. The site of the craniotomy below the transverse sinus and medial to the sigmoid sinus is shown for removing an acoustic neuroma or other lesion involving multiple neurovascular complexes. The spatula protects the lateral surface of the cerebellum after the cerebellum relaxes after the opening of the cisterns and removing cerebrospinal fluid. A brain spatula tapered from 20 or 25 mm at the base to 15 or 20 mm at the tip is commonly used during the

removal of large tumors, and a spatula tapered from 15 mm at the base to 10 mm at the tip is used for small tumors. B, spatula application for exposing the upper neurovascular complex for a microvascular decompression operation for trigeminal neuralgia. A spatula tapered from 10 mm at the base to 3 or 5 mm at the tip is commonly selected. The spatula is placed parallel to the superior petrosal sinus. C, retractor application for the exposure of the lower neurovascular complex. This approach also is used in hemifacial spasm because the facial nerve root exit zone is located only a few millimeters above the glossopharyngeal nerve and the PICA is commonly a compressing vessel. A brain spatula tapered from 10 mm at the base to 3 or 5 mm at the tip is commonly used for operations for hemifacial spasm. (From, Rhoton AL Jr: Instrumentation, in Apuzzo MLJ (ed): Brain Surgery: Complication Avoidance and Management. New York, Churchill-Livingstone, 1993, vol 2, pp 1647–1670 [36].)

Trigeminal Root Anatomy

The fibers from the third division remain in a caudolateral position in the posterior root throughout the interval from the ganglion to the pons, the first division rostromedial, with second-division fibers in an intermediate position (Figs. 4.2 and 4.3). Conclusions that the third-division fibers remain caudolateral and that the first-division fibers remain rostromedial from the pons to the ganglion agree with data from clinical and laboratory studies (5, 8, 31). There are anastomoses between the fibers from each division in the area posterior to the ganglion (Fig. 4.2). Results of selective rhizotomy of the posterior root indicate that somatotopic localization with the third division inferolaterally and the ophthalmic division dorsomedially is well maintained posterior to, and despite, the prominent retrogasserian anastomoses (5).

A cross section of the sensory root between the pons and the petrous apex is elliptical. In most nerves, the angle between the longest diameter of this cross section and the long axis of the body is 40 to 50 degrees; the angle, however, can vary from 10 to 80 degrees (Fig. 4.4) (12). An angle of 80 degrees places the third-division fibers almost directly lateral to those

of the first division; but an angle of 10 degrees places the third-division fibers almost directly caudal to those of the first division. The variability in the degree of rotation of the sensory root entering the pons may explain some differences in the quantity of sensation retained after partial section of the nerve in the posterior cranial fossa. The most frequent pattern is for the third-division fibers to be caudolateral to the first- division fibers; some nerves, however, are rotated so that third-division fibers will be almost directly lateral to the first division; others are rotated nearly 70 degrees away from this so that the third-division fibers will be directly caudal to those of the first division. Cutting into the nerve partially from a caudolateral direction would give a significantly different pattern of sensory loss if the nerve is rotated with the third division lateral to the first, than if the third division is almost directly caudal to the first division.

At the junction of the nerve with the pons, as many as 15 separate nerve rootlets may be spread around the rostral half of the site where the main sensory cone enters the pons (12). These rootlets are either motor or aberrant sensory rootlets. The aberrant sensory fibers are small rootlets that penetrate the pons outside the main sensory root (Figs. 4.2, 4.5, and 4.6). The aberrant rootlets arise around the rostral two-thirds of the nerve and usually join the root a short distance from the brainstem. There may be as many as eight aberrant roots.

Those arising rostral to the sensory root most frequently enter the first division, and those arising more caudally enter the second or third division. No aberrant rootlets originate around the caudal third of the sensory root. Of 66 aberrant rootlets found in our study of 50 trigeminal nerves, 49 went into the first division, 10 into the second division, and 7 into the third division (12). The findings that aberrant rootlets are most commonly related to the first division agree with Dandy's conclusion that when the accessory fibers are spared, sensation in the first division tends to be spared (5). The aberrant rootlets appear to be nonspecific sensory fibers separated from the root by transverse pontine fibers (12, 43). Aberrant roots contribute mainly to the first division and probably do not convey a specific sensory modality from all three divisions.

Motor rootlets also arise around the rostral part of the nerve; however, they tend to arise further from the main sensory cone than do the accessory sensory rootlets. The motor root may be composed of 4 to 14 separate rootlets, each having a separate exit from the pons (Figs. 4.2, 4.3, and 4.7) (12). The aberrant sensory fibers usually arise closer to the main sensory root than to the motor fibers. Some aberrant sensory fibers, however, will arise further from the main sensory root than does the origin of some motor filaments; for this reason, it is easy to confuse aberrant sensory fibers and motor filaments at the nerve/pons junction.

Anastomoses between the motor and sensory roots are present in most nerves (Fig. 4.2). Those sensory fibers associated with the motor root from the pons to just proximal to the ganglion, where they anastomose with the sensory root, would be spared with a rhizotomy in the posterior fossa. Horsley et al. (15) suspected that there were sensory fibers in the trigeminal motor root, suggesting that the motor root be sectioned if trigeminal neuralgia recurred after the complete section of the sensory root. Our studies offer two explanations for the accidental preservation of sensation after posterior rhizotomy: 1) sparing of the aberrant sensory rootlets, and 2) sparing of the anastomotic sensory fibers that run with the motor root at the level of the rhizotomy (12). Anastomosis is a more likely explanation for the accidental sensory preservation and recurrence of trigeminal neuralgia after the section of the posterior root, because anastomotic rootlets are present throughout the interval from the pons to the ganglion. Aberrant sensory roots are present in only half of the nerves. They provide another explanation for the preservation of sensation after section of the main sensory root.

Anatomy of Vascular Compression in the Upper Neurovascular Complex

In 1934, Dandy postulated that arterial compression and distortion of the trigeminal nerve might be the cause of trigeminal neuralgia (6). He described the superior cerebellar artery (SCA) as affecting the nerve in 30.7% of his 215 cases of trigeminal neuralgia. The vascular compression theory failed to gain acceptance at the time, but it awaited the better

demonstration of these pathological changes at surgery by Jannetta (17, 21) using magnification provided by the operating microscope.

This upper neurovascular complex, for a vascular decompression operation, is approached using a vertical scalp incision crossing the asterion, which usually overlies the junction of the lower half of the transverse and sigmoid sinuses (Fig. 4.8). The bone opening, a small craniotomy, located behind the upper half of the sigmoid sinus, exposes the edge of the junction of the transverse and sigmoid sinuses in its superolateral margin. The cerebellum is relaxed by opening the arachnoid and removing cerebrospinal fluid, a maneuver made safer by the use of the operating microscope. A narrow brain spatula, commonly 3 mm at the tip, is introduced parallel and just below the superior petrosal sinus to elevate the superolateral margin of the cerebellum (Fig. 4.9) (36). The use of a wider spatula or a lower entry point along the lateral cerebellum risks damaging the vestibulocochlear nerve. A bridging petrosal vein, which commonly blocks access to the trigeminal nerve, is coagulated with gentle bipolar coagulation and divided nearer its junction with the brain than to the superior petrosal sinus. Unexpected bleeding encountered as the superolateral margin of the cerebellum is elevated, if venous in appearance, is usually related to stretching and tearing of the petrosal veins that pass from the superior surface of the cerebellum to the venous sinus in the tentorium or, if arterial in appearance, to tearing of the subarcuate branch of the anterior inferior cerebellar artery (AICA) behind the internal auditory canal at its site of penetration of the dura covering the subarcuate fossa. The trochlear nerve is identified before opening the arachnoid behind the trigeminal nerve, because it may be difficult to see the nerve after the arachnoid has been opened and shrinks into thick white clumps that may hide the nerve. Usually, the trochlear nerve is several millimeters above the trigeminal nerve; it may be carried downward, however, if it is adherent to a segment of the SCA that has looped into the axilla of the trigeminal nerve. The overhanging lip of the cerebellomesencephalic fissure must be retracted gently to expose the junction of the nerve with the pons.

The most common finding at a vascular decompression operation for

trigeminal neuralgia is a segment of the SCA compressing the trigeminal nerve (13, 18). Normally, the SCA encircles the brainstem well above the trigeminal nerve. In adults, the SCA commonly makes a shallow, caudal loop and courses inferiorly for a variable distance on the lateral side of the pons (Figs. 4.8 and 4.10-4.12). In those cases with the most prominent caudally projecting loop, contact between the artery and the trigeminal nerve occurs. The point of contact with the SCA is usually on the superior or superomedial aspect of the nerve; and often a few fascicles of the nerve are distorted by an SCA that has looped down into the axilla between the medial side of the nerve and the pons (Figs. 4.8 and 4.12). An arterial loop in the axilla may not be visible from the retrosigmoid view behind the trigeminal nerve if the SCA courses around the brainstem directly in front of the nerve. The loop of the SCA also may be difficult to see if the artery passes over the rostral aspect of the nerve very close to the brainstem, where it may be hidden by the overhanging lip of the cerebellomesencephalic fissure. The loop of the SCA may be seen dangling below the lower margin of the nerve, even though it is not visible above the nerve. These loops of the SCA, however, always pass rostrally along the medial and superior surfaces of the nerve to reach the cerebellomesencephalic fissure. The medial axilla of the nerve must be carefully explored before concluding that there is no arterial loop in the axilla of the nerve. It is important to remember that the trunks do not pass directly from the side of the brainstem to the superior surface of the cerebellum; they dip into the deep fissure between the cerebellum and midbrain at the posterior margin of the trigeminal nerve. The SCA gives off perforating arteries that may limit the degree of repositioning of the artery achievable in a microvascular decompression operation.

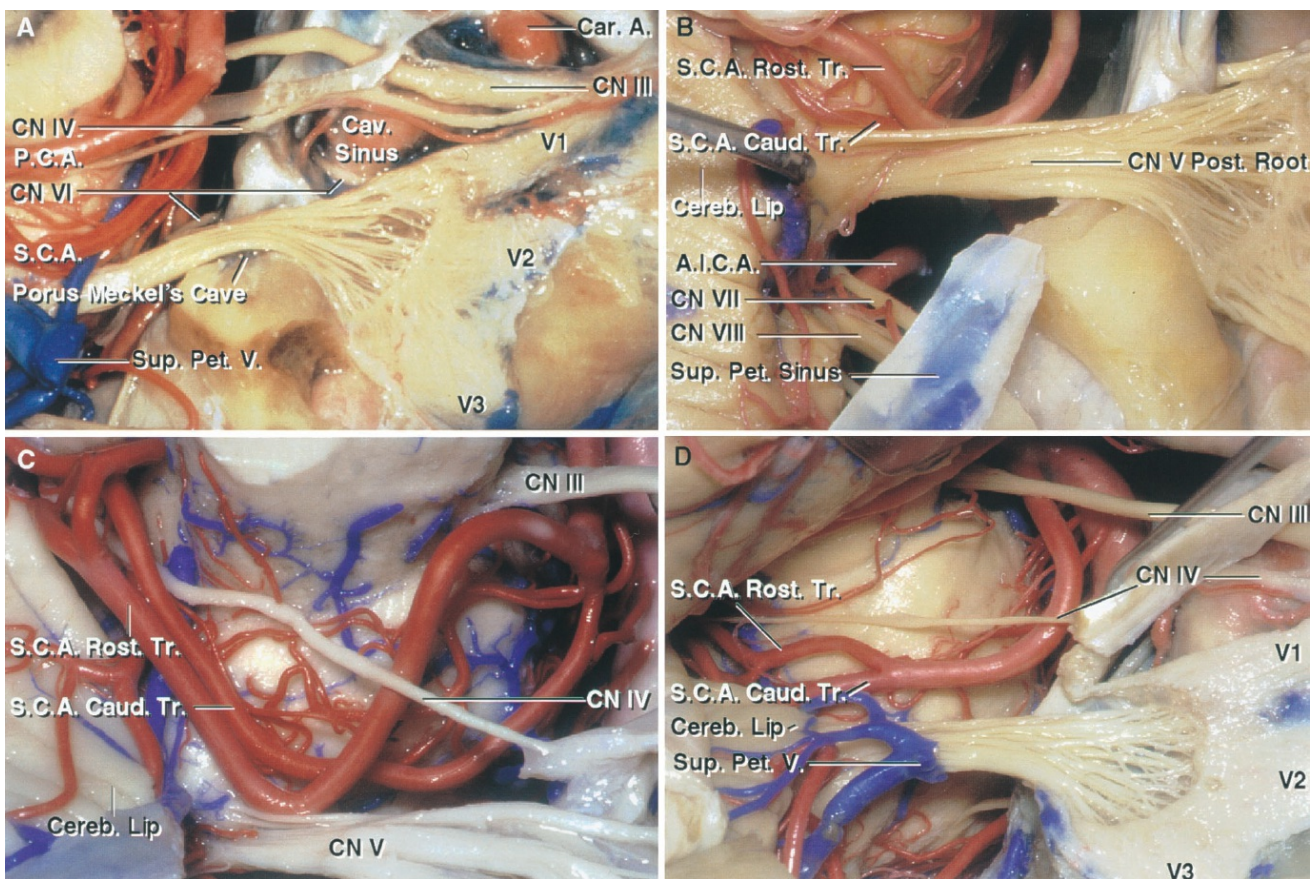
The most common site of compression of the trigeminal nerve on the SCA is at the junction of the main trunk with the origin of the rostral and caudal trunks (Figs. 4.11 and 4.12) (34). However, other sites of compression are seen, depending on how far distal the artery bifurcates in relation to the trigeminal nerve. If the SCA bifurcates near the basilar artery or if there is a duplicate configuration in which the rostral and caudal trunks arise directly from the basilar artery, both trunks may loop down into the axilla and compress the nerve. Alternatively, if the artery

bifurcates before reaching the nerve, the caudal trunk may compress the nerve and the rostral trunk may course well above the nerve. If the artery bifurcates distal to the nerve, only the main trunk will be involved in the compression. The point of bifurcation of the SCA does affect the caliber of the vessel that makes contact with the nerve. The contacting vessel will be of a smaller caliber if the SCA bifurcates before reaching the trigeminal nerve.

A less frequent source of compression of the trigeminal nerve is by the AICA (Figs. 4.11 and 4.12). Normally, the AICA passes around the pons below the trigeminal nerve with the facial and vestibulocochlear nerves. The AICA, however, may have a high origin and loop upward to indent the medial or lower surface of the trigeminal nerve before passing downward to course with the facial and vestibulocochlear nerves. A serpentine basilar artery also may wander laterally and compress the medial side of the trigeminal nerve (43). This type of basilar artery often is elongated and has a fusiform configuration. More than one artery may compress the nerve. In a few cases, the SCA will compress the rostral surface of the nerve and the AICA will compress the caudal surface. Infrequently, the posteroinferior cerebellar artery (PICA) may reach and groove the undersurface of the trigeminal nerve. The trigeminal nerve also may be compressed by a large pontine branch of the basilar artery (Figs. 4.11 and 4.12). Normally, these pontine branches pass around and penetrate the pons before reaching the trigeminal nerve. A large pontine artery, however, may indent the medial surface of the trigeminal nerve and then course rostral or caudal to the nerve to supply the pons behind the nerve.

In a previous study of 50 cadaveric trigeminal nerves, we found that 26 had a point of contact with the SCA in the posterior cranial fossa (14). In the 26 nerves having a point of contact with the SCA, the segment of the SCA involved was the main trunk before its bifurcation in 8, the caudal trunk distal to the bifurcation in 11, the rostral trunk in 2, both the rostral and caudal trunk in 4, and a hemispheric branch of the caudal trunk in 1. In that study, the site of vascular contact was commonly a few millimeters peripheral to the point of entry of the nerve into the pons (average, 3.7

mm) rather than at the root entry zone, as is seen in most of our cases with trigeminal neuralgia. In one cadaveric specimen, the vascular contact was more than 1 cm from the pons. In 6 of the 50 cadaveric nerves, the contact occurred at the pontine sensory root entry zone of the trigeminal nerve. The main trunk of the AICA also impinged on 4 of the 50 cadaveric trigeminal nerves that were examined, and in 3 of these, there was also a point of contact between the nerve and the SCA. One nerve also was contacted on its superior surface by the SCA and on its inferior surface by both trunks of a duplicated AICA. Not all of these contacts seen in our anatomic studies produced distortion of the nerve or occurred at the sensory root entry zone, both of which are postulated as a prerequisite for the production of trigeminal neuralgia (18).



[Click here](#) to view the interactive module and related content for this image.

FIGURE 4.10. Trigeminal nerve and SCA relationships. A, the trigeminal posterior root, ganglion, and three divisions have been exposed by removing the dura from the lateral wall of Meckel's cave and the cavernous sinus. The posterior root enters the midpons below the SCA

and is intertwined with the branches of the superior petrosal vein. B, the SCA loops downward and, at the junction of the rostral and caudal trunks, contacts the posterior trigeminal root at the pontine junction. The cerebellar lip projects forward and may block access to the junction of the trigeminal nerve and pons in the retrosigmoid approach. C, SCA with an early bifurcation. The rostral trunk loops downward and indents the upper surface of the trigeminal nerve. D, another SCA passes around the pons and bifurcates into its rostral and caudal trunks above the trigeminal root entry zone. A., artery; A.I.C.A., anteroinferior cerebellar artery; Car., carotid; Caud., caudal; Cav., cavernous; Cereb., cerebellar; CN, cranial nerve; Pet., petrosal; Post., posterior; Rost., rostral; S.C.A., superior cerebellar artery; Sup., superior; Tr., trunk; V., vein.

Venous Relationships

Compression and distortion of the trigeminal nerve by the surrounding veins, although less frequent than arterial compression, also is found in trigeminal neuralgia (Figs. 4.13 and 4.14) (2, 18, 26). It is the superior petrosal veins that empty into the superior petrosal sinus that are most frequently encountered in operative approaches to the trigeminal nerve and that most commonly compress the trigeminal nerve.

The superior petrosal veins are among the largest and most frequently encountered veins in the posterior fossa. The superior petrosal veins may be formed by the terminal segment of a single vein or by the common stem formed by the union of several veins. The most common tributaries of the superior petrosal veins are the transverse pontine and pontotrigeminal veins, the veins of the cerebellopontine fissure and the middle cerebellar peduncle, and the common stem of the veins draining the lateral part of the cerebellar hemisphere. The transverse pontine veins, which pass near the trigeminal nerve to reach the bridging veins entering the superior petrosal sinus, are the most frequent veins to compress the trigeminal nerve. They may course medially in the axilla of the nerve or they also may pass above, below, or lateral to the nerve and may indent any of its surfaces. The vein of the middle cerebellar peduncle may compress the lateral or medial surface of the trigeminal nerve before

joining the petrosal veins as it ascends in the pons. The vein of the cerebellopontine fissure may indent the lateral margin of the trigeminal nerve as it ascends toward the superior petrosal sinus, and the pontotrigeminal vein may indent the upper margin of the nerve.

The junction of these veins, which converge and form a single trunk before entering the superior petrosal sinus, usually is lateral to the trigeminal nerve. This junction, however, may be located medial to the trigeminal nerve, in which case the common trunk must pass around the trigeminal nerve before reaching the superior petrosal sinus. These common trunks also may compress the trigeminal nerve.

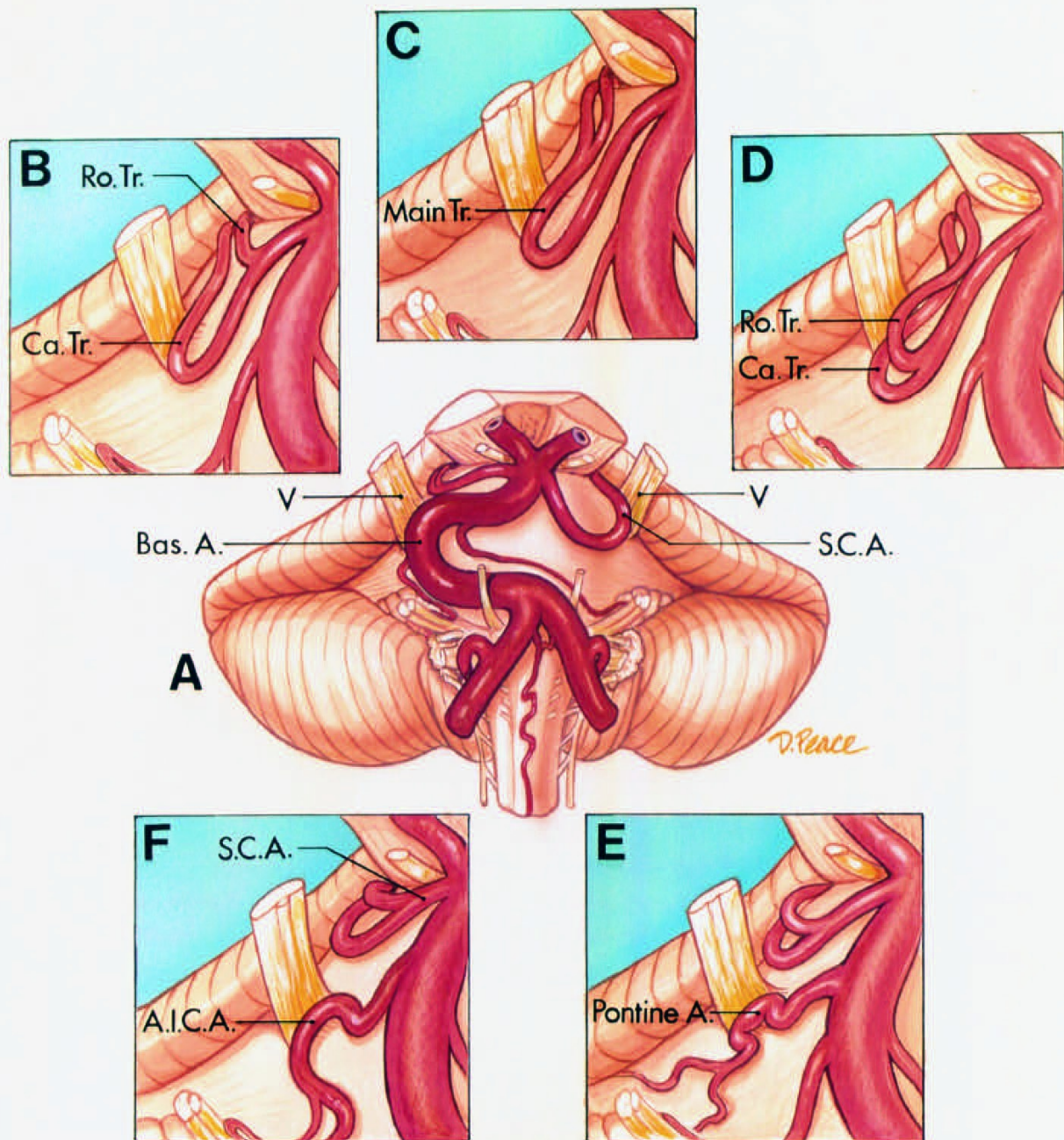


FIGURE 4.11. Sites of arterial compression of the trigeminal nerve. Orientation as shown in the central diagram. A, central diagram. The right trigeminal nerve is compressed by a tortuous basilar artery and the left trigeminal nerve is compressed by the main trunk of the SCA. B, the SCA bifurcates into rostral and caudal trunks before reaching the trigeminal nerve. The nerve is compressed by the caudal trunk. C, the SCA bifurcates distally to the nerve. The nerve is compressed by the main

trunk. D, the SCA bifurcates before reaching the nerve. The nerve is compressed by both the rostral and caudal trunks. E, the nerve is compressed by a large pontine artery. F, the nerve is compressed by an AICA that has a high origin and loops upward into the medial surface of the nerve. The SCA passes around the brainstem above the nerve. (From, Rhoton AL Jr: Microsurgical anatomy of decompression operations on the trigeminal nerve, in Rovit RL, Murali R, Jannetta PJ (eds): Trigeminal Neuralgia. Baltimore, Williams & Wilkins, 1990, pp 165–200 [34].) A., artery; A.I.C.A., anteroinferior cerebellar artery; Bas., basilar; Ca., caudal; Ro., rostral; S.C.A., superior cerebellar artery; Tr., tract; V., vein.

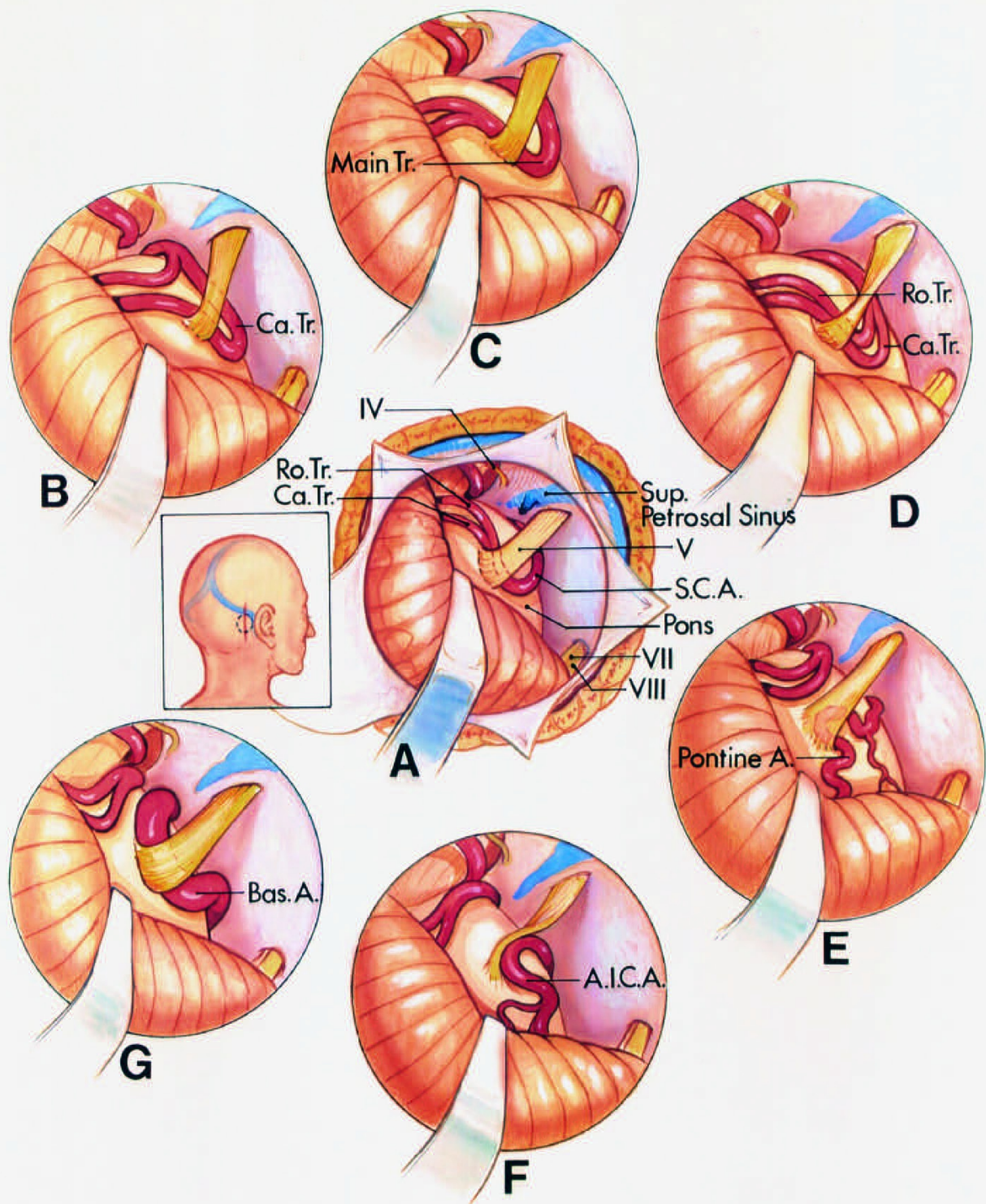


FIGURE 4.12. Sites of arterial compression of the trigeminal nerve as seen through a suboccipital craniotomy. A, central diagram. The site of the skin incision (solid line) and the craniotomy (interrupted line) are shown in the insert. The superolateral margin of the cerebellum is gently retracted to expose the trigeminal nerve and the SCA. The brain spatula is advanced parallel to the superior petrosal sinus. The trochlear nerve is at the superior margin of the exposure and the facial and

vestibulocochlear nerves are at the lower margin. The trigeminal nerve is compressed by a loop of the SCA that dangles down into the axilla of the nerve. The site of compression on the artery is at the junction of the main trunk with the rostral and caudal trunks. B, the nerve is compressed by the caudal trunk. C, the nerve is compressed by the main trunk. D, compression by both the rostral and caudal trunks. E, compression by a pontine branch of the basilar artery. F, compression by the AICA. G, compression by a tortuous basilar artery. A., artery; A.I.C.A., anteroinferior cerebellar artery; Bas., basilar; Ca., caudal; Ro., rostral; S.C.A., superior cerebellar artery; Sup., superior; Tr., trunk; V., vein. (From, Rhoton AL Jr: Microsurgical anatomy of decompression operations on the trigeminal nerve, in Rovit RL, Murali R, Jannetta PJ (eds): Trigeminal Neuralgia. Baltimore, Williams & Wilkins, 1990, pp 165–200 [34].)

Suprameatal Extension of the Retrosigmoid Approach

The part of the posterior surface of the temporal bone that forms the superior lip of the porus of the internal acoustic meatus is the site of a prominence, the suprameatal tubercle, that blocks access to the lateral margin of the trigeminal nerve and the prepontine cistern medial to the trigeminal nerve (Figs. 4.15 and 4.16). Removal of the suprameatal tubercle increases access to the region of the upper neurovascular complex around the trigeminal nerve, and may possibly avoid the need for a supratentorial craniotomy in exposing tumors that are located predominantly in the cerebellopontine angle but also extend into the posterior part of the middle fossa in the region of Meckel's cave (42). The tubercle, the most prominent bony elevation around the circumference of the internal acoustic meatus, is defined below by the internal acoustic meatus, above by the petrous ridge, laterally by a vertical line crossing the posterior edge of the porus of the internal acoustic meatus, and medially by a vertical line crossing the medial edge of the trigeminal notch, a depression in the petrous ridge located below the porus of Meckel's cave. Above and medial to the suprameatal tubercle, the posteromedial part of the floor of the middle cranial fossa is the site of the depression underlying Meckel's cave in which the posterior trigeminal root sits. The

most prominent posterior projection of the tubercle is located above the lateral half of the porus of the internal acoustic meatus.

The neural structures that surround and limit access to the suprameatal tubercle are the cerebellum posteriorly, the facial and vestibulocochlear nerves below, the trigeminal nerve above and medial, and the abducens nerve medially. The cerebellopontine cistern opens through the porus into Meckel's cave. Meckel's segment of the trigeminal nerve, which begins at the porus and extends to the trigeminal ganglion, is differentiated from the cavernous segment in the wall of the cavernous sinus. Meckel's segment is narrower adjacent to the porus and fans out as it approaches the posterior edge of the gasserian ganglion, which is embedded in the dura just anterior to the anterior edge of Meckel's cave.

The intraosseous structures, which limit the extent of the drilling if they are to be preserved, are the posterior part of the superior semicircular canal, the upper part of the posterior semicircular canal, and the common crus of the two canals. After removal of the suprameatal tubercle, the drilling can be extended below Meckel's cave to the edge of the petroclival fissure just in front of the inferior petrosal sinus and immediately lateral to the abducens nerve. Removing the bone in this area provides access, on average, to the posterior 10.3 mm (range, 8.0–13.0 mm) of Meckel's cave and the enclosed portion of the trigeminal nerve, and opens a 180-degree window around the lateral and lower surface of the posterior trigeminal root, which may be used for accessing the posterior part of the middle fossa (Figs. 4.15 and 4.16).

The size of the area created by removing the suprameatal tubercle and adjacent part of the petrous apex by the retrosigmoid route is limited superiorly by the superior petrosal sinus and the dura covering the upper surface of the petrous bone. The superior petrosal sinus can be divided, and Meckel's cave and the tentorium lateral to the porus of Meckel's cave can be opened to provide intradural access to the posteromedial part of the middle fossa, but cannot be extended forward to the horizontal portion of the petrous carotid.

The suprameatal extension of the retrosigmoid approach may permit

removal of some tumors that are located mainly in the posterior fossa but that extend into the middle fossa in the region of Meckel's cave. The space created after drilling the suprameatal tubercle and the bone medial to the internal auditory canal and below the trigeminal nerve was enough to extend the retrosigmoid approach as far as 13.0 mm (average, 10.3 mm) anterior to what could be achieved using the retrosigmoid approach alone (42). The extent to which the bone in the region of the suprameatal tubercle could be removed using the retrosigmoid approach is defined and limited by the neural and bony structures in the region. The cerebellum, with gentle retraction, limits the angle at which the suprameatal tubercle can be drilled, although when combined with evacuation of cerebrospinal fluid, it provides a space to adequately visualize and remove lesions medial to the suprameatal tubercle. A portion of this bone is commonly removed in approaching tumors extending into the internal acoustic meatus. It is possible to remove approximately 270 degrees of the circumference of the wall of the internal acoustic meatus when using the retrosigmoid approach; however, with the approach described herein, only the bone in the region of the suprameatal tubercle is removed. The drilling on the lateral side of the tubercle should avoid the posterior semicircular canal and common crus of the posterior and superior canals if hearing is to be preserved, but on the medial side, it can extend through the petrous apex into the side of the clivus.

Often, the subarcuate branch of the AICA must be obliterated to access the suprameatal tubercle. Accessing the suprameatal tubercle often requires that the superior petrosal veins be obliterated and divided. This allows the drilling to be directed medially along the lateral and lower margin of the porus of Meckel's cave. The dura along the lower and lateral margin of the porus of Meckel's cave and the tentorium lateral to the porus trigeminus can then be opened to expose the trigeminal nerve in the posterior part of Meckel's cave and the middle cranial fossa. Care is taken to protect the trochlear nerve if the tentorial incision is to be extended through the free edge.

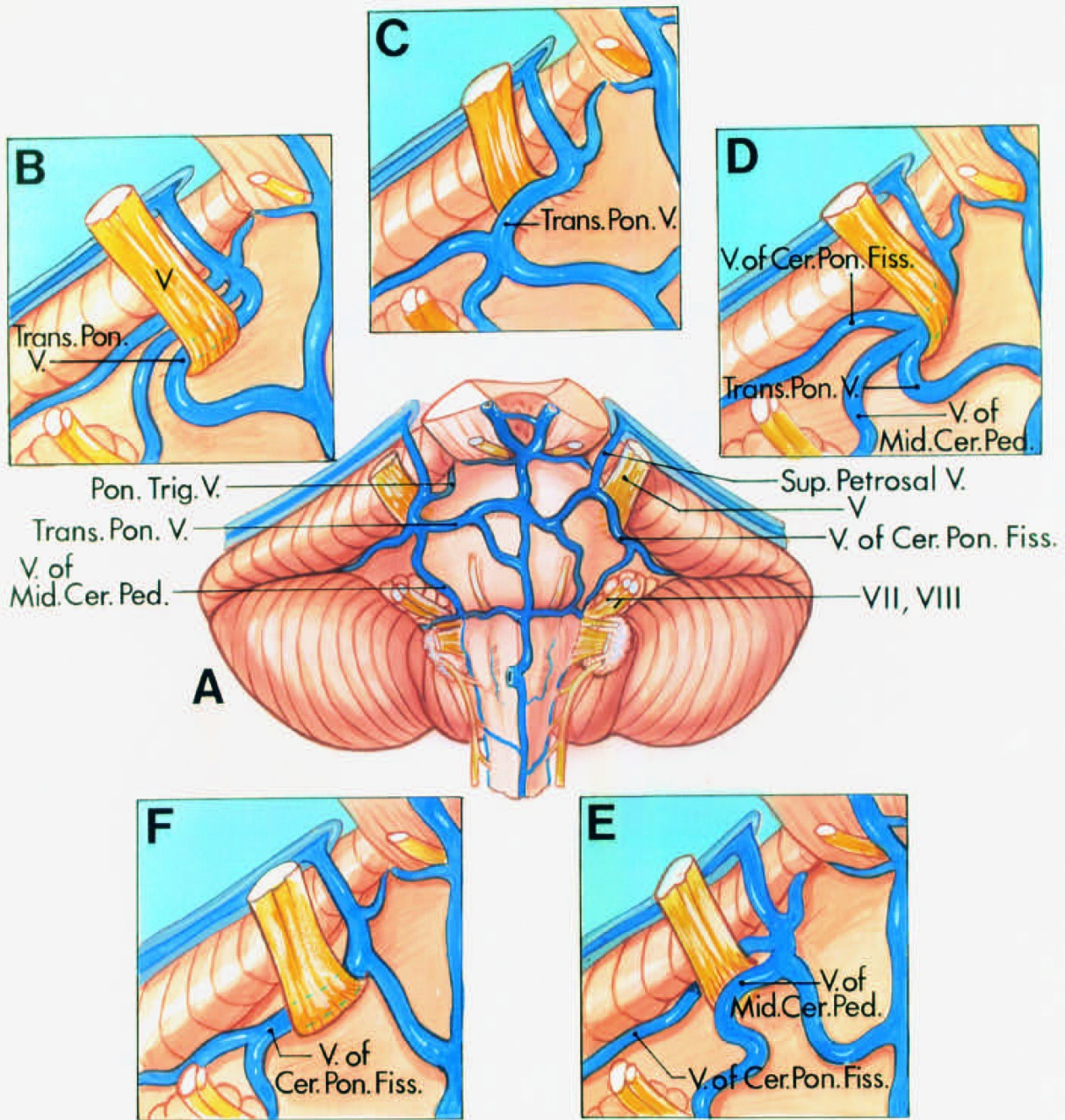


FIGURE 4.13. Sites of venous compression of the trigeminal nerve. A, central diagram. Anterior view. The veins that commonly compress the trigeminal nerve are tributaries of the superior petrosal vein. The tributaries that converge on and may compress the nerve are the transverse pontine and pontotrigeminal veins and the veins of the cerebellopontine fissure and middle cerebellar peduncle. The transverse pontine veins course transversely across the pons. The vein of the middle

cerebellar peduncle arises in the region of the facial and vestibulocochlear nerves and ascends on the pons. The vein of the cerebellopontine fissure arises along the cleft between the pons and the cerebellum and ascends behind the trigeminal nerve. The pontotrigeminal vein arises on the upper pons and passes above the trigeminal nerve. B, a transverse pontine vein compresses the lateral side of the nerve and joins the veins of the middle cerebellar peduncle and cerebellopontine fissure to empty into a superior petrosal vein. C, the medial side of the nerve is compressed by a tortuous transverse pontine vein. D, the lateral side of the nerve is compressed by the junction of the transverse pontine vein with the veins of the middle cerebellar peduncle and the cerebellopontine fissure. E, the nerve is compressed on the medial side by the vein of the middle cerebellar peduncle and on the lateral side by the vein of the cerebellopontine fissure. F, the lateral side of the nerve is compressed by the vein of the cerebellopontine fissure. (From, Rhoton AL Jr: Microsurgical anatomy of decompression operations on the trigeminal nerve, in Rovit RL, Murali R, Jannetta PJ (eds): Trigeminal Neuralgia. Baltimore, Williams & Wilkins, 1990, pp 165–200 [34].) Cer., cerebellar; Cer. Pon., cerebellopontine; Fiss., fissure; Mid., middle; Ped., peduncle; Pon., pontine; Sup., superior; Trans., transverse; Trig., trigeminal; V., vein.

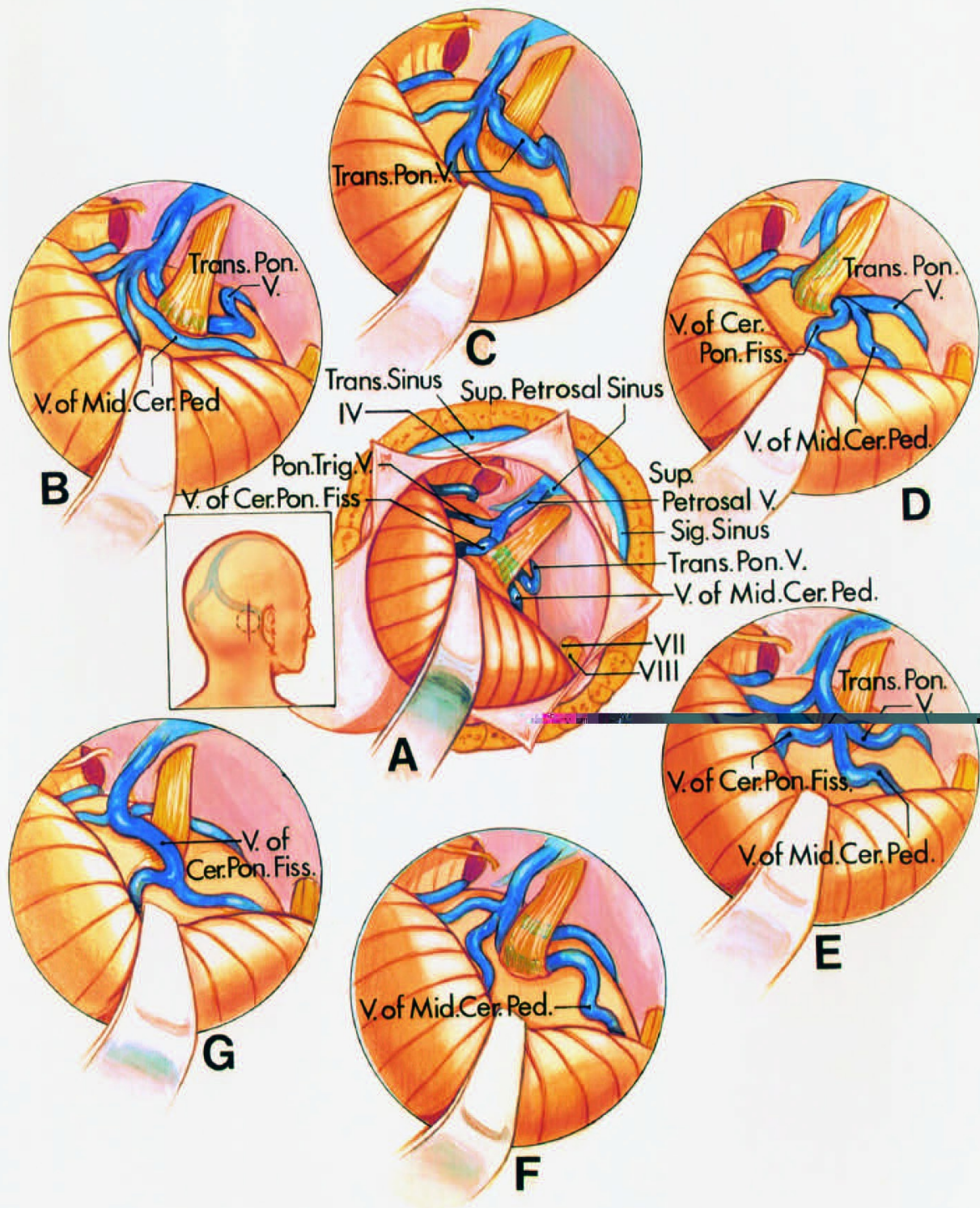
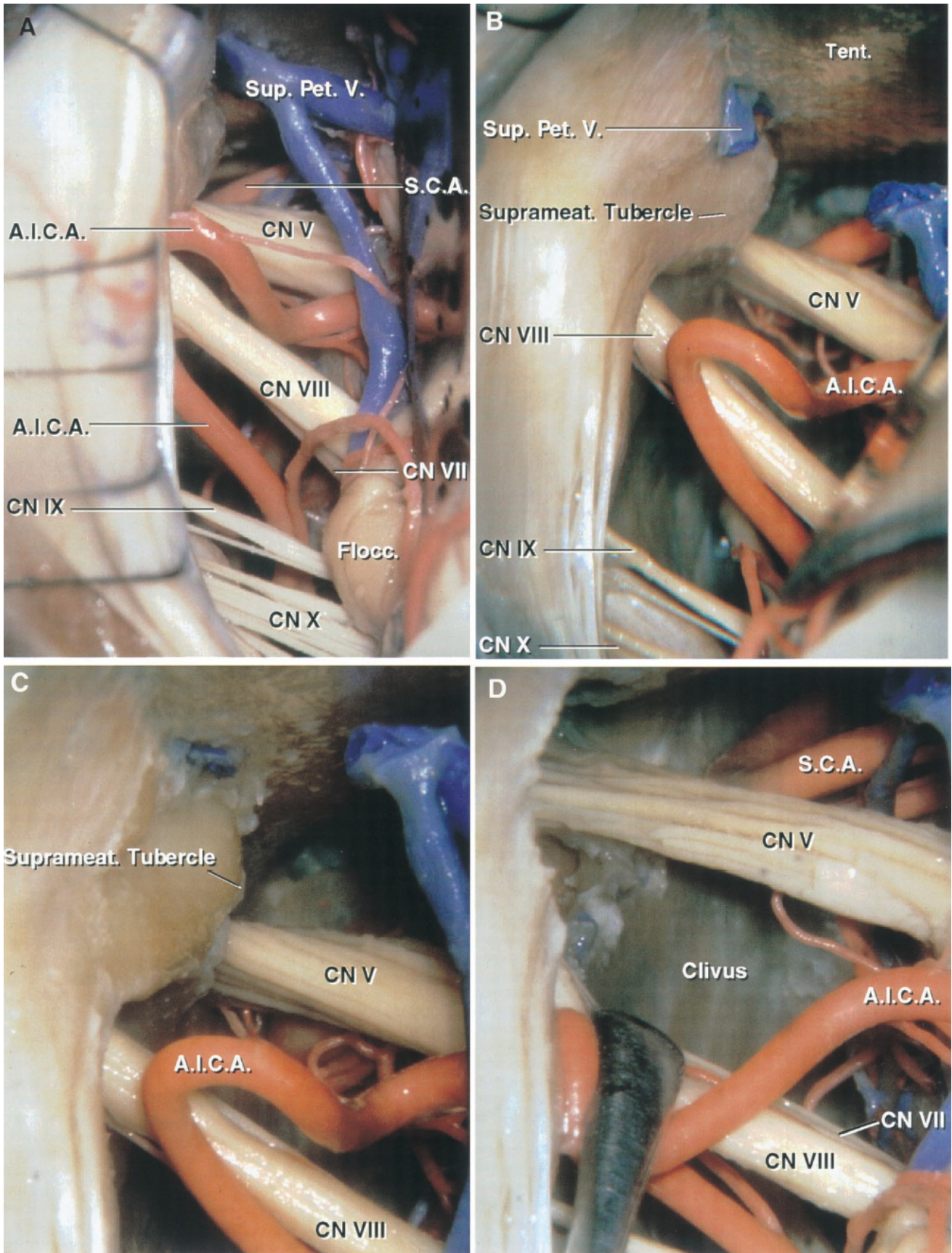


FIGURE 4.14. Sites of venous compression of the trigeminal nerve as seen through a retrosigmoid craniotomy. A, the insert shows the site of the scalp incision (solid line) and the craniotomy (interrupted line). The cerebellum has been elevated to expose the junction of the trigeminal nerve with the pons. The superior petrosal veins empty into the superior petrosal sinus. The trochlear nerve is at the superior margin and the facial and vestibulocochlear nerves are at the lower margin of the exposure.

The craniotomy exposes the junction of the sigmoid and transverse sinuses. The trigeminal nerve is compressed by the junction of a transverse pontine vein and the vein of the middle cerebellar peduncle with the superior petrosal vein. The vein of the cerebellopontine fissure ascends behind the nerve and the pontotrigeminal vein passes above the nerve. B, the trigeminal nerve is compressed on its medial side by a transverse pontine vein and on its lateral side by the vein of the middle cerebellar peduncle. C, the lateral side of the nerve is compressed by a transverse pontine vein. D, the medial side of the nerve is compressed by the junction of a transverse pontine vein with the veins of the middle cerebellar peduncle and cerebellopontine fissure. E, the lateral side of the nerve is compressed by the junction of the transverse pontine vein with the veins of the middle cerebellar peduncle and cerebellopontine fissure. F, the medial side of the nerve is compressed by the vein of the middle cerebellar peduncle. G, the lateral side of the nerve is compressed by the vein of the cerebellopontine fissure. (From, Rhoton AL Jr: Microsurgical anatomy of decompression operations on the trigeminal nerve, in Rovit RL, Murali R, Jannetta PJ (eds): Trigeminal Neuralgia. Baltimore, Williams & Wilkins, 1990, pp 165–200 [34].) Cer., cerebellar; Cer. Pon., cerebellopontine; Fiss., fissure; Mid., middle; Ped., peduncle; Pon., pontine; Sig., sigmoid; Sup., superior; Trans., transverse; Trig., trigeminal; V., vein.

Middle Neurovascular Complex

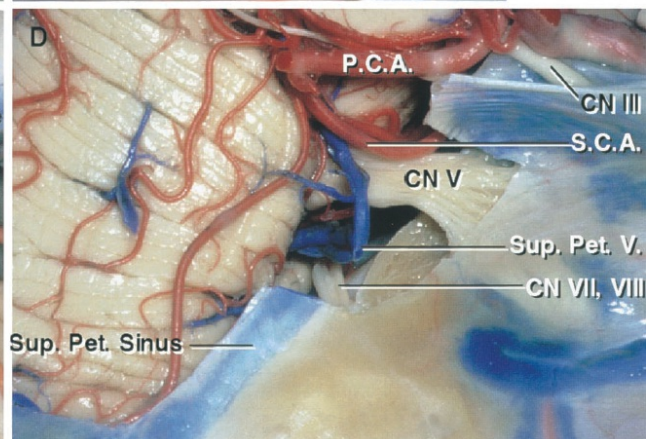
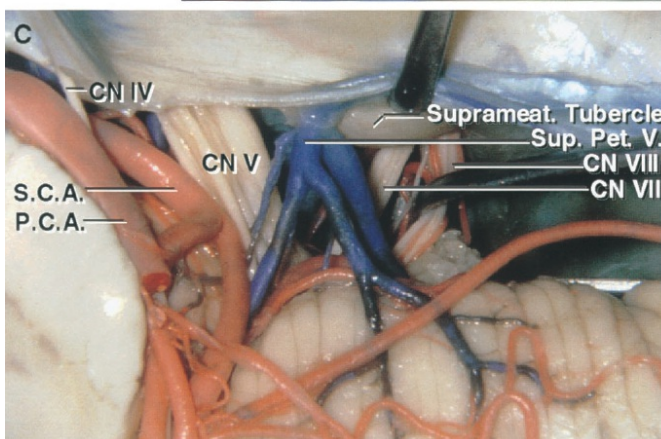
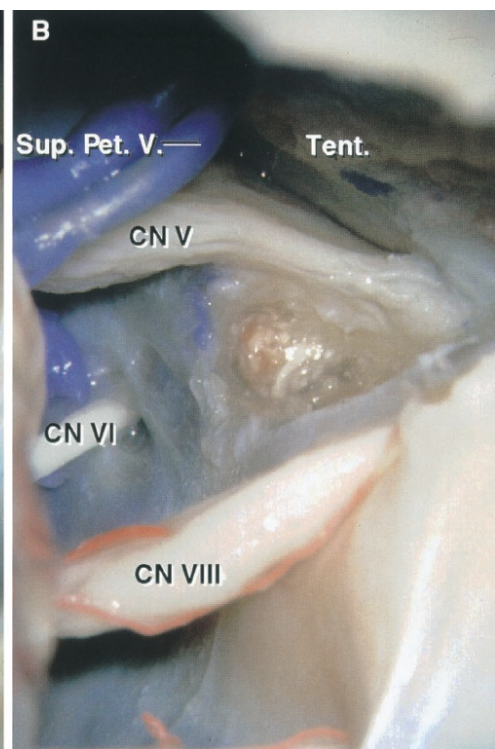
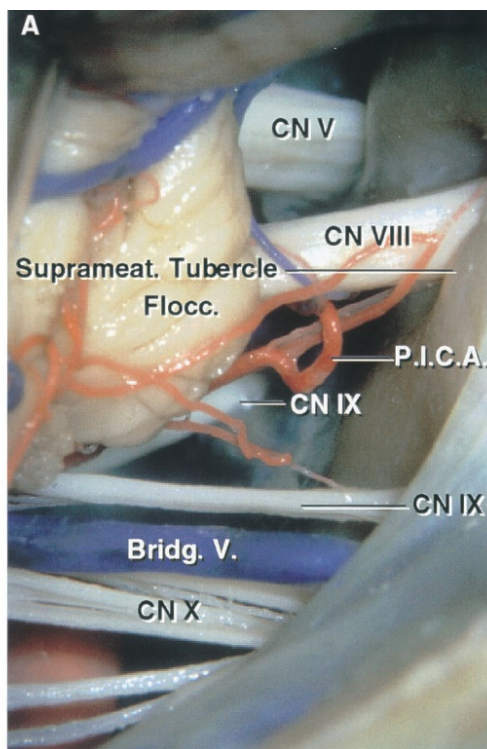
The middle complex includes the AICA, pons, middle cerebellar peduncle, cerebellopontine fissure, petrosal surface of the cerebellum, and the abducens, facial, and vestibulocochlear nerves (Figs. 4.1 and 4.17). The AICA arises at the pontine level and courses in relationship to the abducens, facial, and vestibulocochlear nerves to reach the surface of the middle cerebellar peduncle, where it courses along the cerebellopontine fissure and terminates by supplying the petrosal surface of the cerebellum. Operations directed to the middle complex are for the removal of acoustic neuromas and other tumors and for the relief of hemifacial spasm. The considerations related to acoustic neuromas will be dealt with first.



[Click here](#) to view the interactive module and related content for this image.

FIGURE 4.15. Suprameatal variant of the retrosigmoid approach. A, the

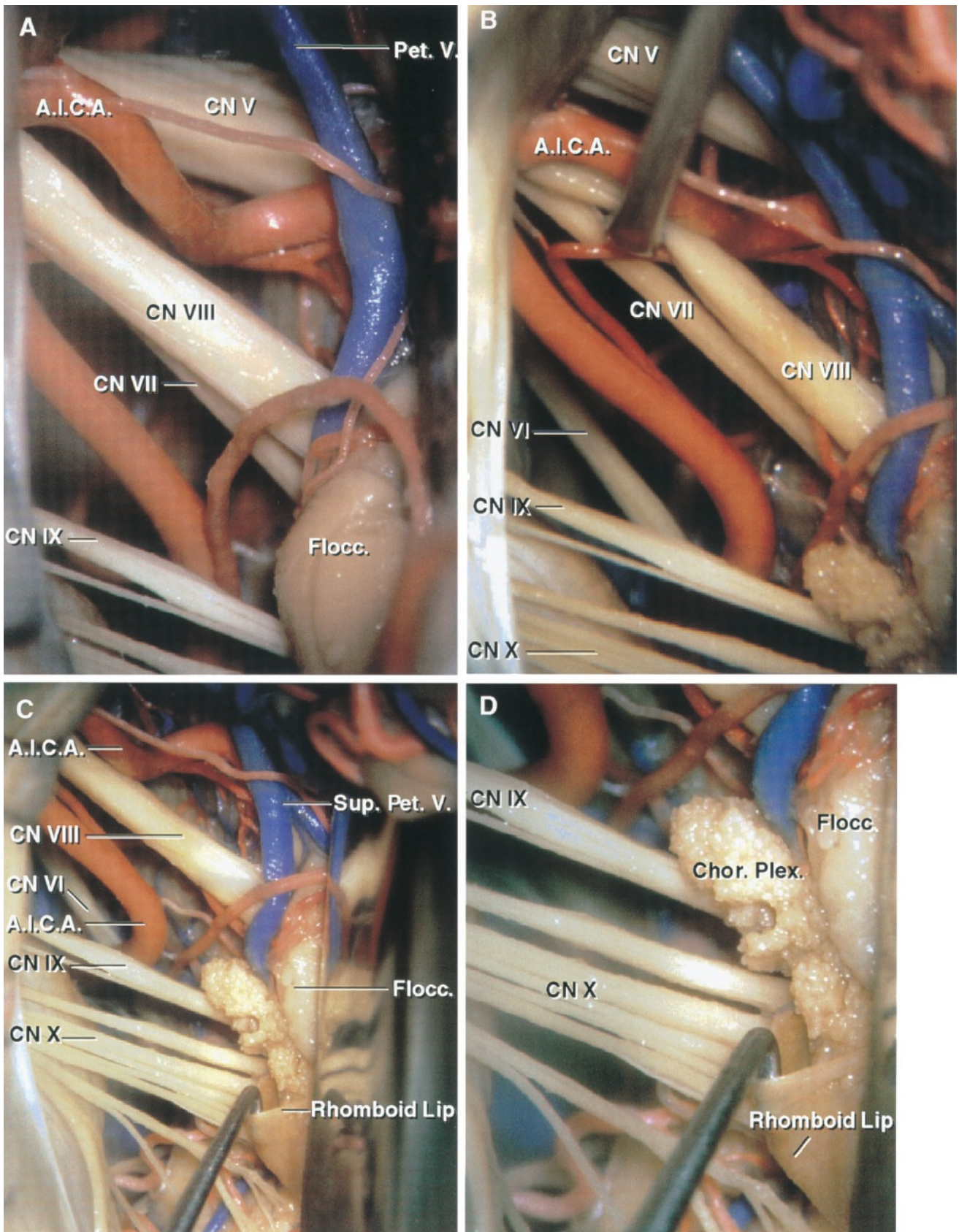
cerebellum has been elevated to expose the nerves in the cerebellopontine angle. A large petrosal vein blocks access to the suprameatal area. B, the superior petrosal vein has been divided to expose the suprameatal tubercle located above the porus of the internal acoustic meatus and lateral to the trigeminal nerve. C, the dura over the suprameatal tubercle has been removed in preparation for drilling. D, removing the suprameatal bone, including the tubercle, extends the exposure along the posterior trigeminal root by approximately 1 cm and increases access to the front of the brainstem and clivus. A.I.C.A., anteroinferior cerebellar artery; CN, cranial nerve; Flocc., flocculus; Pet., petrosal; S.C.A., superior cerebellar artery; Sup., superior; Suprameat., suprameatal; V., vein.





[Click here](#) to view the interactive module and related content for this image.

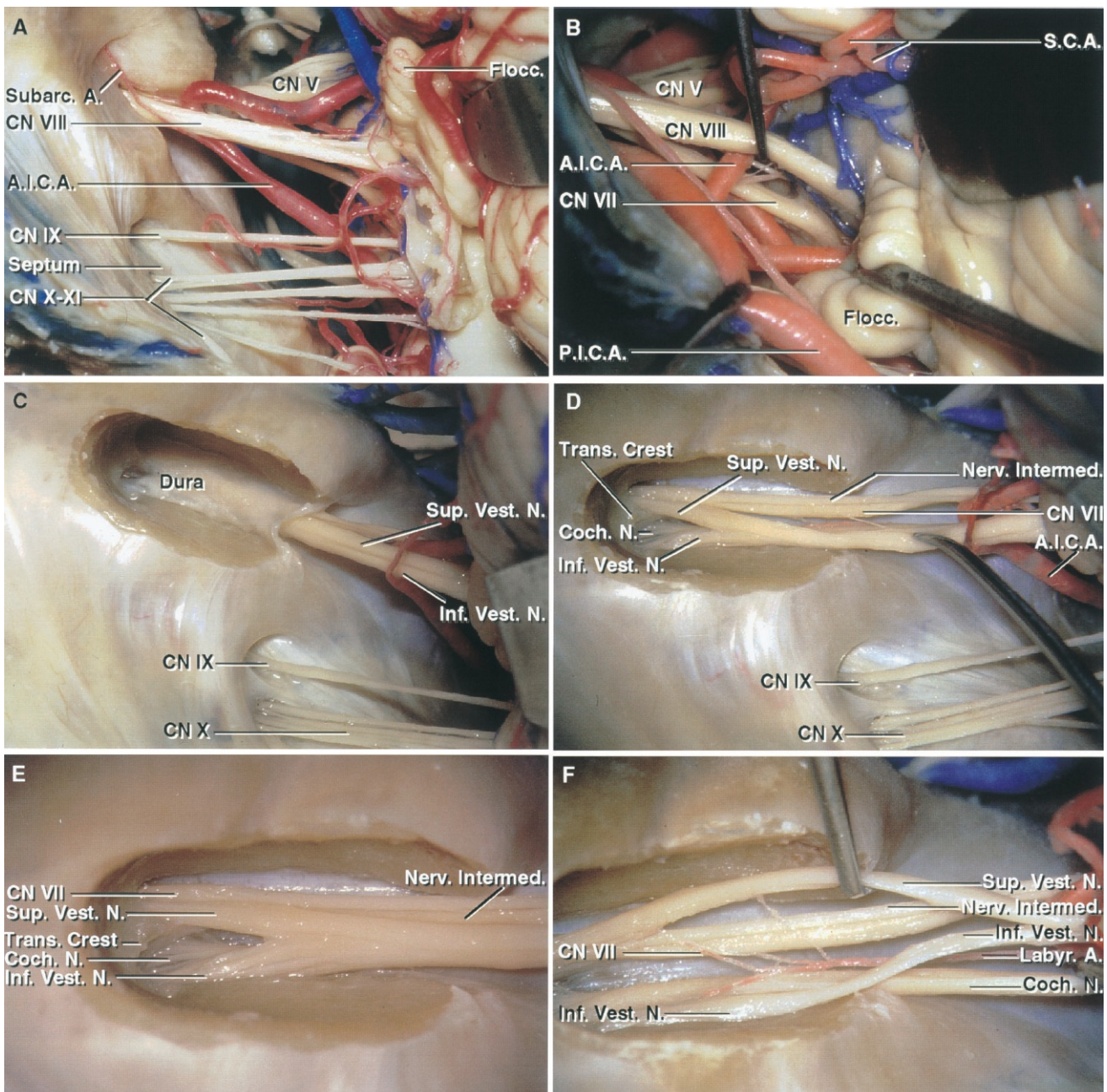
FIGURE 4.16. Suprameatal approach to the posterior part of Meckel's cave. A, right cerebellopontine angle. The suprameatal tubercle is located above the porus of the internal meatus. A large inferior petrosal vein passes behind the vagus nerve. B, the suprameatal tubercle has been removed and the dura extending anteriorly toward Meckel's cave has been opened to provide 1 cm of additional exposure along the posterior trigeminal root. In addition, access to the side of the clivus is improved. C, superior view of the suprameatal tubercle. The tubercle is located lateral to the trigeminal nerve, below the superior petrosal vein, and above the internal acoustic meatus and the facial and vestibulocochlear nerves. D, lateral view after removal of the suprameatal tubercle and the segment of the superior petrosal sinus passing above the porus of Meckel's cave. This improves the length of the posterior trigeminal root exposed by 8 to 10 mm, compared with the exposure before drilling the tubercle. Bridg., bridging; CN, cranial nerve; Flocc., flocculus; P.C.A., posterior cerebral artery; Pet., petrosal; P.I.C.A., posteroinferior cerebellar artery; S.C.A., superior cerebellar artery; Sup., superior; Suprameat., suprameatal; Tent., tentorium; V., vein.



[Click here](#) to view the interactive module and related content for this image.

FIGURE 4.17. Left retrosigmoid exposure. A, the cerebellum has been elevated. A large AICA loops into the porus of the internal meatus. The

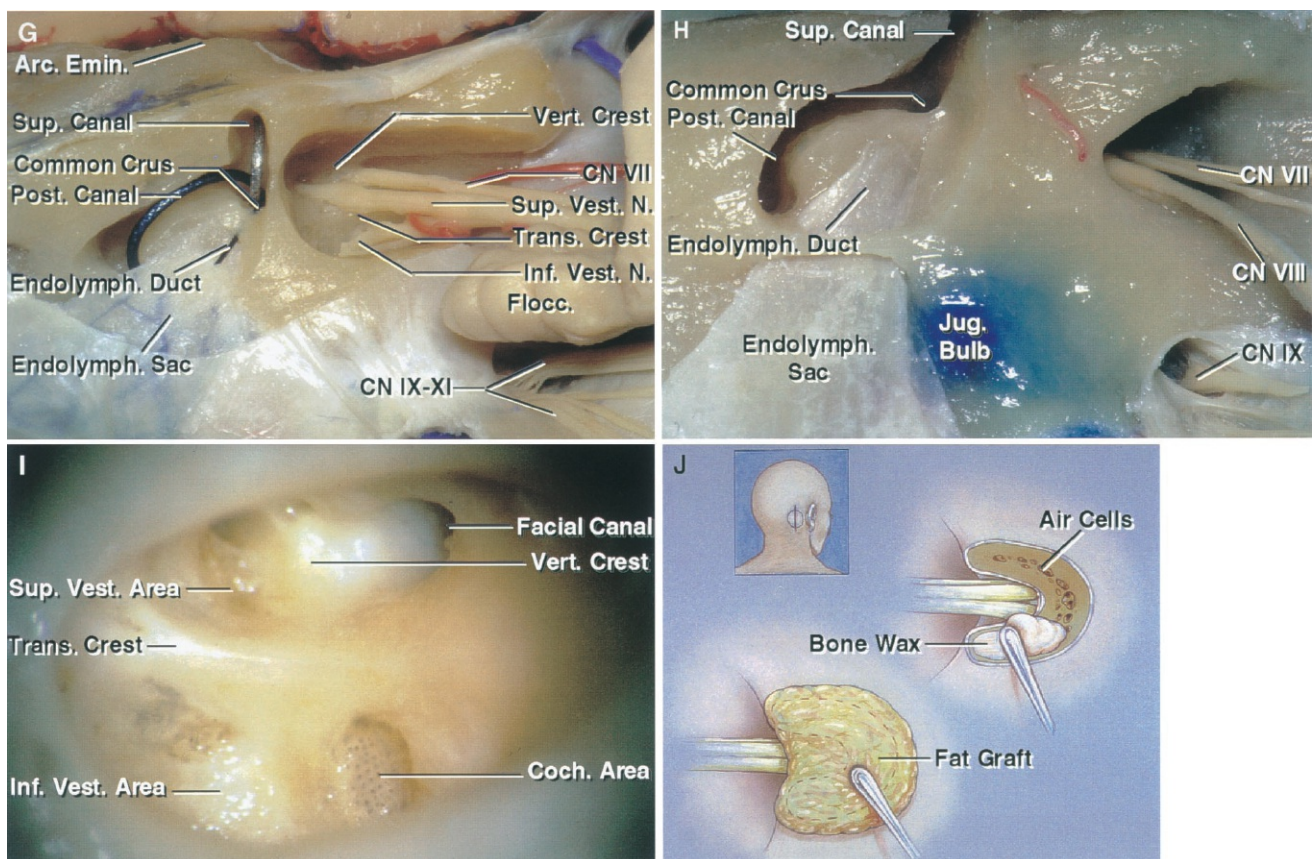
junction of the facial nerve with the brainstem is located below and slightly in front of the vestibulocochlear nerve. B, the vestibulocochlear nerve has been elevated to provide additional exposure of the facial nerve. C, choroid plexus protrudes from the foramen of Luschka into the cerebellopontine angle behind the glossopharyngeal and vagus nerves. A nerve hook has been placed inside the rhomboid lip, a pouch of neural tissue attached along the anterior margin of the lateral recess and extending laterally behind the glossopharyngeal and vagus nerves. D, enlarged view of the rhomboid lip. A.I.C.A., anteroinferior cerebellar artery; Chor. Plex., choroid plexus; CN, cranial nerve; Flocc., flocculus; Pet., petrosal; Sup., superior; V., vein.





[Click here](#) to view the interactive module and related content for this image.

FIGURE 4.18. A–F. Left cerebellopontine angle. A, the AICA passes between the facial and vestibulocochlear nerves. A dural septum separates the glossopharyngeal and vagus nerves at the jugular foramen. **B,** the vestibulocochlear nerve and the flocculus have been elevated to expose the junction of the facial nerve with the brainstem. In the retrosigmoid approach, the facial nerve junction with the brainstem can be exposed below the vestibulocochlear nerve. **C,** the posterior wall of the internal acoustic meatus has been removed. The cleavage plane between the superior and inferior vestibular nerves is especially prominent. **D,** the dura lining the internal acoustic meatus has been opened. The transverse crest separates the superior vestibular and facial nerves above from the inferior vestibular and cochlear nerves below. **E,** enlarged view of the nerves within the meatus. The cochlear nerve is partially hidden anterior to the inferior vestibular nerve. **F,** the cleavage plane between the superior and inferior vestibular and cochlear nerves has been started laterally and extended medially to expose the individual nerve bundles. A., artery; A.I.C.A., anteroinferior cerebellar artery; Arc., arcuate; CN, cranial nerve; Coch., cochlear; Emin., eminence; Endolymph., endolymphatic; Flocc., flocculus; Inf., inferior; Intermed., intermedium; Jug., jugular; Labyr., labyrinth; N., nerve; Nerv., nervus; P.I.C.A., posteroinferior cerebellar artery; Post., posterior; S.C.A., superior cerebellar artery; Subarc., subarcuate; Sup., superior; Trans., transverse; Vert., vertebral; Vest., vestibular.



[Click here](#) to view the interactive module and related content for this image.

FIGURE 4.18. G–J. Left cerebellopontine angle. G, the vertical and transverse crest are exposed at the meatal fundus. The common crus and adjacent part of the superior and posterior canals have been exposed. The endolymphatic duct and sac are situated inferolateral to the internal acoustic meatus. H, another dissection showing the relationships of the junction of the posterior and superior canals and common crus to the meatus. The endolymphatic duct extends downward and backward from the vestibule and opens into the endolymphatic sac, which sits under the dura in the area below and lateral to the meatus. The jugular bulb can be seen through the bone medial to the endolymphatic sac. I, fundus of the left internal acoustic meatus. The transverse crest separates the superior vestibular area and facial canal above from the inferior vestibular and cochlear areas below. The vertical crest separates the superior vestibular area from the entrance into the facial canal. The multiple cochlear nerve filaments penetrating the tiny openings in the lamina cribrosa at the meatal fundus can easily be torn with traction on the nerve from lateral to medial, therefore, we try to direct the strokes of dissection from

medial to lateral when there is an opportunity to preserve hearing. J, closure after removing the posterior wall of the internal acoustic meatus. Bone wax on a microdissector is carefully placed into open air cells in the posterior meatal lip and then a pledget of crushed subcutaneous abdominal fat is laid over the drilled meatal area. This has prevented cerebrospinal fluid leaks after removal of the posterior wall of the internal acoustic meatus in more than 200 consecutive operations for acoustic neuroma by the author.

Anatomy of Acoustic Neuromas

Acoustic neuromas, as they expand, may involve a majority of the cranial nerves, cerebellar arteries, and parts of the brainstem. On the lateral side, in the meatus, they commonly expand by enlarging the meatus, but infrequently erode into the vestibule and cochlea. On the medial side, they compress the pons, medulla, and cerebellum. An understanding of microsurgical anatomy is especially important in preserving the facial and adjacent cranial nerves, which are the neural structures at greatest risk during acoustic neuroma removal. A widely accepted operative precept is that a nerve involved by a tumor should be identified proximal or distal to the tumor, where its displacement and distortion is the least, before the tumor is removed from the involved segment of the nerve. Considerable attention has been directed to the early identification of the facial nerve distal to the tumor at the lateral part of the internal acoustic canal. Less attention has been directed to identification at the brainstem on the medial side of the tumor. These anatomic considerations are divided into sections dealing with the relationships at the lateral end of the tumor in the meatus and those on the medial end of the tumor at the brainstem, which follow in this chapter (33, 35, 37).

Meatal Relationships

The nerves in the lateral part of the internal acoustic meatus are the facial, cochlear, and inferior and superior vestibular nerves (Figs. 4.1 and 4.18) (30, 38). The position of the nerves is most constant in the lateral portion of the meatus, which is divided into a superior and an inferior portion by a horizontal ridge, called either the transverse or falciform crest. The facial

and the superior vestibular nerves are superior to the crest.

The facial nerve is anterior to the superior vestibular nerve and is separated from it at the lateral end of the meatus by a vertical ridge of bone, called the vertical crest. The vertical crest is also called “Bill’s bar” in recognition of William House’s role in focusing on the importance of this crest in identifying the facial nerve in the lateral end of the canal (16). The cochlear and inferior vestibular nerves run below the transverse crest with the cochlear nerve located anteriorly. Thus, the lateral meatus can be considered to be divided into four portions, with the facial nerve being anterosuperior, the cochlear nerve anteroinferior, the superior vestibular nerve posteroinferior. The anatomy of the region offers the opportunity for three basic approaches to the tumor in the meatus and cerebellopontine angle. One is directed through the middle cranial fossa and the roof of the meatus. Another is directed through the labyrinth and posterior surface of the temporal bone. The third is directed through the posterior cranial fossa and posterior meatal lip. The translabyrinthine the temporal bone.

Retrosigmoid approach. The retrosigmoid approach to the meatus is directed through a vertical scalp incision that crosses the asterion. A burr hole is placed below the asterion and a craniotomy is performed exposing the lower margin of the transverse sinus superiorly, the posterior margin of the sigmoid sinus laterally, and the inferior portion of the squamous part of the occipital bone inferiorly. The intradural exposure is directed down the plane between the posterior face of the temporal bone and the petrosal cerebellar surface (Figs. 4.1, 4.17, and 4.18) (35–37). The petrosal cerebellar surface usually relaxes away from the temporal bone after the arachnoid membrane over the cisterna magna has been opened and the cerebrospinal fluid allowed to escape. When removing the posterior meatal wall, it often is necessary to sacrifice the subarcuate artery because it passes through the dura on the posterior meatal wall to reach the subarcuate fossa (Figs. 4.1 and 4.18) (25). This artery usually has a sufficiently long stem that its obliteration does not risk damage to the AICA from which it arises. In a few cases, however, the subarcuate artery and the segment of the AICA from which it arises will be incorporated into

the dura covering the subarcuate fossa. In this case, the dura and the artery will have to be separated together from the posterior meatal lip wall in preparation for opening the meatus.

The posterior semicircular canal and its common crus with the superior canal, both of which are situated just lateral to the posterior meatal lip, should be preserved when removing the posterior meatal wall if there is the possibility of preserving hearing, since hearing may be lost if damage occurs (Fig. 4.18). Care also is required to avoid injury to the vestibular aqueduct, which is situated inferolateral to the meatal lip, and the endolymphatic sac, which expands under the dura on the posterior surface of the temporal bone inferolateral to the meatal porus (Fig. 4.18). The endolymphatic sac may be entered in removing the dura from the posterior meatal lip. There is little danger of encountering the cochlear canaliculus, which has a more medial course below the internal auditory canal. An unusually high projection of the jugular bulb into the posterior wall of the meatus presents an anomaly that may block access to the posterior meatal lip. Mastoid air cells commonly are encountered in the posterior meatal lip.

After removing the posterior wall of the meatus, the dura lining the meatus is opened to expose its contents (Figs. 4.18 and 4.19). The facial nerve is identified near the origin of the facial canal at the anterosuperior quadrant of the meatus rather than in a more medial location where the direction of displacement is variable. If the tumor extends into the vestibule, the latter can easily be exposed by drilling and removing the posterior wall of the vestibule lateral to the meatal fundus. The strokes of the fine dissecting instruments along the vestibulocochlear nerve should be directed from medial to lateral rather than from lateral to medial, because traction medially may tear the tiny filaments of the cochlear nerve at the site where these filaments penetrate the lateral end of the meatus to enter the modiolus of the cochlea (Fig. 4.18).

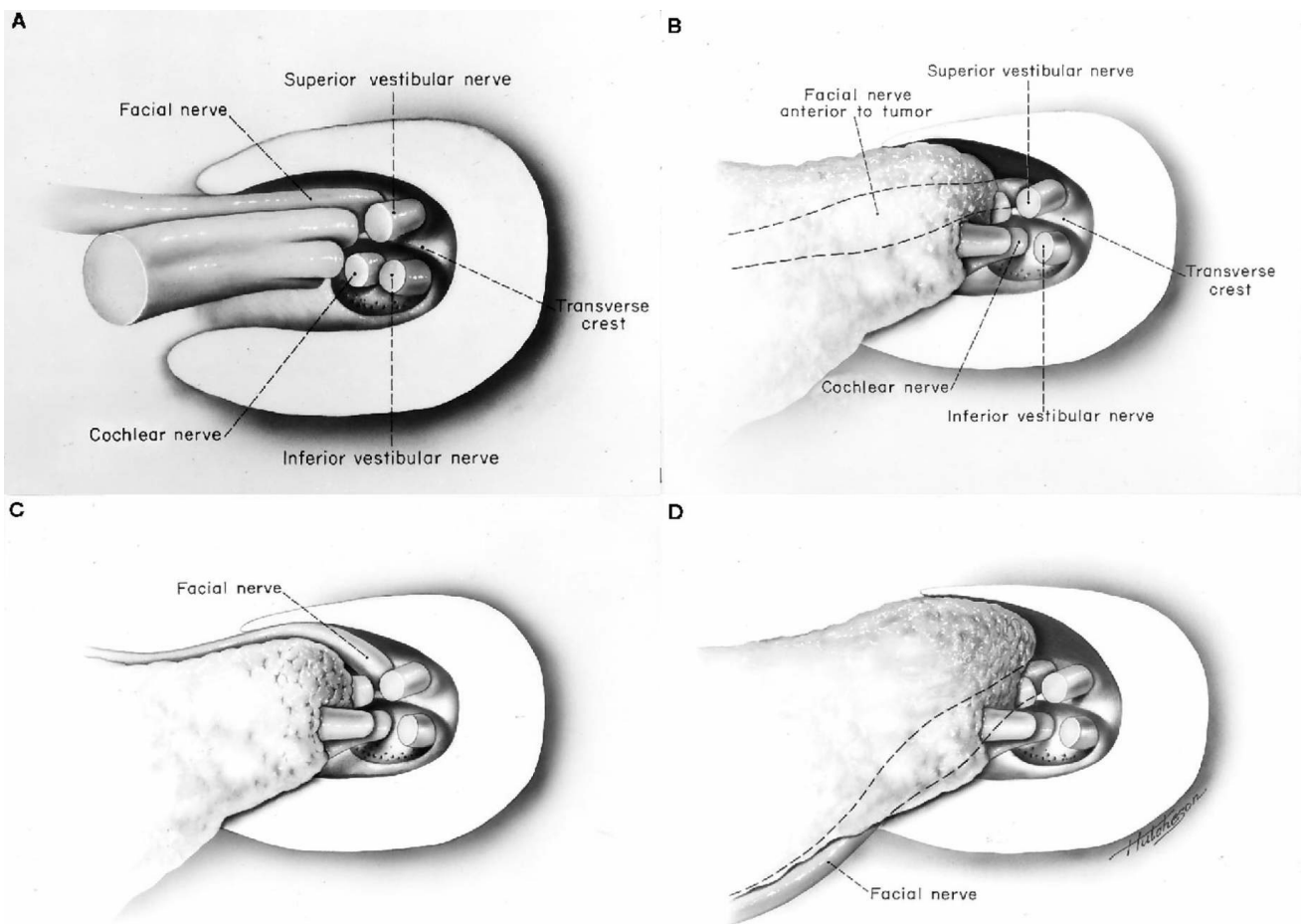


FIGURE 4.19. View of right internal acoustic meatus with the posterior lip removed to show variable direction of facial nerve displacement by acoustic neuroma. **A**, normal neural relationships with the eighth nerve dividing into its three parts in the lateral meatus. The facial and superior vestibular nerves are above the transverse crest and the cochlear and inferior vestibular nerves are below. The facial nerve occupies the anterosuperior quadrant of the lateral meatus. **B**, the facial nerve is displaced directly anteriorly. This is a frequent direction of displacement with acoustic neuroma. **C**, another frequent direction of displacement of the facial nerve is anterior and superior. **D**, the facial nerve is displaced anteriorly and inferiorly by tumor, which erodes the superior wall of the meatus above the nerves and grows into the area above the nerves, displacing them inferiorly. (From, Rhoton AL Jr: *Microsurgery of the Internal Acoustic Meatus*. *Surg Neurol* 2:311–318, 1974 [32].)

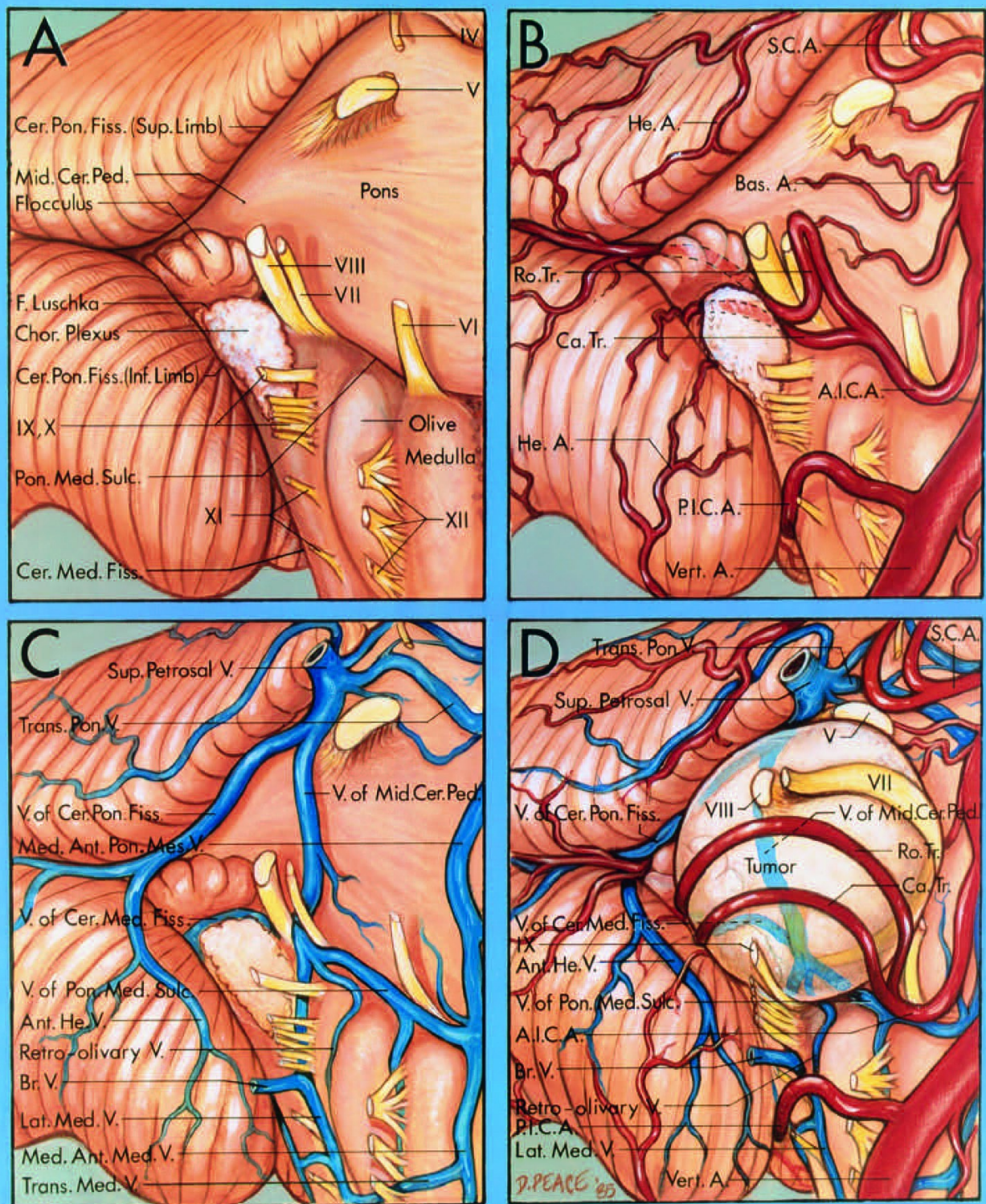


FIGURE 4.20. Neurovascular relationships on the brainstem side of an acoustic neuroma. Anterolateral view of the right cerebellopontine angle. A, neural relationships. The facial and vestibulocochlear nerves arise from the brainstem near the lateral end of the pontomedullary sulcus, anterosuperior to the choroid plexus protruding from the foramen of Luschka, anterior to the flocculus, rostral to a line drawn along the junction of the rootlets of the glossopharyngeal, vagus, and accessory

nerves with the brainstem, and slightly posterior to the rostral pole of the inferior olive. The cerebellopontine fissure formed by the cerebellum wrapping around the lateral side of the pons and middle cerebellar peduncle has a superior limb that passes above the trigeminal nerve and an inferior limb that extends below the foramen of Luschka. The cerebellomedullary fissure, which extends superiorly between the medulla and cerebellum, communicates in the region of the foramen of Luschka with the cerebellopontine fissure.

B, arterial relationships. The AICA arises from the basilar artery and divides into rostral and caudal trunks. The rostral trunk, which is usually the larger of the two trunks, courses below the facial and vestibulocochlear nerves, and then above the flocculus to reach the surface of the middle cerebellar peduncle. The PICA arises from the vertebral artery and passes first between the hypoglossal rootlets, and then between the vagus and accessory nerves on its way to the cerebellar hemisphere. The SCA passes above the trigeminal nerve. The cerebellar arteries give rise to hemispheric branches.

C, venous relationships. The veins that converge on the junction of the facial and vestibulocochlear nerves with the brainstem are the veins of the pontomedullary sulcus, cerebellomedullary fissure, middle cerebellar peduncle, and the retro-olivary and lateral medullary veins. The vein of the cerebellopontine fissure, which passes above the flocculus on the middle cerebellar peduncle, is formed by the anterior hemispheric veins that arise on the cerebellum. Transverse pontine and transverse medullary veins cross the pons and medulla. The median anterior medullary and median anterior pontomesencephalic veins ascend on the anterior surface of the medulla and pons. The veins of the middle cerebellar peduncle and the cerebellopontine fissure and a transverse pontine vein join to form a superior petrosal vein, which empties into the superior petrosal sinus. A bridging vein passes below the vagal rootlets toward the jugular foramen.

D, neurovascular relationships of an acoustic neuroma. The tumor arises from the vestibulocochlear nerve and displaces the facial nerve anteriorly, the trigeminal nerve superiorly, and the vagus and glossopharyngeal nerves inferiorly. The facial nerve, even though displaced by the tumor, enters the brainstem along the lateral margin of the pontomedullary sulcus, rostral to the glossopharyngeal and

vagus nerves, anterior to the flocculus, and rostral to the choroid plexus protruding from the foramen of Luschka. The rostral trunk of the AICA, after passing below the tumor, returns to the surface of the middle cerebellar peduncle above the flocculus. The veins displaced around the medial side of the tumor are the veins of the middle cerebellar peduncle, cerebellomedullary fissure, cerebellopontine fissure, and pontomedullary sulcus, and the retro-olivary and lateral medullary veins. (From, Rhoton AL Jr: Microsurgical anatomy of the brainstem surface facing an acoustic neuroma. Surg Neurol 25:326–339, 1986 [33].) A., artery; A.I.C.A., anteroinferior cerebellar artery; Ant., anterior; Bas., basilar; Br., bridging; Ca., caudal; Cer., cerebellar; Cer. Pon., cerebellopontine; Chor., choroid; F., foramen; Fiss., fissure; Hem., hemispheric; Lat., lateral; Med., medial, medullary; Mid., middle; Ped., peduncle; P.I.C.A., posteroinferior cerebellar artery; Pon., pontine; Pon. Med., pontomedullary; Pon. Mes., pontomesencephalic; Ro., rostral; S.C.A., superior cerebellar artery; Sulc., sulcus; Sup., superior; Tr., trunk; Trans., transverse; V., vein; Vert., vertebral.

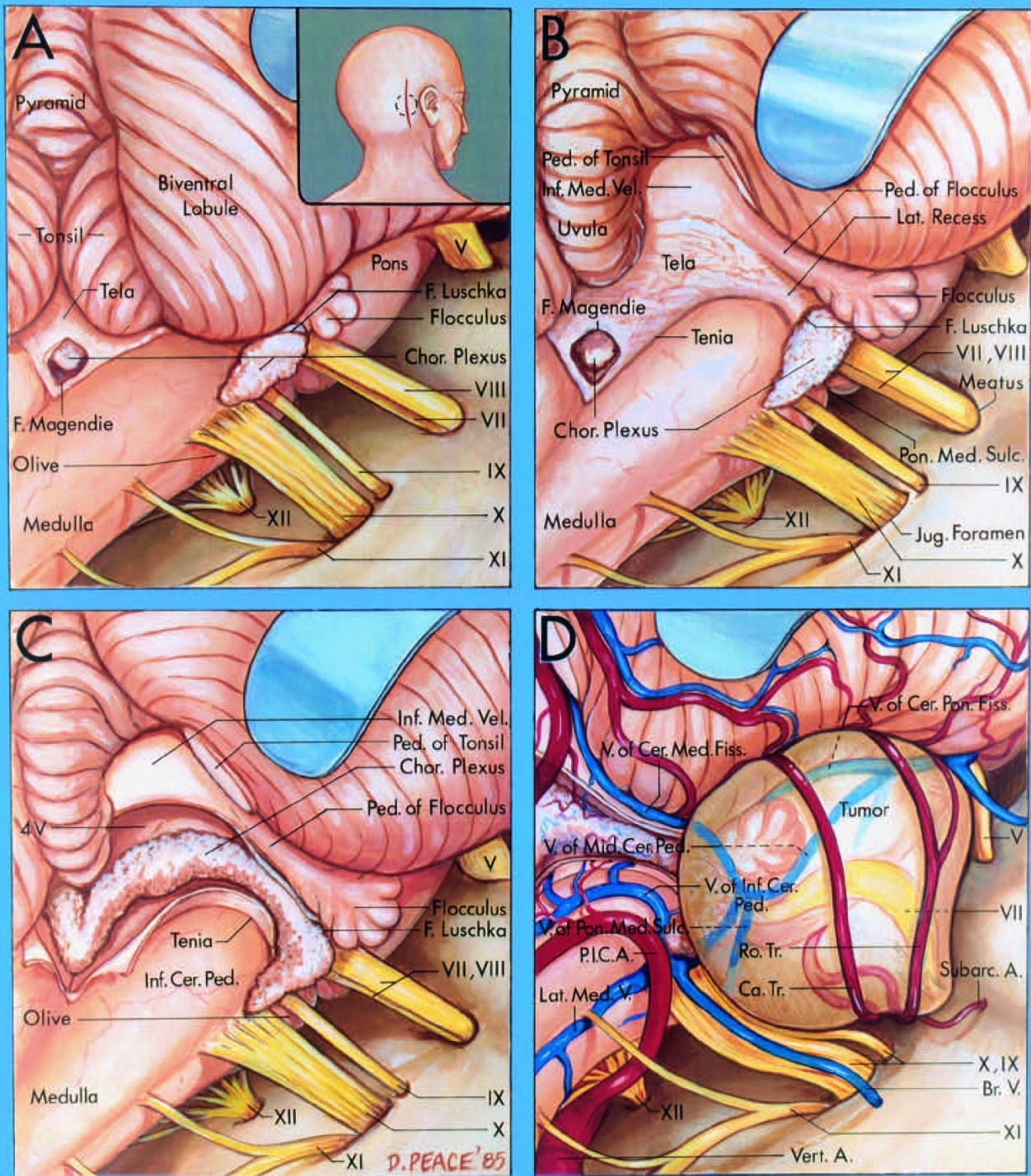


FIGURE 4.21. Relationship of the foramen of Luschka and the lateral recess of the fourth ventricle to the junction of the facial and vestibulocochlear nerves with the brainstem, as seen through a suboccipital craniotomy. **A**, the orientation, skin incision (solid line), and craniotomy (interrupted line) are shown in the insert. The foramen of Luschka opens into the cerebellopontine angle behind the glossopharyngeal and vagus nerves. The choroid plexus protrudes from

the foramen of Luschka, slightly below and behind the facial and vestibulocochlear nerves, and behind to the glossopharyngeal and vagus nerves. The flocculus protrudes into the cerebellopontine angle above the foramen of Luschka. The accessory nerve arises below the vagus nerve. The hypoglossal rootlets arise ventral to the olive. The trigeminal nerve crosses in the upper part of the exposure. B, the right cerebellar tonsil has been removed by dividing the tonsillar peduncle to show the relationship of the lateral recess to the facial and vestibulocochlear nerves. The flocculus and choroid plexus protrude in the cerebellopontine angle behind the junction of the facial and vestibulocochlear nerves with the brainstem. The inferior medullary velum stretches from the lateral side of the vermis to the flocculus and is all that remains of the connection between the flocculus and the nodulus, which form the flocculonodular lobe of the cerebellum. The inferior medullary velum stretches laterally to form the peduncle of the flocculus. The tela choroidea forms the caudal part of the roof of the fourth ventricle and has the choroid plexus attached to its inner surface. The facial and vestibulocochlear nerves enter the brainstem at the lateral end of the pontomedullary sulcus. C, the tela choroidea has been opened, but the choroid plexus, which arises on the inner surface of the tela in the fourth ventricle, has been preserved. The fringelike choroid plexus extends through the foramen of Luschka slightly below and behind the junction of the facial and vestibulocochlear nerves with the brainstem. The inferior cerebellar peduncle ascends on the dorsolateral margin of the medulla. D, relationships of an acoustic neuroma. The facial nerve is displaced anteriorly and superiorly in the cerebellopontine angle and enters the brainstem at the lateral end of the pontomedullary sulcus, anterosuperior to the choroid plexus protruding from the foramen of Luschka, and near where the flocculus is attached along the margin of the lateral recess. The tumor displaces the trigeminal nerve upward and the glossopharyngeal and vagus nerves downward. The AICA gives rise to a subarcuate artery, which enters the subarcuate fossa in the posterior wall of the internal acoustic meatus and bifurcates into a rostral and a caudal trunk. The rostral trunk courses above the flocculus to reach the surface of the middle cerebellar peduncle. (From, Rhoton AL Jr: Microsurgical

anatomy of the brainstem surface facing an acoustic neuroma. Surg Neurol 25:326–339, 1986 [33].) Br., bridging; Ca., caudal; Cer. Med., cerebellomedullary; Cer. Pon., cerebellopontine; Chor. choroid; F., foramen; Fiss., fissure; Inf., inferior; Jug., jugular; Lat., lateral; Med., medial, medullary; Mid., middle; Ped., peduncle; P.I.C.A., posteroinferior cerebellar artery; Pon. Med., pontomedullary; Ro., rostral; Subarc., subarcuate; Sulc., sulcus; Tr., trunk; V., vein; Vel., velum.

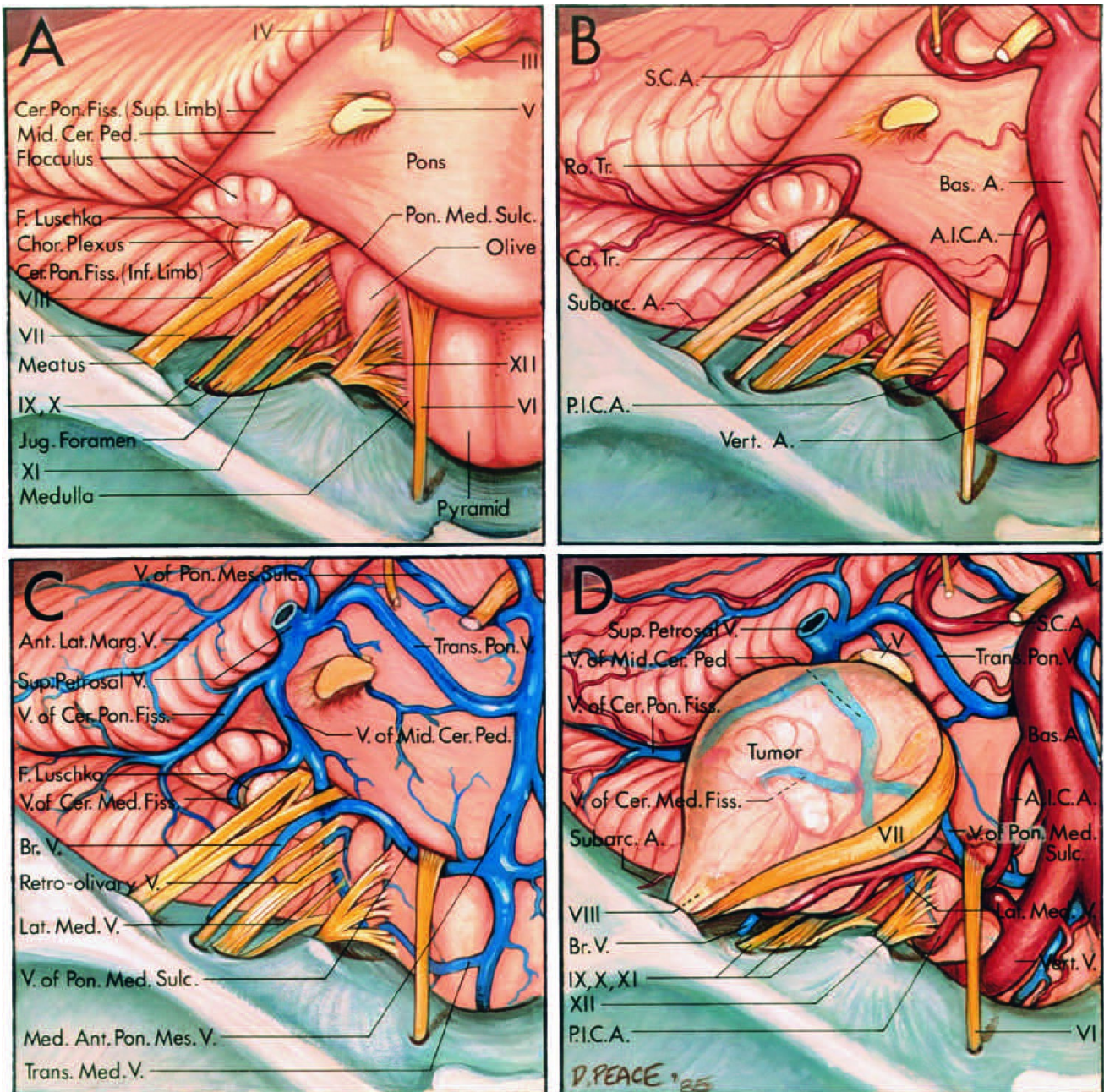


FIGURE 4.22. Neurovascular relationships on the brainstem side of an acoustic neuroma. Anterosuperior views. A, neural relationships. The cerebrum and tentorium cerebelli have been removed, and the trigeminal, trochlear, and oculomotor nerves have been divided to allow the brainstem to be displaced posteriorly to expose the cerebellopontine

angle from above. The facial and vestibulocochlear nerves arise at the lateral end of the pontomedullary sulcus anterior to the flocculus, rostral to the glossopharyngeal, vagus, and accessory nerves, and anterosuperior to the choroid plexus protruding from the foramen of Luschka. The cerebellopontine fissure, formed where the cerebellum wraps around the lateral side of the pons and middle cerebellar peduncle, has superior and inferior limbs. The foramen of Luschka opens into the inferior limb near the facial and vestibulocochlear nerves. B, arterial relationships. The AICA arises from the basilar artery, passes below the facial and vestibulocochlear nerves, gives rise to the subarcuate artery, and divides into a rostral and a caudal trunk. The rostral trunk passes above the flocculus to course on the middle cerebellar peduncle, and the caudal trunk supplies the area below the flocculus. C, venous relationships. The veins converging on the junction of the facial nerve with the brainstem are the lateral medullary and retro-olivary veins, and the veins of the pontomedullary sulcus, cerebellomedullary fissure, and middle cerebellar peduncle. The median anterior pontomesencephalic vein ascends on the anterior surface of the brainstem, and the transverse pontine and transverse medullary veins cross the pons and medulla. The vein of the cerebellopontine fissure passes above the flocculus. The transverse pontine vein and the veins of the middle cerebellar peduncle and cerebellopontine fissure join to form one of the superior petrosal veins that empty into the superior petrosal sinus. A bridging vein passes from the side of the brainstem to the jugular foramen. The anterolateral marginal vein crosses the anterolateral margin of the cerebellum. The vein of the pontomesencephalic sulcus courses in the pontomesencephalic sulcus below the oculomotor nerve. D, neurovascular relationships of an acoustic neuroma. The tumor arises from the vestibulocochlear nerve and displaces the facial nerve anteriorly, the trigeminal nerve superiorly, and the glossopharyngeal and vagus nerves inferiorly. The vestibulocochlear nerve disappears into the tumor. The facial nerve enters the brainstem along the lateral margin of the pontomedullary sulcus, rostral to the glossopharyngeal nerve, anterior to the flocculus, and rostral to the choroid plexus protruding from the foramen of Luschka. The AICA is usually displaced around the

lower margin of the tumor. The veins displaced around the medial side of the tumor are the veins of the pontomedullary sulcus, middle cerebellar peduncle, and cerebellomedullary fissure, and the lateral medullary and retro-olivary veins. (From, Rhoton AL Jr: Microsurgical anatomy of the brainstem surface facing an acoustic neuroma. *Surg Neurol* 25:326–339, 1986 [33].) A., artery; A.I.C.A., anteroinferior cerebellar artery; Ant., anterior; Bas., basilar; Br., bridging; Ca., caudal; Cer., cerebellar; Cer. Pon., cerebellopontine; Chor., choroid; F., foramen; Fiss., fissure; Inf., inferior; Jug., jugular; Lat., lateral; Marg., marginal; Med., medial, medullary; Mid., middle; Ped., peduncle; P.I.C.A., posteroinferior cerebellar artery; Pon., pontine; Pon. Med., pontomedullary; Pon. Mes., pontomesencephalic; Ro., rostral; S.C.A., superior cerebellar artery; Subarc., subarcuate; Sulc., sulcus; Sup., superior; Tr., trunk; Trans., transverse; V., vein; Vert., vertebral.

Brainstem Relationships

Neural relationships. The landmarks on the medial or brainstem side of structures that are helpful in guiding the surgeon to the junction of the facial nerve with the brainstem are the pontomedullary sulcus; the junction of the glossopharyngeal, vagus, and spinal accessory nerves with the medulla; the foramen of Luschka and its choroid plexus; and the flocculus. The facial nerve arises from the brainstem near the lateral end of the pontomedullary sulcus 1 to 2 mm anterior to the point at which the vestibulocochlear nerve joins the brainstem at the lateral end of the sulcus. The interval between the vestibulocochlear and facial nerves is greatest at the level of the pontomedullary sulcus and decreases as these nerves approach the meatus.

The facial nerve enjoys a consistent relationship to the junction of the glossopharyngeal, vagus, and spinal accessory nerves with the medulla (Figs. 4.20-4.22). The facial nerve arises 2 to 3 mm above the most rostral rootlet contributing to these nerves. A helpful way of visualizing the point where the facial nerve will exit from the brain stem, even when displaced by a tumor, is to project an imaginary line along the medullary junction of the rootlets forming the glossopharyngeal, vagus, and spinal accessory

nerves upward through the pontomedullary junction. This line, at a point 2 to 3 mm above the junction of the glossopharyngeal nerve with the medulla, will pass through the pontomedullary junction at the site where the facial nerve exits from the brainstem. The filaments of the nervus intermedius also are stretched around an acoustic neuroma.

The structures related to the lateral recess of the fourth ventricle that have a consistent relationship to the facial and vestibulocochlear nerves are the foramen of Luschka and its choroid plexus, and the flocculus (Figs. 4.20-4.22) (10, 27). The foramen of Luschka is situated at the lateral margin of the pontomedullary sulcus, just behind the junction of the glossopharyngeal nerve with the brainstem, and immediately posteroinferior to the junction of the facial and vestibulocochlear nerves with the brainstem. The foramen of Luschka is infrequently well visualized. A consistently identifiable tuft of choroid plexus, however, hangs out of the foramen of Luschka and sits on the posterior surface of the glossopharyngeal and vagus nerves just inferior to the junction of the facial and vestibulocochlear nerves with the brainstem. Another structure related to the lateral recess, the flocculus, projects from the margin of the lateral recess and foramen of Luschka into the cerebellopontine angle, just posterior to where the facial and vestibulocochlear nerves join the pontomedullary sulcus.

Arterial relationships. The arteries crossing the cerebellopontine angle, especially the AICA, enjoy a consistent relationship to the facial and vestibulocochlear nerves, the foramen of Luschka, and the flocculus as described elsewhere in this volume (13, 14, 24, 25). In a previous study, the author's group found that the AICA formed a loop that reached the porus or protruded into the canal in 54% of the cases (25). When opening the meatus by the middle fossa, translabyrinthine, or posterior approaches, care is required to avoid injury to the AICA if it is located at or protrudes through the porus.

In most cases, the AICA passes below the facial and vestibulocochlear nerves as it encircles the brainstem, but it also may pass above or between these nerves in its course around the brainstem (Fig. 4.23). In the

most common case, in which the artery passes below the nerves, the tumor would displace the artery inferiorly. If the artery courses between the facial and vestibulocochlear nerves, a tumor arising in the latter nerve will displace the artery forward. Tumor growth would displace the artery superiorly if it passes above the nerves. Atkinson pointed out that those cases of acoustic neuroma appearing at necropsy after operation frequently had occlusion of the AICA (3). In three cases presented by Atkinson, an arterial branch coursing over the tumor capsule was ligated with resulting lateral pontine, tegmental, and medullary infarction in the area supplied by the AICA and death. He noted that the blood pressure rose at or near the time of occlusion of the artery, although the hypertension often subsided by the end of the operation. These tumors may also displace the PICA and insinuate themselves between the basilar artery and the pons, stretching the perforating branches of the basilar artery. The labyrinthine, recurrent perforating, and subarcuate branches arise from the AICA near the facial and vestibulocochlear nerves and are frequently stretched around a cerebellopontine angle tumor.

Venous relationships. The veins on the side of the brainstem that have a predictable relationship to the facial and vestibulocochlear nerves are the vein of the pontomedullary sulcus, the veins of the cerebellomedullary fissure, middle cerebellar peduncle, and cerebellopontine fissure (Figs. 4.20- 4.22) (26). The identification of any of these veins during the removal of the tumor makes it easier to identify the site of the junction of the facial and vestibulocochlear nerves with the brainstem. The exposure of an acoustic neuroma in the central part of the cerebellopontine angle near the lateral recess usually can be completed without sacrificing a bridging vein. If a vein is obliterated during acoustic tumor removal, it is usually one of the superior petrosal veins, which is sacrificed near the superior pole of the tumor during the later stages of the removal of a large tumor. Small acoustic neuromas usually are removed without sacrificing a petrosal vein. The largest vein encountered around the superior pole of an acoustic neuroma is the vein of the cerebellopontine fissure.

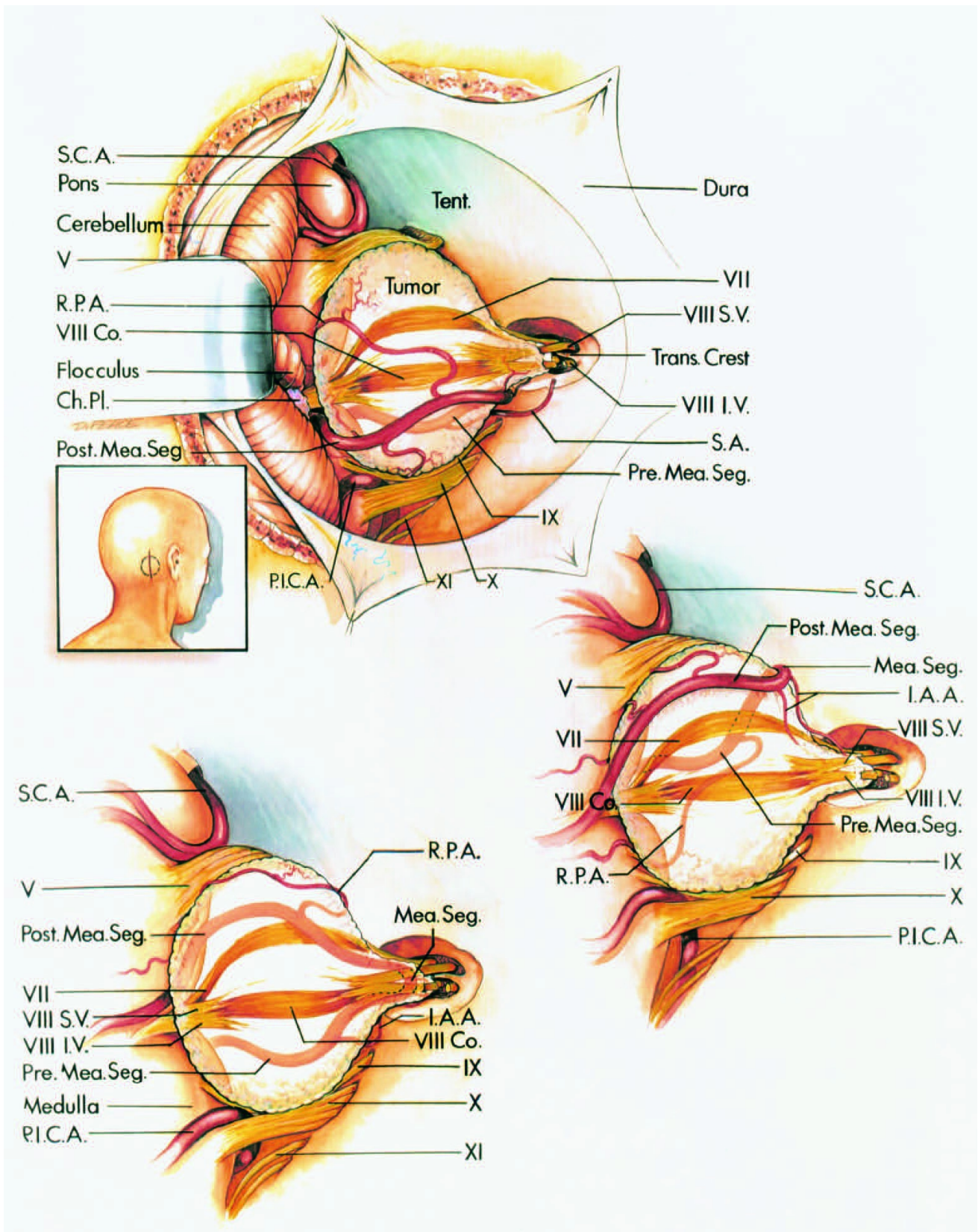


FIGURE 4.23. Posterior views of the direction of displacement of the AICA around an acoustic neuroma. Top left, the insert shows the direction of view. Both the premeatal and the postmeatal segments are in their most common locations around the lower margin of the tumor. The premeatal segment approaches the meatus from anteroinferior, and the postmeatal segment passes posteroinferior to the tumor. The SCA and the trigeminal nerve are above the tumor, and the PICA and the

glossopharyngeal, vagus, and spinal accessory nerves are below the tumor. The choroid plexus protrudes into the cerebellopontine angle medial to the tumor. The posterior wall of the internal acoustic canal has been removed to expose the transverse crest and the superior vestibular and inferior vestibular nerves. The vestibular nerves disappear into the tumor; however, the cochlear and facial nerves are displaced around the anterior margin of the tumor. A subarcuate artery arises from the premeatal segment, and a recurrent perforating artery arises from the postmeatal segment. Center right, in a less common pattern of displacement of the AICA, the premeatal and postmeatal segments are above the tumor. The internal auditory arteries arise from the meatal segment. Bottom left, both the premeatal and the postmeatal segments are displaced anteriorly to the tumor. This occurs if the AICA courses between the vestibulocochlear and facial nerves. The tumor arises in the vestibular nerves, and tumor growth displaces both the premeatal and the postmeatal segments anteriorly. (From, Martin RG, Grant JL, Peace DA, Theiss C, Rhoton AL Jr: Microsurgical relationships of the anterior inferior cerebellar artery and the facial-vestibulocochlear nerve complex. *Neurosurgery* 6:483–507, 1980 [25].) Ch. Pl., choroid plexus; Co., cochlear; I.A.A., internal auditory (labyrinthine) artery; I.V., inferior vestibular; Mea., meatal; P.I.C.A., posteroinferior cerebellar artery; Post., posterior; R.P.A., recurrent perforating artery; S.A., subarcuate artery; S.V., superior vestibular; S.C.A., superior cerebellar artery; Seg., segment; Tent., tentorium.

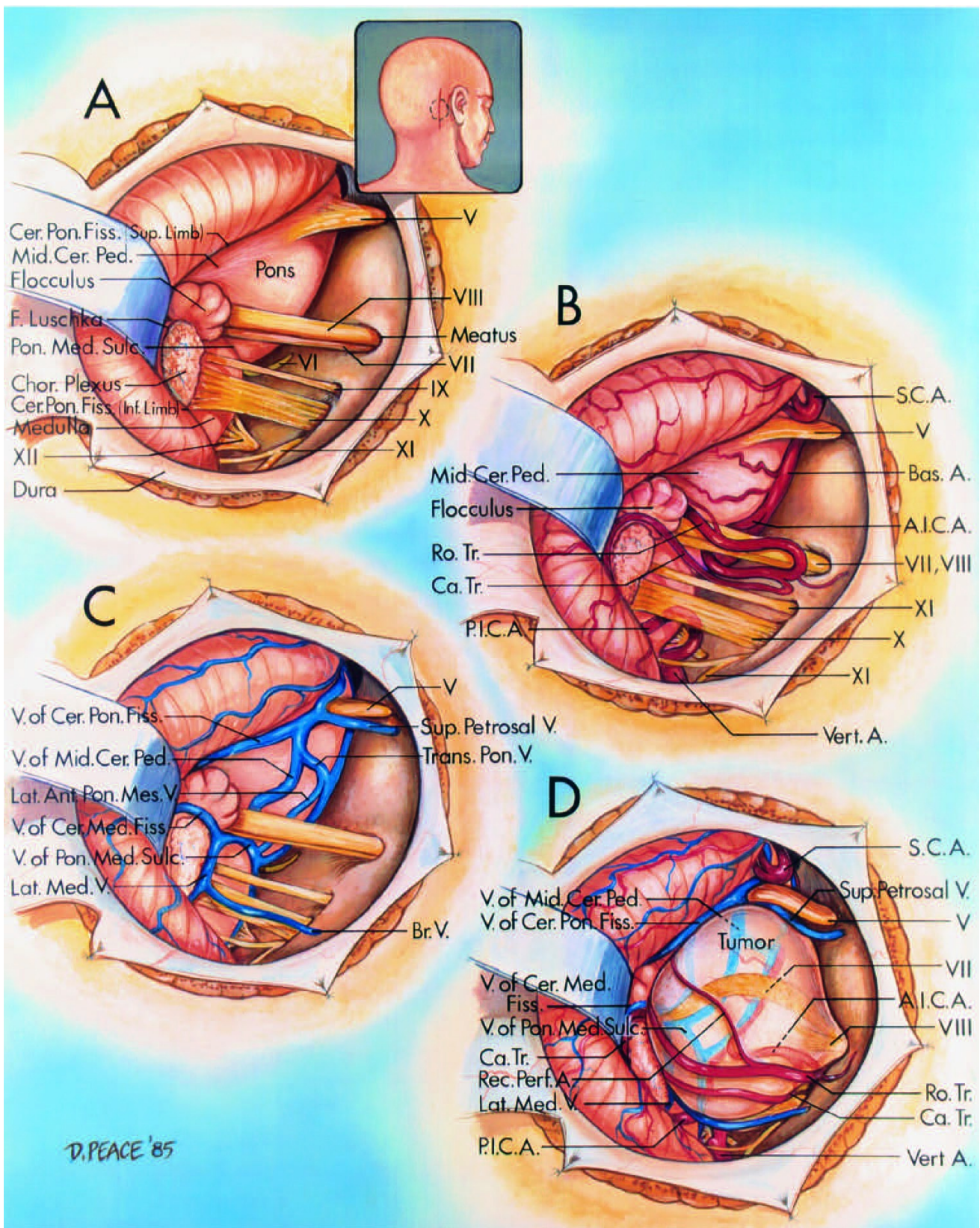


FIGURE 4.24. Neurovascular relationships on the brainstem side of an acoustic neuroma. Posterior view through a retrosigmoid craniotomy. A, neural relationships. The orientation, skin incision (solid line), and craniotomy site (interrupted line) are shown in the insert. The retractor is on the petrosal surface of the cerebellum. The facial and vestibulocochlear nerves arise at the lateral end of the pontomedullary sulcus, anterior to the flocculus, rostral to the glossopharyngeal, vagus, and accessory nerves,

and anterosuperior to the choroid plexus protruding from the foramen of Luschka. The cerebellopontine fissure, formed where the cerebellum wraps around the lateral side of the pons and middle cerebellar peduncle, has superior and inferior limbs. B, arterial relationships. The AICA arises from the basilar artery and divides into a rostral trunk, which passes above the flocculus to reach the surface of the middle cerebellar peduncle, and a caudal trunk, which supplies the area below the flocculus. The PICA arises from the vertebral artery and passes dorsally between the vagus and accessory nerves. The SCA courses above the trigeminal nerve. C, venous relationships. The veins that join near the junction of the facial and vestibulocochlear nerves with the brainstem are the lateral medullary veins and the veins of the cerebellomedullary fissure, pontomedullary sulcus, and middle cerebellar peduncle. The vein of the cerebellopontine fissure passes above the flocculus along the superior limb of the cerebellopontine fissure and joins the vein of the middle cerebellar peduncle and a transverse pontine vein to form a superior petrosal vein, which empties into the superior petrosal sinus. A bridging vein passes behind the vagus nerve. The lateral anterior pontomesencephalic vein ascends on the pons. D, neurovascular relationships of an acoustic neuroma. The tumor arises from the vestibulocochlear nerve and displaces the facial nerve anteriorly, the trigeminal nerve superiorly, and the glossopharyngeal and vagus nerves inferiorly. The vestibulocochlear nerve disappears into the tumor. The facial nerve enters the brainstem at the lateral margin of the pontomedullary sulcus anterior to the flocculus and rostral to the choroid plexus protruding from the foramen of Luschka. The rostral trunk of the AICA courses below the tumor and above the flocculus to reach the surface of the middle cerebellar peduncle. The veins displaced around the medial side of the tumor are the lateral medullary veins and the veins of the middle cerebellar peduncle, cerebellomedullary fissure, and pontomedullary sulcus. The vein of the cerebellopontine fissure passes above the tumor. A recurrent perforating branch of the AICA passes across the tumor and supplies the brainstem. (From, Rhoton AL Jr: Microsurgical anatomy of the brainstem surface facing an acoustic neuroma. *Surg Neurol* 25:326–339, 1986 [33].) A., artery; A.I.C.A., anteroinferior cerebellar artery; Ant., anterior; Bas.,

basilar; Br., bridging; Ca., caudal; Cer., cerebellar; Cer. Pon., cerebellopontine; Chor., choroid; F., foramen; Fiss., fissure; Lat., lateral; Med., medial, medulla; Mid., middle; Ped., peduncle; Perf., perforating; P.I.C.A., posteroinferior cerebellar artery; Pon., pontine; Pon. Med., pontomedullary; Rec., recurrent; Ro., rostral; S.C.A., superior cerebellar artery; Sulc., sulcus; Sup., superior; Tr., trunk; V., vein; Vert., vertebral.

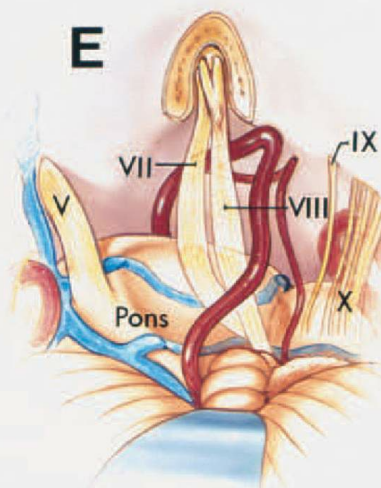
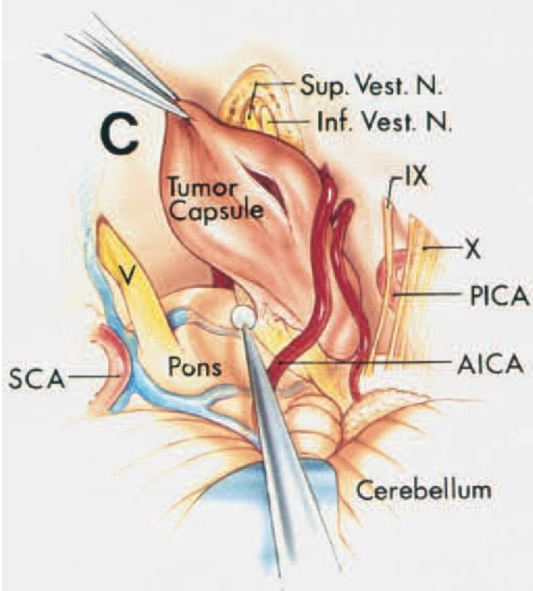
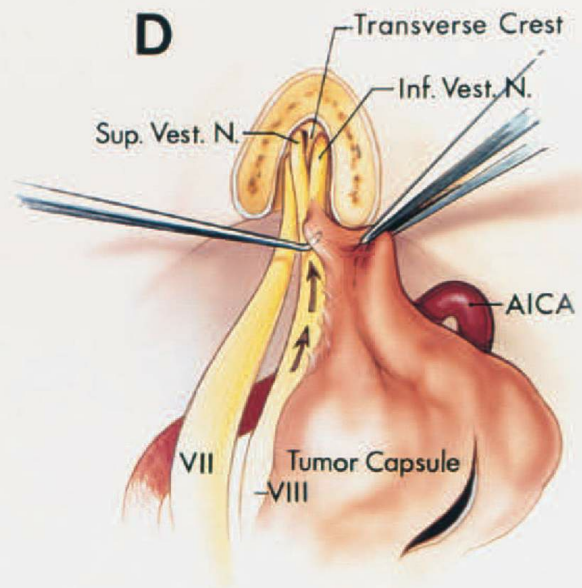
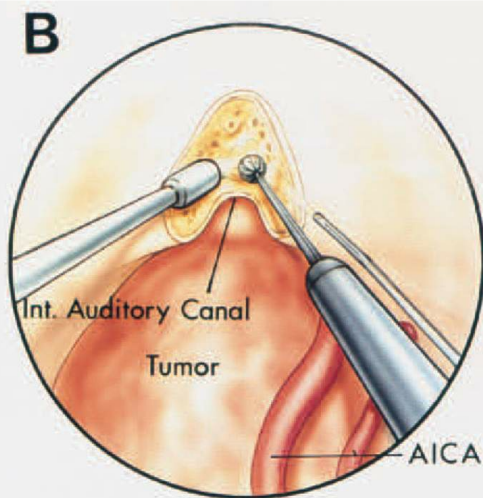
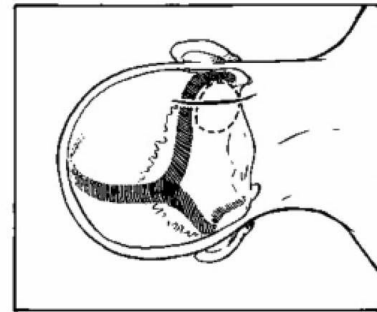
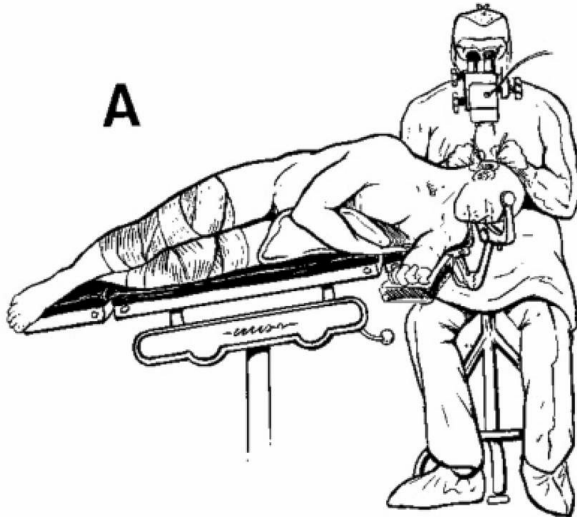


FIGURE 4.25. A. Retrosigmoid approach for removal of small or medium-size acoustic neuromas. **A**, the patient is positioned in the three-quarter prone position with the surgeon behind the head. The insert (right) shows the site of the scalp incision (continuous line) and the bony opening (interrupted line). **B–E.** Retrosigmoid approach for the removal of small or medium-size acoustic neuromas. **B**, the posterior wall of the internal auditory canal is removed using an irrigating drill. The AICA courses around the lower margin of the tumor. **C**, the intracapsular contents of the tumor have been removed. The capsule of the tumor is being separated from the pons and the posterior surface of the part of the facial and vestibulocochlear nerves adjacent to the brainstem. The superior and inferior vestibular nerves are seen at the lateral end of the internal auditory canal. The trigeminal nerve and SCA are above the tumor and the glossopharyngeal and vagus nerves and the PICA are below the tumor. **D**, the dissection along the eighth nerve is done in a medial to lateral direction (arrows) to avoid tearing the tiny filaments of the cochlear nerve in the lateral end of the canal where they pass through the lamina cribrosa. The transverse crest separates the superior and inferior vestibular nerves in the lateral end of the canal. **E**, cerebellopontine angle and internal auditory canal after tumor removal. The facial and vestibulocochlear nerves have been preserved. A.I.C.A., anteroinferior cerebellar artery; Inf., inferior; Int., internal; N., nerve; P.I.C.A., posteroinferior cerebellar artery; S.C.A., superior cerebellar artery; Sup., superior; Vest., vestibular. (From, Rhoton AL Jr: Microsurgical anatomy of acoustic neuromas, in Sekhar LN, Janecka IP (eds): Surgery of Cranial Base Tumors. New York, Raven Press, 1993, pp 687–713 [37].)

Summary: Anatomy of Acoustic Neuromas

Because acoustic neuromas most frequently arise in the posteriorly placed vestibular nerves, they usually displace the facial and cochlear nerves anteriorly (Figs. 4.19 and 4.24). The facial nerve is stretched around the anterior half of the tumor capsule. Variability in the direction of the growth of the tumor arising from the vestibular nerves may result in the facial nerve being displaced, not only directly anteriorly, but also

anterosuperiorly or anteroinferiorly. The nerve infrequently is found on the posterior surface of the tumor. Because the facial nerve always enters the facial canal at the anterosuperior quadrant of the meatal fundus, it usually is easiest to locate it here, rather than at a more medial location where the degree of displacement of the nerve is more variable. The cochlear nerve also lies anterior to the vestibular nerve and is stretched most frequently around the anterior half of the tumor. The strokes of the fine dissecting instruments used in removing the tumor should be directed along the vestibulocochlear nerve from medial to lateral rather than from lateral to medial, because traction medially may tear the tiny filaments of the cochlear nerve at the site where these filaments penetrate the lateral end of the meatus to enter the cochlea (Figs. 4.18 and 4.25).

The operation for a cerebellopontine angle tumor should be planned so that the tumor surface is allowed to settle away from the neural tissue rather than the neural structures being retracted away from the tumor (Fig. 4.25). No attempt is made to see the whole tumor upon initial exposure. The surface of the tumor then is opened and the intracapsular contents are removed. As the intracapsular contents are evacuated, the tumor shifts laterally, allowing more of the tumor to be removed through the small exposure. The most common reason for the tumor appearing to be tightly adherent to the neural structures is not adhesions between the capsule and surrounding tissue, but, rather, the residual tumor within the capsule wedging the tumor into position. As the intracapsular contents are removed, the tumor capsule folds laterally, revealing the structures on the brainstem side of the tumor.

The landmarks that are helpful in identifying the facial and vestibulocochlear nerves at the brainstem on the medial side of the tumor have been reviewed (Figs. 4.20-4.24) (33). These nerves, although distorted by the tumor, usually can be identified on the brainstem side of the tumor at the lateral end of the pontomedullary sulcus, just rostral to the glossopharyngeal nerve and just anterosuperior to the foramen of Luschka, the flocculus, and the choroid plexus protruding from the foramen of Luschka. After the facial and vestibulocochlear nerves are identified on the medial and lateral sides of the tumor, the final remnants

of the tumor are separated from the intervening segment of the nerves using fine dissecting instruments (Fig. 4.25). It is especially important to preserve the segment of the cerebellar arteries adherent to the tumor capsule because a major cause of operative mortality and morbidity is the loss of perforating arteries and branches of the cerebellar arteries that may be adherent to and displaced by the tumor. Any vessel that stands above or is stretched around the tumor capsule should be dealt with initially as if it were an artery that runs over the tumor surface to supply the brain. After the tumor has been removed from within the capsule, an attempt should be made to displace the vessel off the tumor capsule. When dissected free of the capsule, vessels that initially appeared to be adherent to the capsule often prove to be neural vessels. The number of veins sacrificed should be kept to a minimum because of the undesirable consequences of their loss. Obliteration of the petrosal veins, which pass from the surface of the cerebellum and the brainstem to the superior petrosal sinus, is inescapable when reaching and removing some cerebellopontine angle tumors. Occlusion of these veins, which drain much of the cerebellum and the brainstem, infrequently may cause hemorrhagic edema of the cerebellum and the brainstem. Some of these veins may need to be sacrificed if the tumor extends into the area above the internal acoustic meatus. Small acoustic neuromas and other tumors in the lower part of the cerebellopontine angle, however, frequently may be removed without sacrificing a petrosal vein. In removing the posterior meatal lip, a communication may be established between the subarachnoid space and the mastoid air cells that will require careful closure to prevent a cerebrospinal fluid leak. Laying a small pledget of crushed fat over the drilled meatal area has been successful in minimizing this complication (Fig. 4.25). The retrosigmoid approach is used by this author for most acoustic neuromas, because it is suitable for the removal of both small and large tumors. Unlike the translabyrinthine approach, described in the section on the temporal bone, which is directed through the vestibule and semicircular canals, the retrosigmoid approach is not necessarily associated with hearing loss. The retrosigmoid approach provides a broader exposure of the small tumor than does the middle fossa approach. Also, once the nerves are identified lateral to the tumor,

there are advantages to being able to separate the tumor capsule off the nerves beginning medially, because this more often results in preservation of hearing than dissection starting laterally. Compared with the middle fossa approach, it has the advantage that the facial nerve is usually deep to the tumor and often is protected by a thin veil of vestibulocochlear nerve, thus increasing the opportunity for facial nerve preservation. In the middle fossa approach, the facial nerve is often in the upper part of the exposure, stretched over the upper half of the tumor, and much of the dissection is directly on the surface of the nerve, which increases the risk of facial dysfunction after surgery.

Anatomy of Vascular Compression in the Middle Neurovascular Complex

Compression of the facial and vestibulocochlear nerves by tortuous arteries is postulated to cause dysfunction of these nerves, and cases in which surgical liberation of the vessels from these nerves has relieved the symptoms provide support for a vascular compressive etiology (Figs. 4.1 and 4.20) (11, 20, 38). Ectasia and elongation of the arteries are important in forcing the arteries into the nerves. Gardner was the first to treat hemifacial spasm by removing a compressive arterial loop from the facial nerve (11). Jannetta et al., using the suboccipital approach to the cerebellopontine angle, found mechanical compression and distortion of the root exit zone of the facial nerve in all of 47 patients with hemifacial spasm (20). The distorting vessel not only was the AICA and its branches, but in some cases was found to be the PICA, the vertebral or basilar artery, veins, or an arteriovenous malformation (Fig. 4.26) (20). It is expected that the AICA would be the compressing vessel in most cases because the facial nerve is located in the middle neurovascular complex. However, a tortuous PICA is an equally frequent offending vessel in hemifacial spasm, followed in order by the vertebral artery, basilar artery, veins, and a combination of these vessels (Figs. 4.26 and 4.27). The proximal part of the PICA usually passes around the brainstem below the facial and vestibulocochlear nerves. In some cerebellopontine angles, however, the proximal part of the PICA, after coursing posteriorly to the level of the hypoglossal rootlets, will loop superiorly toward the facial and

vestibulocochlear nerves before descending to pass between the glossopharyngeal, vagus, and spinal accessory nerves.

The offending arterial loop may be located on either the superior or the inferior aspect of the facial nerve at its exit from the brainstem. In the most common type of hemifacial spasm, that beginning in the orbicularis oculi muscle and gradually spreading downward to involve the lower face, the anteroinferior aspect of the nerve root exit zone will commonly be compressed. Atypical hemifacial spasm, a much less common entity, beginning in the lower or midface and spreading upward to involve the frontalis muscle, will be caused by the compression of the posterosuperior aspect of the facial nerve at the brainstem. Jannetta and others thought that the arteries frequently seen coursing around or between the facial and vestibulocochlear nerves in the interval between the brainstem and porus acusticus, as found by Gardner (11), were not the cause of hemifacial spasm, but that crosscompression of the facial nerve by the same arteries coursing at right angles to the nerve at the root exit zone was the essential element (20). The craniotomy for hemifacial spasm is positioned behind the lower half of the sigmoid sinus.

The operation for hemifacial spasm is directed along the inferolateral margin of the cerebellum (Figs. 4.28 and 4.29). The craniotomy is located medial to the lower half of the sigmoid sinus (Figs. 4.9, 4.28, and 4.29). It is not necessary to extend the bone opening downward to the foramen magnum or upward to the transverse sinus. The inferolateral margin of the cerebellum is elevated with a small brain spatula and the arachnoid behind the glossopharyngeal and vagus nerves is opened. This will expose the tuft of choroid plexus protruding from the foramen of Luschka, which sits on the posterior surface of the glossopharyngeal and vagus nerves.

Commonly, the flocculus is seen protruding behind the nerves and blocks their visualization at the junction with the brainstem. It also may be difficult to see the facial nerve that is hidden in front of the vestibulocochlear nerve. At this time, it is important to recall that the facial nerve root exits the brainstem 2 to 3 mm rostral to the point at which the glossopharyngeal nerve enters the brainstem. To expose the nerve's exit zone, it may be necessary to gently separate the choroid

plexus from the posterior margin of the glossopharyngeal nerve so that its junction with the brainstem can be seen. The brain spatula is advanced upwards to elevate the choroid plexus away from the posterior margin of the glossopharyngeal nerve. The exposure is then directed several millimeters above the glossopharyngeal nerve to where the facial nerve will be seen joining the brainstem below and in front of the vestibulocochlear nerve. The spatula often needs to be positioned so that it elevates the lower margin of the flocculus. Care must be taken to avoid damage to the vestibulocochlear nerve, which may be adherent to the flocculus. In the experience of this author, the most common offending artery is a PICA that loops upward before passing between the glossopharyngeal, vagus, and spinal accessory nerves. After looping into the facial nerve exit zone, the PICA then passes distally between the rootlets of the lower cranial nerves. The compressing artery may also be the premeatal or postmeatal segments of the AICA or a tortuous vertebral or basilar artery. Care is taken to explore the interval between the facial and vestibulocochlear nerves because it would be easy to miss a vessel compressing the facial nerve in this location.

Venous compression is less commonly encountered. The most common venous compression is by the vein of the pontomedullary sulcus, the retro-olivary vein, or the vein of the middle cerebral peduncle (26). The vein of the pontomedullary sulcus and the retro-olivary vein commonly join in the region of the facial nerve to form the vein of the middle cerebellar peduncle, which ascends on the middle cerebral peduncle toward the superior petrosal sinus. The vein of the middle cerebral peduncle commonly passes between the facial and vestibulocochlear nerves. It is not uncommon to encounter a bridging vein that passes from the lateral side of the medulla to the jugular bulb. At the time of elevating the cerebellum, it is best to obliterate this vein with gentle bipolar coagulation.

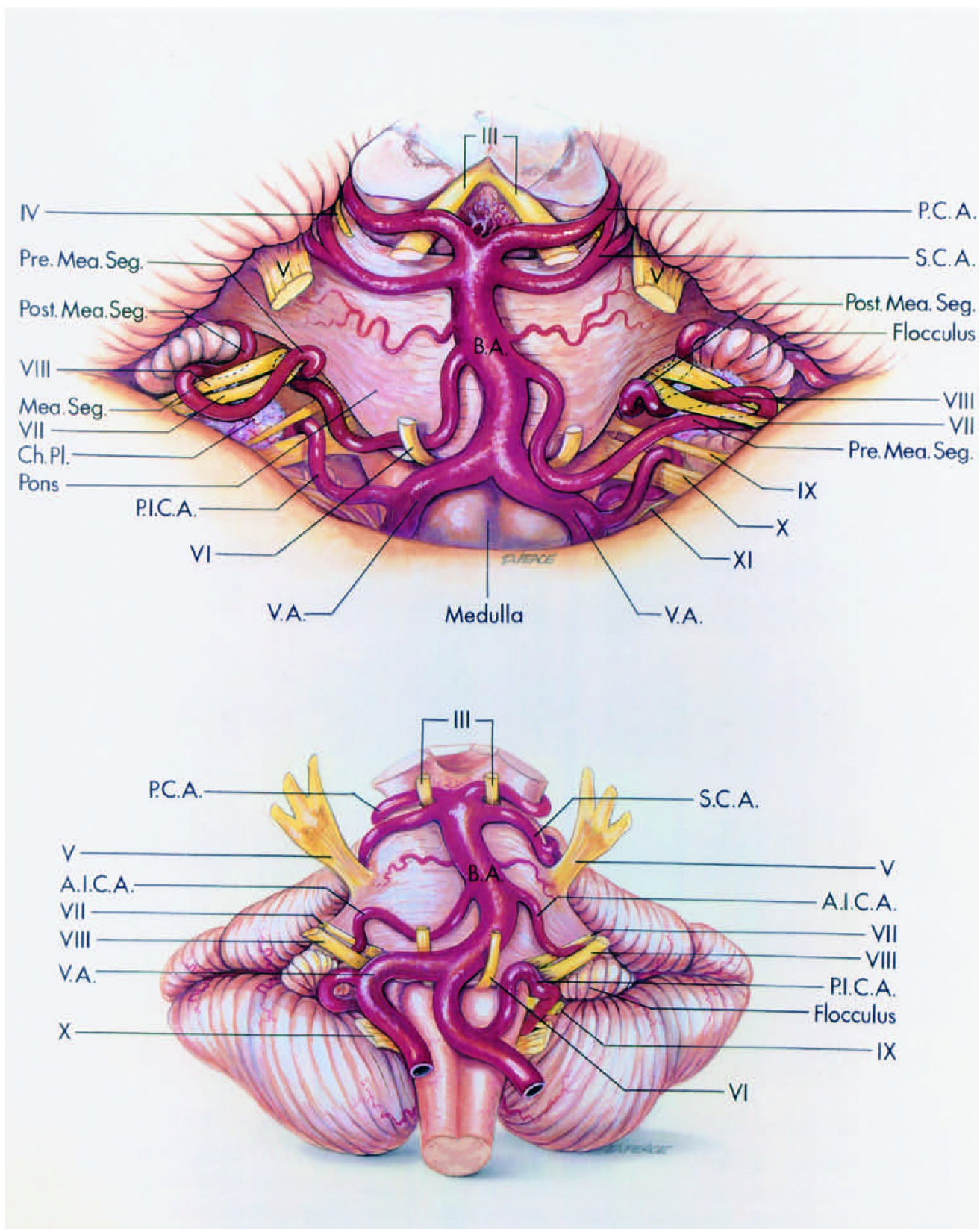


FIGURE 4.26. Sites of arterial compression of the facial nerve in hemifacial spasm. **A**, anterosuperior view. The facial and vestibulocochlear nerves are distorted at their junction with the brainstem by the right premeatal and the left postmeatal segments of the AICAs. **B**, anterior view. The junction of the right facial and vestibulocochlear nerves with the brainstem is compressed by a tortuous vertebral artery. The nerves on the left side are compressed by the PICA.

(From, Martin RG, Grant JL, Peace DA, Theiss C, Rhoton AL Jr: Microsurgical relationships of the anterior inferior cerebellar artery and the facial-vestibulocochlear nerve complex. *Neurosurgery* 6:483–507, 1980 [25].) A.I.C.A., anteroinferior cerebellar artery; Ch. Pl., choroid plexus; Mea., meatal; P.C.A., posterior cerebral artery; P.I.C.A., posteroinferior cerebellar artery; Post., posterior; S.C.A., superior cerebellar artery; Seg., segment; V.A., vertebral artery.

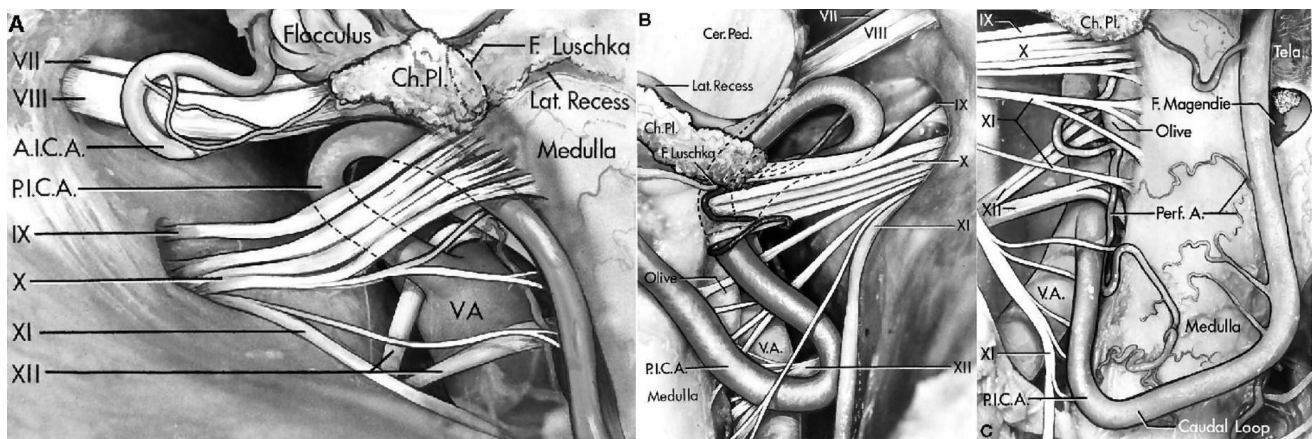


FIGURE 4.27. A, the PICA arises from the vertebral artery, passes between the rootlets of the hypoglossal nerve, and loops superiorly under the glossopharyngeal and vagus nerves before passing posteroinferiorly between the rootlets of the vagus and spinal accessory nerves. The vertebral artery stretches the rootlets of the hypoglossal nerve posteriorly. The AICA loops posterior to the facial and vestibulocochlear nerves. B, a tortuous PICA arises from the vertebral artery and passes rostrally toward the vestibulocochlear and facial nerves. At the level of the vestibulocochlear nerve, it loops inferiorly and descends anterior to the glossopharyngeal and vagus nerves, and passes between the vagus and spinal accessory nerves. The PICA compresses the medulla anterior to the origin of the glossopharyngeal and vagus nerves. The choroid plexus protrudes from the foramen of Luschka posterior to the glossopharyngeal nerve. The cerebellar peduncles are above the lateral recess of the fourth ventricle. C, the vertebral artery displaces and stretches the hypoglossal rootlets so far posteriorly that they intermingle with the rootlets of the spinal accessory nerve. The PICA descends between the rootlets of the spinal accessory nerve. (From, Lister JR, Rhoton AL Jr, Matsushima T, Peace DA: Microsurgical anatomy of the posterior inferior cerebellar artery. *Neurosurgery* 10: 170–199, 1982

[24].) A., artery; A.I.C.A., anteroinferior cerebellar artery; Cer., cerebellar; Ch. Pl., choroid plexus; F., foramen; Lat., lateral; Ped., peduncle; Perf., perforating; P.I.C.A., posteroinferior cerebellar artery; V.A., vertebral artery.

Cochlear and Vestibular Nerve Compression Syndromes

Vascular compression has been reported as a cause of cochlear and vestibular nerve dysfunction manifested by tinnitus, hearing loss, dysequilibrium, and disabling positional vertigo (21, 28, 29). The site of the compressive lesion with vestibulocochlear nerve dysfunction has been reported to be more peripheral along the nerve rather than at the junction with the brainstem, as commonly seen in trigeminal neuralgia and hemifacial spasm. Jannetta and others have restricted the use of the operation for vestibulocochlear nerve symptoms to those patients who are disabled and have documented unilateral disease on neuro-otologic testing. Jannetta et al. (21) and Gardner (11) have postulated that vascular compression of a cranial nerve is more likely to be symptomatic when it is located on the nerve proximal to the Obersteiner-Redlich zone where the axons are insulated by central myelin produced by oligodendroglia. It is proximal to this glial-neurilemmal junction that the compression causes transaxonal excitement between the afferent and efferent fibers. This glial-neurilemmal junction on the facial and trigeminal nerves is situated at the nerve root junction with the brainstem, but the entire intracranial portion of the vestibulocochlear nerve is sensitive to compression because the glial-neurilemmal junction is located at or in the internal acoustic meatus (21).

Compression by veins is less common around the facial and vestibulocochlear nerves than in the region of the trigeminal nerve because the veins around the facial and vestibulocochlear nerves tend to be smaller. Because no large bridging veins cross the subarachnoid space around the facial and vestibulocochlear nerves, as are seen frequently around the trigeminal nerve, any vascular cross-compression of facial and vestibulocochlear nerves peripheral to the brainstem is likely to be caused by arteries that loop through the cerebellopontine angle and even into the

meatus. The veins at the level of the junction of the facial and vestibulocochlear nerves with the brainstem tightly hug the pontomedullary junction where they adhere to the pial membrane, as described earlier in the section on the middle neurovascular complex.

Geniculate Neuralgia

Sectioning the nervus intermedius for geniculate neuralgia requires an understanding of the complex anatomy of this small nerve that is hidden between the vestibulocochlear and facial nerves (Figs. 4.1 and 4.30) (40). The nervus intermedius usually is described as a component of the facial nerve. Relatively little note has been taken of the fact that it may be closely bound to the vestibulocochlear nerve for a variable distance before it enters the brainstem, and that in the cerebellopontine angle, it may consist of as many as four rootlets. The nervus intermedius is found divisible into three parts: a medial segment that adheres closely to the vestibulocochlear nerve, an intermediate segment that lies freely between the acoustic nerve and the motor root of the facial nerve, and a distal segment that joins the motor root to form the facial nerve (40). Twenty-two percent of the nerves were adherent to the acoustic nerve for 14 mm or more (the entire course of the nerve in the posterior cranial fossa) and could be found as a separate structure only after opening the internal acoustic meatus. In most instances, the nerve was a single trunk, but in some cases, it was composed of as many as four rootlets. A single large root most frequently arises at the brainstem anterior to the superior vestibular nerve and, in the meatus, lies anterior to the superior vestibular nerve. When multiple rootlets are present, they may arise along the whole anterior surface of the vestibulocochlear nerve; however, they usually converge immediately proximal to the junction with the facial motor root to form a single bundle that lies anterior to the superior vestibular nerve.

It is the free segment between the facial and vestibulocochlear nerve that is divided in geniculate neuralgia. This segment, where the nervus intermedius is free of both the facial and vestibulocochlear nerves, may be located in the cerebellopontine angle or in the meatus if the nervus intermedius is composed of a single rootlet. If the nervus intermedius is

composed of more than one rootlet, however, there may be free segments both in the cerebellopontine angle and in the meatus. Geniculate neuralgia with or without vestibulocochlear dysfunction also has been postulated to be caused by vascular compression of the nervus intermedius or vestibulocochlear nerve (21, 29).

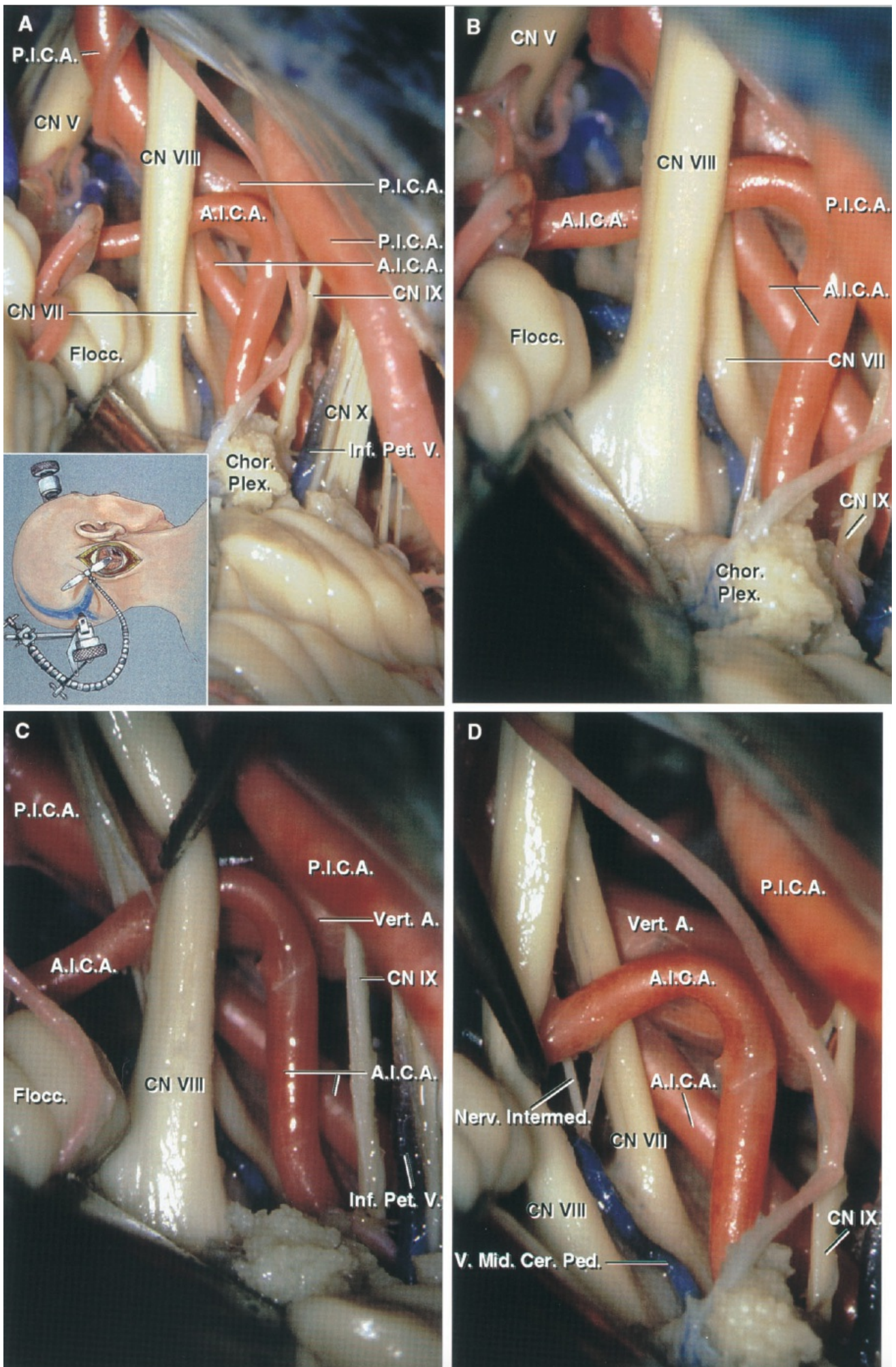


FIGURE 4.28. Facial nerve exposure in hemifacial spasm. A, the insert

shows the approach along the inferolateral margin of the cerebellum. The cerebellum has been elevated to expose the right cerebellopontine angle. The facial nerve exit zone from the brainstem is seen along the lower margin of the vestibulocochlear nerve. The AICA passes between the facial and vestibulocochlear nerve. A large tortuous PICA loops upward anterior to the facial and vestibulocochlear nerves and behind the trigeminal nerve, before turning downward to reach the medulla. The flocculus and the choroid plexus protruding from the foramen Luschka often hide the junction of the facial and vestibulocochlear nerves with brainstem. In this case, the flocculus has been gently elevated to expose the junction of these nerves with the brainstem. B, enlarged view.

Exposing the facial nerve exit zone from the brainstem is facilitated by directing the exposure along the inferolateral margin of the cerebellum in the area above the glossopharyngeal nerve and below the lower edge of the flocculus. C, the vestibulocochlear nerve has been depressed. This exposes the distal segment of the facial nerve, but does not provide access to the junction of the facial nerve with the brainstem, which should be visualized in dealing with hemifacial spasm. D, the vestibulocochlear nerve has been gently elevated. This exposes both the rostral and caudal margins of the facial nerve at the brainstem. A rootlet of the nervus intermedius is also exposed. The vein of the middle cerebellar peduncle passes between the facial and vestibulocochlear nerve. A., artery; A.I.C.A., anterior inferior cerebellar artery; Cer., cerebellar; Chor. Plex., choroid plexus; CN, cranial nerve; Flocc., flocculus; Inf., inferior; Intermed., intermedius; Mid., middle; Nerv., nervus; Ped., peduncle; Pet., petrosal; P.I.C.A., posterior inferior cerebellar artery; V., vein; Vert., vertebral.

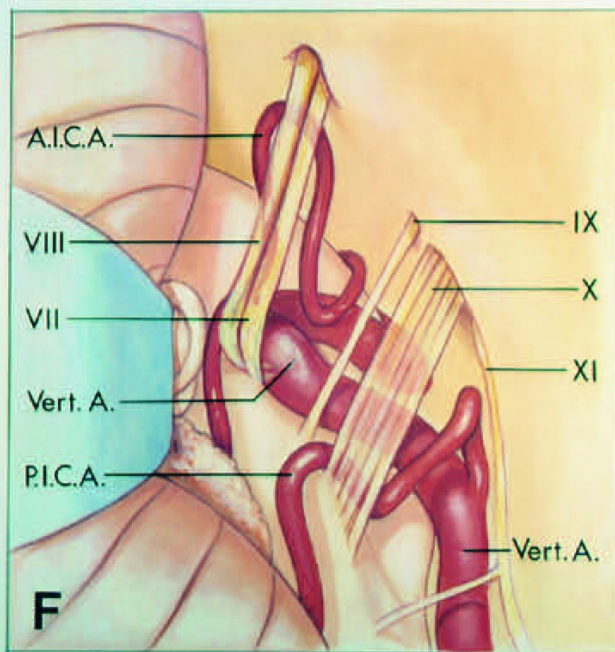
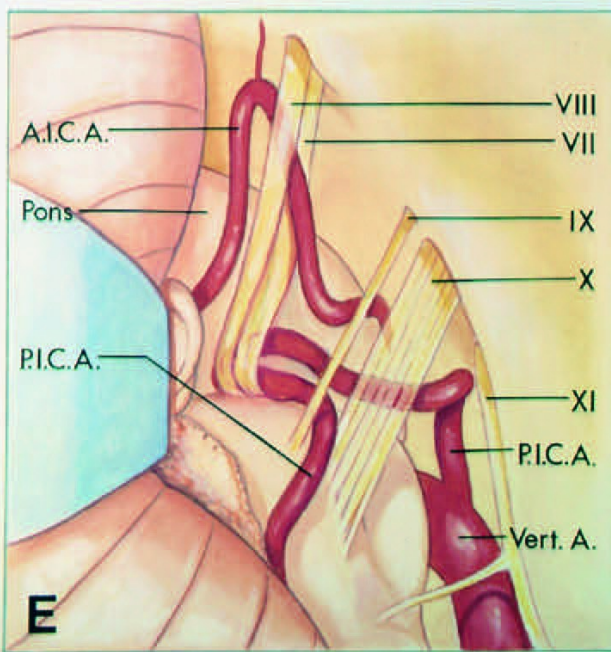
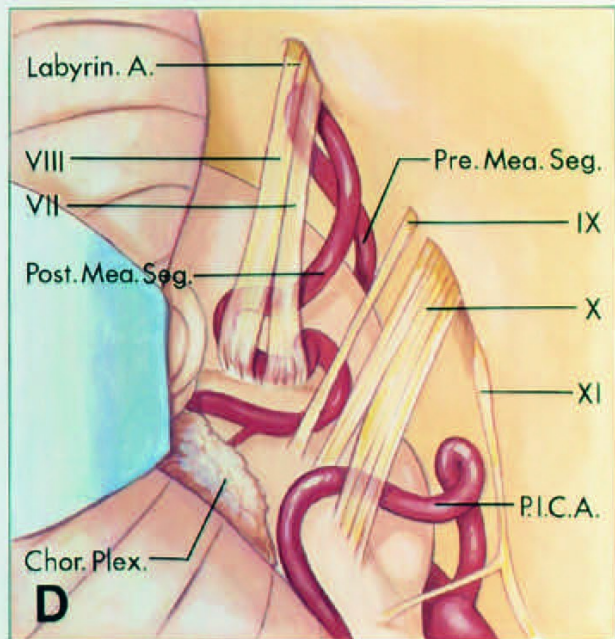
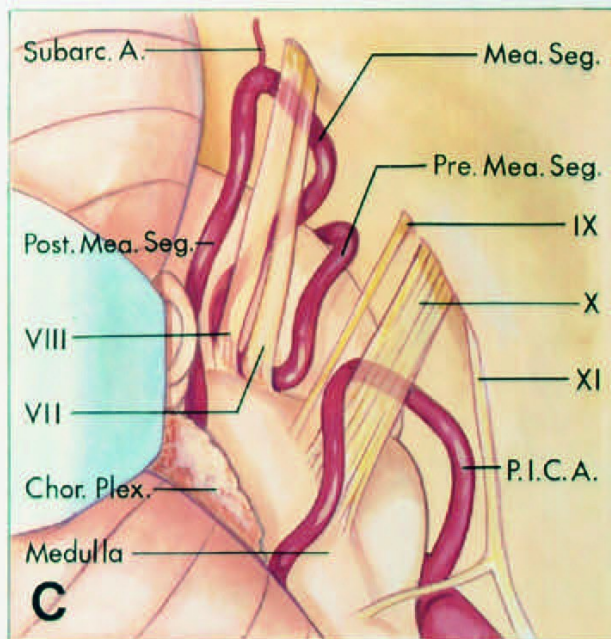
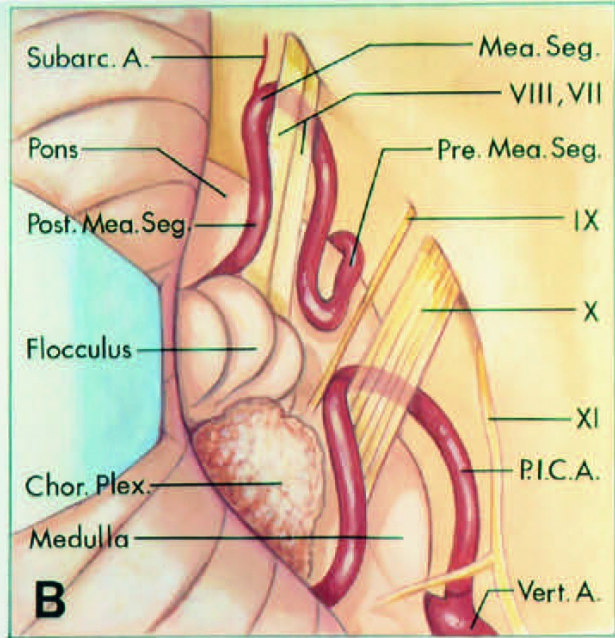
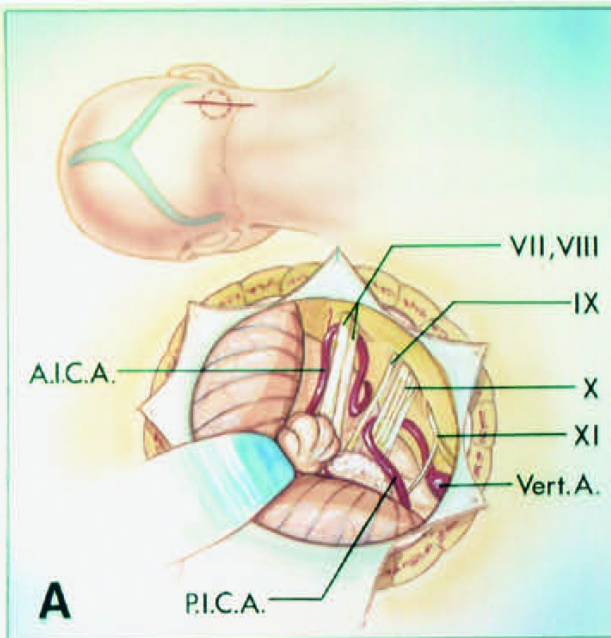


FIGURE 4.29. A-F, arterial compression of the facial nerve in hemifacial

spasm as viewed through a retrosigmoid craniotomy performed with the patient in the three-quarter prone position. A, the upper drawing shows the site of the incision (straight line) and the location of the craniotomy (broken line). The lower drawing shows the surgical exposure obtained with this approach. The AICA and the facial and vestibulocochlear nerves are in the midportion of the exposure. The vertebral artery, PICA, and the glossopharyngeal, vagus, and spinal accessory nerves are below. B, the cerebellum is elevated to expose the facial and vestibulocochlear nerves and the premeatal, meatal, and postmeatal segments of the AICA. The flocculus and the choroid plexus block the view of the junction of the facial and vestibulocochlear nerves with the brainstem. C, the flocculus and the choroid plexus have been elevated to expose the root entry/exit zone of the facial and vestibulocochlear nerves. The premeatal segment compresses the nerves at the junction with the pons and the medulla. D, the nerve root entry/ exit zone is compressed by the postmeatal segment. E, a tortuous PICA loops upward to compress the nerves at their junction with the brainstem before turning inferiorly to pass between the glossopharyngeal and vagus nerves. F, a tortuous vertebral artery compresses the nerve root entry/exit zone. A., artery; A.I.C.A., anteroinferior cerebellar artery; Chor. Plex., choroid plexus; Labyrin., labyrinthine; Mea., meatal; P.I.C.A., posteroinferior cerebellar artery; Post., posterior; Seg., segment; Subarc., subarcuate; Vert., vertebral.

Lower Neurovascular Complex

The lower complex, which is related to the PICA, includes the medulla, inferior cerebellar peduncle, cerebellomedullary fissure, suboccipital surface of the cerebellum, and the glossopharyngeal, vagus, spinal accessory, and hypoglossal nerves (Figs. 4.1, 4.17, and 4.27). The PICA arises at the medullary level, encircles the medulla, passing in relationship to the glossopharyngeal, vagus, spinal accessory, and hypoglossal nerves to reach the surface of the inferior cerebellar peduncle, where it dips into the cerebellomedullary fissure and terminates by supplying the suboccipital surface of the cerebellum.

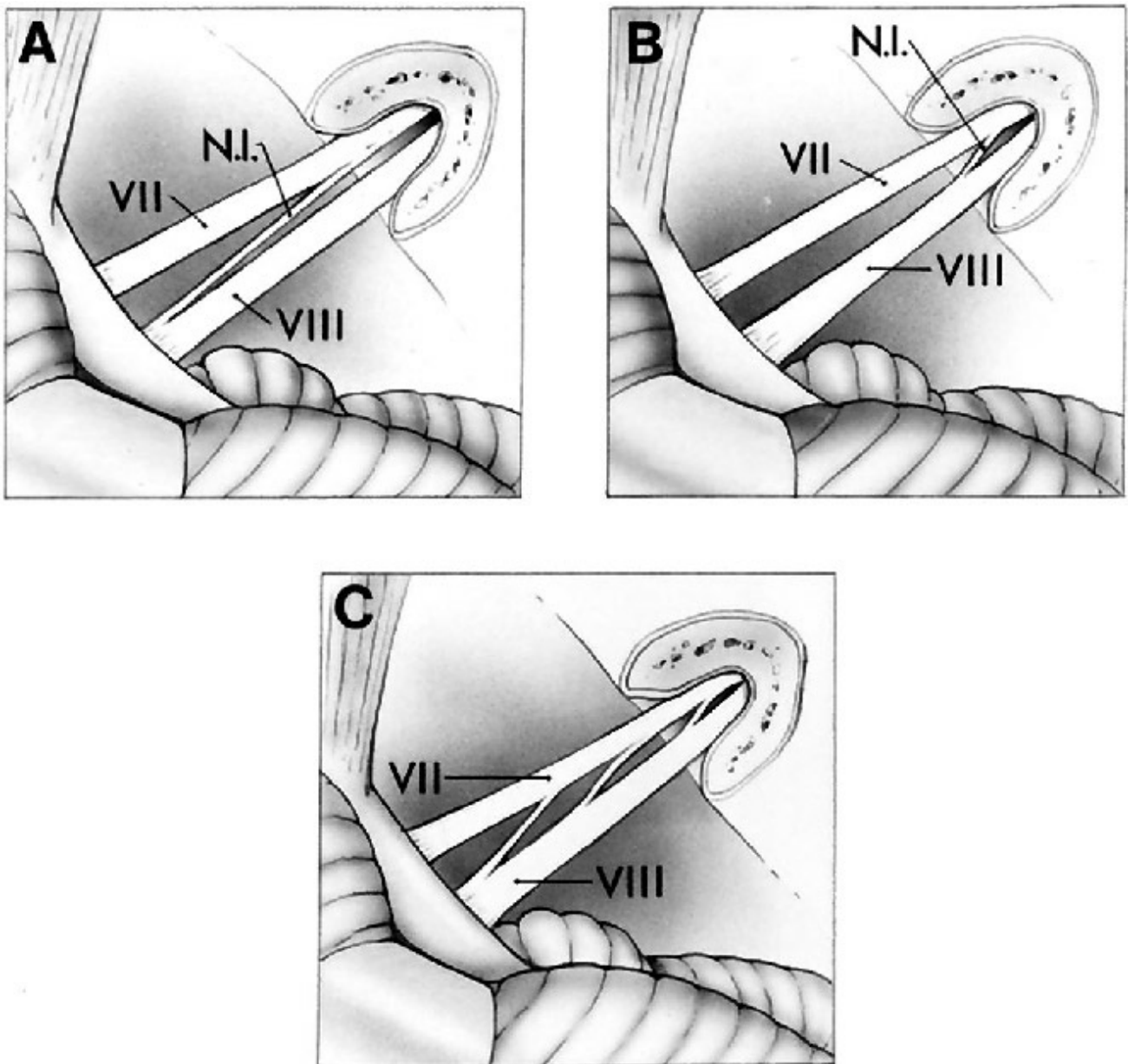
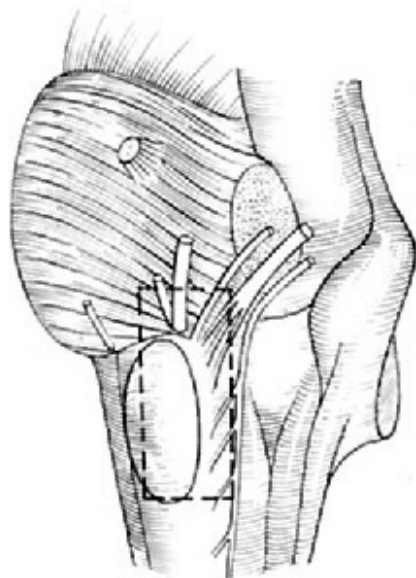
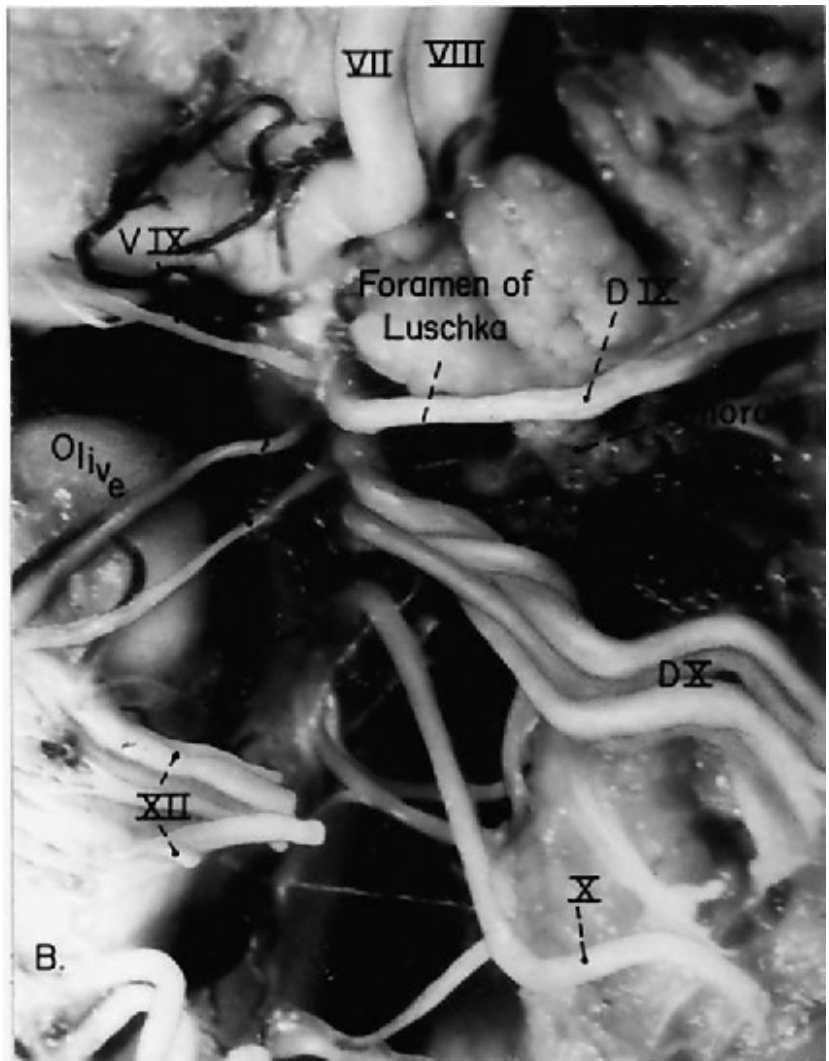


FIGURE 4.30. View of the cerebellopontine angle from above to show the relationship of the nervus intermedius to the facial and vestibulocochlear nerves. **A**, most common relationship. The nervus intermedius is joined to the ventral surface of the vestibulocochlear nerve for a few millimeters adjacent to the brainstem, then has a free segment in the cerebellopontine angle as it courses to join the facial motor root. **B**, pattern present in 20% of the nerves studied. The free segment is entirely in the meatus. **C**, the nervus intermedius consists of three free segments: two are the angle and one is in the meatus. The nervus intermedius in **A** could be exposed in the angle without drilling off the posterior lip of the meatus. In **B**, the free segment could not be found in the angle but only in the meatus. (From, Rhoton AL Jr: Microsurgical anatomy of acoustic neuromas, in Jackler RK (ed): Otolaryngologic Clinics of North America. Philadelphia, W.B. Saunders Co., 1992, pp 257–294

[35].)



A.



B.

FIGURE 4.31. A, lateral view of the left side of the brainstem as outlined by the broken line. B, note the ventral and dorsal rootlets of the glossopharyngeal and vagus nerves. One ventral glossopharyngeal and two ventral vagal rootlets are seen. (From, Rhoton AL Jr, Buza R: Microsurgical anatomy of the jugular foramen. *J Neurosurg* 42:541-550, 1975 [39].)

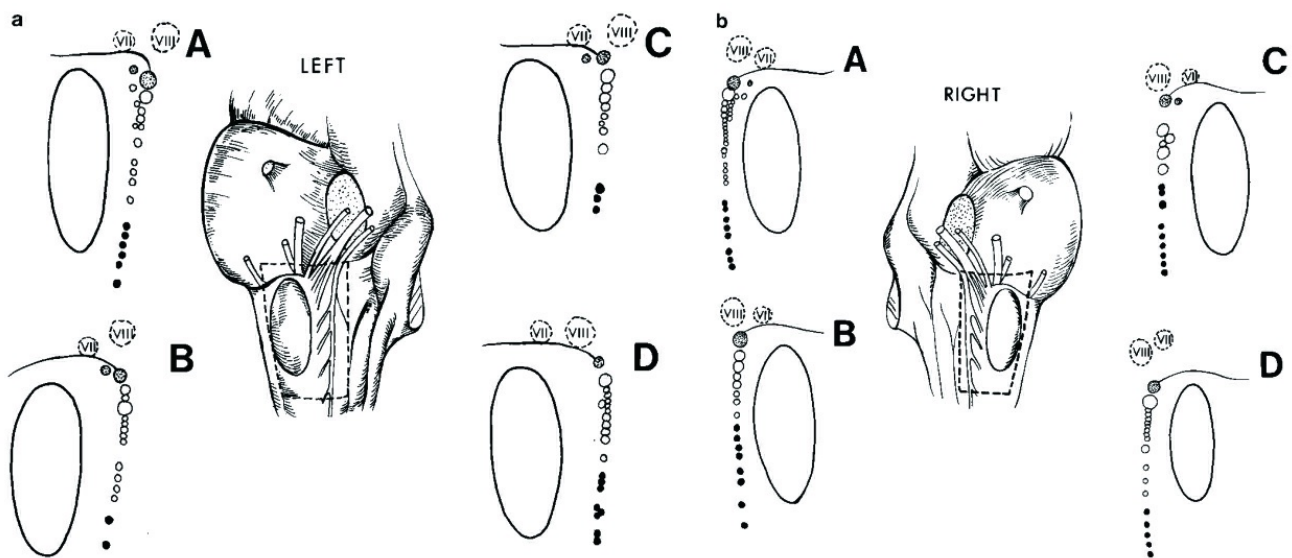


FIGURE 4.32. The broken line on the drawing of the lateral surface of the brainstem outlines the area shown in each diagram, demonstrating the brainstem origin and variations of the rootlet size of the glossopharyngeal, vagus, and spinal accessory nerves. The large ovoid structure is the inferior olive. The broken-line circles outline the origin of the facial and vestibulocochlear nerves. The most cephalad, shaded circles indicate glossopharyngeal rootlet origins, intermediate, open circles indicate vagal rootlet origins, and caudal, black circles outline spinal accessory rootlet origins. The glossopharyngeal nerve usually originates as one large rootlet, the vagus as a series of large and small rootlets, and the spinal accessory as a series of small rootlets. Top, note the small ventral rootlets of the glossopharyngeal nerve in A, B, and C and the small ventral rootlet between the glossopharyngeal and vagus nerves in A. The glossopharyngeal rootlet is larger than the rostral rootlet of the vagus nerve in all except D, in which the rostral vagal rootlet is larger than the glossopharyngeal nerve. Bottom, note the wide separation of the origin of the glossopharyngeal and vagus nerves in C, the small ventral rootlet of the glossopharyngeal nerve in C, and the small ventral rootlets of the glossopharyngeal and vagus nerves in A. The glossopharyngeal nerve is smaller than the upper vagal rootlet in A and D. (From, Rhoton AL Jr, Buza R: Microsurgical anatomy of the jugular foramen. *J Neurosurg* 42:541-550, 1975 [39].)

Neural Relationships

The glossopharyngeal, vagus, spinal accessory, and hypoglossal nerves

arise from the medulla along the margin of the inferior olive. The glossopharyngeal, vagus, and spinal accessory nerves arise as a line of rootlets that exit the brainstem along the posterior edge of the olive in the post-olivary sulcus, a shallow groove between the olive and posterolateral surface of the medulla (Figs. 4.1, 4.17, 4.31, and 4.32). The hypoglossal nerve arises as a line of rootlets that exit the brainstem along the anterior margin of the lower two-thirds of the olive in the preolivary sulcus, a groove between the olive and the medullary pyramid. The glossopharyngeal and vagus nerves arise at the level of the superior third of the olive. The spinal accessory rootlets arise along the posterior margin of the inferior two-thirds of the olive and from the lower medulla and the upper segments of the cervical spinal cord. The glossopharyngeal and vagus nerves arise rostral to the level of origin of the hypoglossal rootlets.

The glossopharyngeal nerve arises as one or rarely two rootlets from the upper medulla, posterior to the olive, just caudal to the origin of the facial nerve. It courses ventral to the choroid plexus protruding from the foramen of Luschka on its way to the jugular foramen. Frequently, a larger dorsal and a smaller ventral component can be seen at the junction with the brainstem (22, 39). The smaller ventral rootlets have been demonstrated to be motor and the larger main bundle to be sensory (7, 44). The larger dorsal component usually arises from the medulla as one root, except in a few cases in which it will originate as two rootlets. The two rootlets may remain separate throughout their course to the dura (Figs. 4.31 and 4.32).

The vagus nerve arises below the glossopharyngeal nerve as a line of tightly packed rootlets along a line 2 to 5.5 mm in length posterior to the superior third of the olive (Figs. 4.1, 4.27, and 4.32). The most rostral vagal fibers arise adjacent to the glossopharyngeal origin, from which they are sometimes separated by as much as 2 mm. The vagus is composed of multiple combinations of large and small rootlets that pass ventral to the choroid plexus protruding from the foramen of Luschka on its way to the jugular foramen. Occasionally, several small rootlets are found originating ventral to the majority of the vagal rootlets (Figs. 4.31 and 4.32). These small ventral rootlets are considered to be motor (7).

The accessory nerve arises as a widely separated series of rootlets that originated from the medulla at the level of the lower two-thirds of the olive and from the upper cervical cord. The cranial rootlets of the accessory nerve arise as a line of rootlets ranging in diameter from 0.1 to 1 mm just caudal to the vagal fibers (Figs. 4.1, 4.17, 4.27, and 4.32). The cranial rootlets of the accessory nerve are more properly regarded as inferior vagal rootlets, since they arise from vagal nuclei (22, 39). It may be difficult to separate the lower vagal fibers from the upper accessory rootlets because the vagal and cranial accessory fibers usually enter the vagal meatus as a single bundle.

The upper rootlets of the spinal portion of the accessory nerve originate several millimeters caudal to the lowest cranial accessory fibers and either course to join the cranial accessory bundle or enter the lower border of the vagal meatus separate from the cranial accessory rootlets. The spinal accessory fibers pass superolateral from their origin to reach the jugular foramen. Although the cranial and spinal portion of the accessory nerve most frequently enter the vagal meatus together, they may infrequently be separated by a dural septum.

The rootlets forming the hypoglossal nerve arise from the medulla along a line that is continuous inferiorly with the line along which the ventral spinal roots arise (Figs. 4.1, 4.17, and 4.27). These rootlets arise in a nucleus whose rostral part sits deep to the hypoglossal triangle in the floor of the fourth ventricle, and exit the medulla along the anterior margin of the caudal two-thirds of the olive. The hypoglossal rootlets course anterolateral through the subarachnoid space and pass behind the vertebral artery to reach the hypoglossal canal. If the vertebral artery is short and straight, it may not contact or distort the hypoglossal rootlets, but if the artery is tortuous it may stretch the hypoglossal rootlets posteriorly over its dorsal surface (38). Infrequently, the vertebral artery passes between the rootlets of the hypoglossal nerve (24). Before entering the hypoglossal canal, the rootlets collect into two bundles, and in some cases, the canal is divided by a bony septum that separates the two bundles. After passing through the canal, the bundles unite and the nerve lies medial to the internal jugular vein, and the glossopharyngeal,

vagus, and accessory nerves.

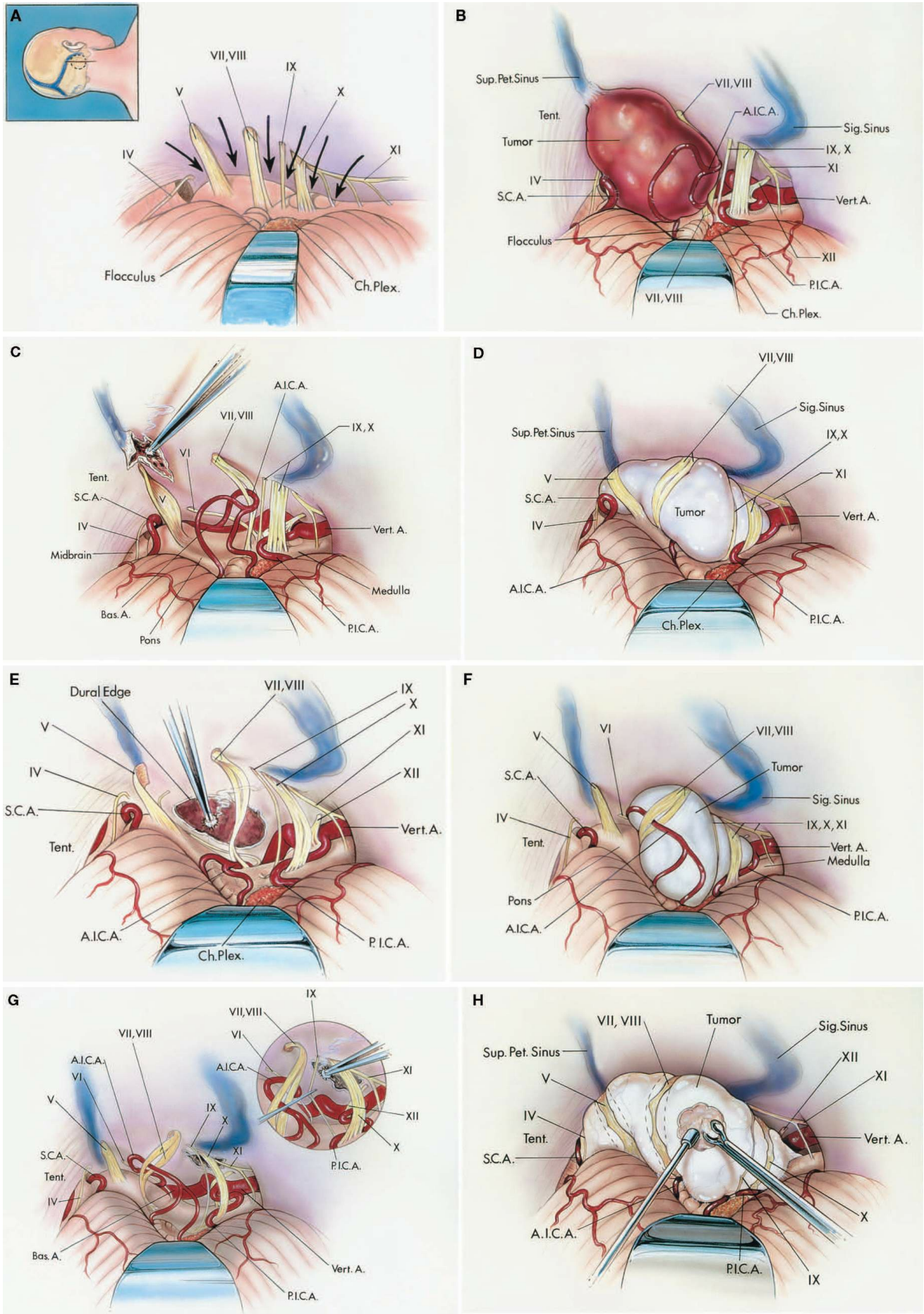


FIGURE 4.33. Tumors involving multiple neurovascular complexes. A,

routes that can be taken between the cranial nerves to expose and remove a tumor situated medial to and involving multiple cranial nerves. The patient is positioned in the three-quarter prone position. The insert (upper left) shows the site of the vertical scalp incision and craniotomy. The approach to pathology located medial to the nerves can be directed (arrows) between the trochlear nerve above and trigeminal nerve below; between the trigeminal nerve above and the facial and vestibulocochlear nerves below; between the facial and vestibulocochlear nerves above and the glossopharyngeal nerve below; between the glossopharyngeal and vagus nerves; between the vagus nerve and accessory rootlets; and between the widely separated rootlets of the accessory nerve. A tumor located medial to the nerves will often widen the intervals between the nerves, depending on the site of origin of the tumor. Choroid plexus protrudes from the foramen of Luschka. B, meningioma attached lateral to the trigeminal nerve in the region of the superior petrosal sinus. The trochlear nerve is elevated, the trigeminal nerve is pushed medially, and the facial and vestibulocochlear nerves are stretched below the tumor. C and D. Tumors involving multiple neurovascular complexes. C, the tumor has been removed. The thin distorted nerves have been preserved, and the remaining dural attachment is removed or cauterized with bipolar coagulation. The basilar artery and abducens nerve are exposed. D, a large meningioma arising from the clivus in the region of the inferior petrosal sinus with involvement of the fourth through the eleventh nerves. The nerves are displaced laterally around the tumor. The tumor is removed by working through the intervals between the nerves. Tumors involving multiple neurovascular complexes. E, the meningioma has been removed. The dural attachment has been partially removed and the base is being cauterized. F, meningioma arising medial to the jugular bulb in the region of the jugular tubercle and involving the lower cranial nerves. G and H. Tumors involving multiple neurovascular complexes. G, the tumor was removed by operating through the intervals between the facial and vestibulocochlear nerves above and the glossopharyngeal nerve below and between the glossopharyngeal and vagus nerves (round insert). H, a large epidermoid tumor being removed by working through the intervals between the nerves. A., artery; A.I.C.A., anteroinferior

cerebellar artery; Bas., basilar; Ch. Plex., choroid plexus; Pet., petrosal; P.I.C.A., posteroinferior cerebellar artery; S.C.A., superior cerebellar artery; Sig., sigmoid; Sup., superior; Tent., tentorium; Vert., vertebral.

Anatomy of Glossopharyngeal Neuralgia

Dandy (4) described endocranial sectioning of the glossopharyngeal nerve for neuralgia, but because this alone did not adequately control the neuralgia, he later advocated the additional sectioning of “perhaps 1/8 to 1/6 of the vagus” (Figs. 4.1, 4.17, 4.27, and 4.32). Tarlov (44, 45) sectioned the cephalic third of the vagal-spinal accessory group and produced analgesia of the epiglottis but only hypalgesia over the mucosa of the lower pharynx and larynx. In his second case, he sectioned the cephalic half of the vagal-spinal accessory complex; this caused both analgesia and transient paralysis of the ipsilateral soft palate, pharynx, and larynx. In our study, the structure of the vagus nerve was variable, being composed of all large or all small rootlets or any combination of the two. It is suggested that fewer of the rostral rootlets be cut if the diameters of the upper rootlets are large rather than small; the diameter of the largest rootlet is 1.5 mm and the smallest is 0.1 mm (39).

A large glossopharyngeal nerve diameter might be associated with a small diameter of the upper rootlets of the vagus nerve, or a large vagus nerve might be associated with a small glossopharyngeal nerve, because the two nerves arise from the same nuclei and have a similar function (7). This idea that more fibers might be distributed to one nerve, leaving the other smaller, was not confirmed in our studies (39). When the diameter of the dorsal root of the glossopharyngeal nerve is compared with the mean of the upper rootlets of the vagus nerve, no significant correlation is found (39). A smaller diameter of the glossopharyngeal nerve is not commonly associated with a large mean diameter of the upper rootlets of the vagus, nor is a large glossopharyngeal nerve diameter associated with a small diameter of the vagal rootlets.

The only location where the glossopharyngeal nerve can consistently be distinguished from the vagus is just proximal to the dural meati where a dural septum separates the glossopharyngeal and vagus nerves (39). This

septum varies in width from 0.5 to 4.9 mm and serves to differentiate the glossopharyngeal nerve from the vagus nerve. The close medullary origin of the glossopharyngeal and vagus nerves and the frequent arachnoid adhesions between the two makes separation difficult in their course through the subarachnoid space or adjacent to the brainstem, except in the few cases in which there will be a 1- to 2-mm separation between their origin at the medulla.

The superior glossopharyngeal and vagal ganglia may be visible intracranially (22). In glossopharyngeal neuralgia, Adson (1) noted the need to section the glossopharyngeal nerve proximal to the superior ganglion. The superior ganglion was intracranial in 32% of 50 jugular foramina that we examined and within or extracranial to the foramen in 68% (39). The superior ganglion of the vagus could be seen intracranially in only 14% of the cases.

Vascular Relationships

The vertebral artery courses anterior to the nerves in the lower neurovascular complex. The hypoglossal rootlets usually pass behind the vertebral artery, however, some hypoglossal rootlets infrequently pass anterior to the artery. If the vertebral artery is elongated or tortuous and courses laterally to the olive, it will stretch the hypoglossal rootlets over its posterior surface. Some tortuous vertebral arteries will stretch the hypoglossal rootlets so far posterior that they intermingle with the glossopharyngeal, vagus, and spinal accessory nerves. The PICA has a much more complex relationship to these nerves (Fig. 4.27). The proximal part of the PICA passes around or between and often stretches or distorts the rootlets of the nerves in the lower complex. At the anterolateral medulla, the PICA passes around or between the rootlets of the hypoglossal nerve. At the posterolateral margin of the medulla, it passes between the fila of the glossopharyngeal, vagus, and spinal accessory nerves. The PICA may be ascending, descending, or passing laterally or medially, or may be involved in a complex loop that stretches and distorts these nerves as it passes between them (Fig. 4.27). The relationships of the PICA and vertebral artery to these nerves are reviewed in greater

detail in the chapter on the cerebellar arteries.

Vascular Compression in the Lower Neurovascular Complex

The close relationship of the PICA and the vertebral artery to the glossopharyngeal and vagus nerves makes it logical to explore these relationships in glossopharyngeal neuralgia (23, 46). Both the glossopharyngeal and vagus nerves have been found to be compressed at their junction with the brainstem by the PICA or the vertebral artery, or both, with relief after separation of the arteries and nerves (23). The adverse cardiovascular effects of mobilization of these nerves and the risk to causing swallowing and vocal cord defects have led some to conclude that rhizotomy of the glossopharyngeal nerve and upper vagal rootlets is a reasonable alternative to vascular mobilization along the lateral medulla (19, 20, 21, 29, 41).

Jannetta has proposed that compression of the left side of the medulla by the PICA or the vertebral artery may be a cause of hypertension and that diabetes mellitus may result from right lateral medullary compression as a result of vagal effects on pancreatic islet cell secretion (9, 19). The fact that hypertension is a component of the Cushing response to lateral medullary compression has been well established and that hypertension has been relieved after decompression of the left side of the medulla supports this concept. The relationship of vascular compression to diabetes mellitus awaits further elucidation.

Tumors Involving Multiple Neurovascular Complexes

Tumors in the cerebellopontine angle commonly involve more than one of the neurovascular complexes (Fig. 4.33) (38). An especially difficult challenge is exposing and removing the tumors that are situated medial to the nerves. In this case, the operation must be directed through the interval between the neurovascular complexes, because these tumors often will widen these intervals. Lesions in the upper cerebellopontine angle may be exposed through the interval between the lower margin of the tentorium and the upper edge of the trigeminal nerve. Care is needed to protect the trochlear nerve and the SCA in this area. Further inferiorly,

the medially placed tumor may be approached through the interval between the trigeminal nerve above and the facial and vestibulocochlear nerves below. If the tumor has an even lower attachment near the jugular foramen, it can be approached through the interval between the lower margin of the nerves entering the internal meatus and the upper margin of the glossopharyngeal nerve, or through the interval between the lower rootlets of the vagus nerve and the upper rootlets of the spinal accessory nerve. The intervals between the glossopharyngeal and vagus nerves and between the individual vagal rootlets usually are too narrow to work through unless they have been opened by the tumor; however, the interval between the lower of the cranial accessory rootlets may provide access to lesions in the area. The role of procedures involving resection of parts of the temporal bone in accessing lesions in this area is reviewed in the chapter on the temporal bone.

Contributor: Albert L. Rhoton, Jr

Content from Rhoton AL, Jr. The posterior cranial fossa: microsurgical anatomy and surgical approaches. *Neurosurgery* 2000;47:1196. doi.org/10.1097/00006123-200105000-00065. With permission of Oxford University Press on behalf of the Congress of Neurological Surgeons. © Congress of Neurological Surgeons.

The Neurosurgical Atlas is honored to maintain the legacy of Albert L. Rhoton, Jr, MD.

REFERENCES

1. Adson AW: The surgical treatment of glossopharyngeal neuralgia. *Arch Neurol Psychiatry* 12:487–506, 1924.
2. Apfelbaum RI: Microvascular decompression for tic douloureux results, in Brackmann DE (ed): *Neurological Surgery of the Ear and Skull Base*. New York, Raven Press, 1982, pp 175–180.
3. Atkinson WJ: The anterior inferior cerebellar artery: Its variations, pontine distribution, and significance in the surgery of cerebello-pontine angle tumours. *J Neurol Neurosurg Psychiatry* 12:137– 151,

1949.

4. Dandy WE: Glossopharyngeal neuralgia (tic douloureux): Its diagnosis and treatment. *Arch Surg* 15:198–214, 1927.
5. Dandy WE: An operation for the cure of tic douloureux: Partial section of the sensory root at the pons. *Arch Surg* 18:687–734, 1929.
6. Dandy WE: Concerning the cause of trigeminal neuralgia. *Am J Surg* 24:447–455, 1934.
7. DuBois FS, Foley JO: Experimental studies on the vagus and spinal accessory nerves in the cat. *Anat Rec* 64:285–307, 1936.
8. Emmons WF, Rhoton AL Jr: Subdivision of the trigeminal sensory root: Experimental study in the monkey. *J Neurosurg* 35:585–591, 1971.
9. Fein JM, Frishman W: Neurogenic hypertension related to vascular compression of the lateral medulla. *Neurosurgery* 6:615–622, 1980.
10. Fujii K, Lenkey C, Rhoton AL Jr: Microsurgical anatomy of the choroidal arteries: Fourth ventricle and cerebellopontine angles. *J Neurosurg* 52:504–524, 1980.
11. Gardner WJ: Concerning the mechanism of trigeminal neuralgia and hemifacial spasm. *J Neurosurg* 19:947–958, 1962.
12. Gudmundsson K, Rhoton AL Jr, Rushton JG: Detailed anatomy of the intracranial portion of the trigeminal nerve. *J Neurosurg* 35:592–600, 1971.
13. Hardy DG, Rhoton AL Jr: Microsurgical relationships of the superior cerebellar artery and the trigeminal nerve. *J Neurosurg* 49:669–678, 1978.
14. Hardy DG, Peace DA, Rhoton AL Jr: Microsurgical anatomy of the superior cerebellar artery. *Neurosurgery* 6:10–28, 1980.
15. Horsley V, Taylor J, Coleman WS: Remarks on the various surgical procedures devised for the relief or cure of trigeminal neuralgia (tic douloureux). *Br Med J* 2:1139–1143, 1191–1193, 1249–1252,

1891.

16. House WF: Translabyrinthine approach, in House WF, Luetje CM (eds): *Acoustic Tumors: II—Management*. Baltimore, University Park Press, 1979, pp 43–87.
17. Jannetta PJ: Arterial compression of the trigeminal nerve at the pons in patients with trigeminal neuralgia. *J Neurosurg* 26:159–162, 1967.
18. Jannetta PJ: Vascular decompression in trigeminal neuralgia, in Samii M, Jannetta PJ (eds): *The Cranial Nerves: Anatomy, Pathology, Pathophysiology, Diagnosis, Treatment*. New York, Springer-Verlag, 1981, pp 331–340.
19. Jannetta PJ, Gendell HM: Clinical observations on etiology essential hypertension. *Surg Forum* 30:431–432, 1979.
20. Jannetta PJ, Abbasy M, Maroon JC, Ramos FM, Albin MS: Etiology and definitive microsurgical treatment of hemifacial spasm: Operative techniques and results in 47 patients. *J Neurosurg* 47:321–328, 1977.
21. Jannetta PJ, Moller MB, Møller AR, Sekhar LN: Neurosurgical treatment of vertigo by microvascular decompression of the eighth cranial nerve. *Clin Neurosurg* 33:645–665, 1986.
22. Katsuta T, Rhoton AL Jr, Matsushima T: The jugular foramen: Microsurgical anatomy and operative approaches. *Neurosurgery* 41:149–202, 1997.
23. Laha RK, Jannetta PJ: Glossopharyngeal neuralgia. *J Neurosurg* 47:316–320, 1977.
24. Lister JR, Rhoton AL Jr, Matsushima T, Peace DA: Microsurgical anatomy of the posterior inferior cerebellar artery. *Neurosurgery* 10:170–199, 1982.
25. Martin RG, Grant JL, Peace DA, Theiss C, Rhoton AL Jr: Microsurgical relationships of the anterior inferior cerebellar artery and the facial- vestibulocochlear nerve complex. *Neurosurgery* 6:483–507, 1980.

26. Matsushima T, Rhoton AL Jr, de Oliveira E, Peace DA: Microsurgical anatomy of the veins of the posterior fossa. *J Neurosurg* 59:63–105, 1983.
27. Matsushima T, Rhoton AL Jr, Lenkey C: Microsurgery of the fourth ventricle: Part I—Microsurgical anatomy. *Neurosurgery* 11:631–667, 1982.
28. Møller MB, Møller AR, Jannetta PJ, Sekhar L: Diagnosis and surgical treatment of disabling positional vertigo. *J Neurosurg* 64:21–28, 1986.
29. Ouaknine GE, Robert F, Molina-Negro P, Hardy J: Geniculate neuralgia and audio-vestibular disturbances due to compression of the intermediate and eighth nerves by the postero-inferior cerebellar artery. *Surg Neurol* 13:147–150, 1980.
30. Pait TG, Zeal A, Harris FS, Paullus WS, Rhoton AL Jr: Microsurgical anatomy and dissection of the temporal bone. *Surg Neurol* 8:363–391, 1977.
31. Pelletier V, Poulos DA, Lende RA: Localization in the trigeminal root. Presented at the American Association of Neurological Surgeons, Washington, DC, 1970.
32. Rhoton AL Jr: Microsurgery of the internal acoustic meatus. *Surg Neurol* 2:311–318, 1974.
33. Rhoton AL Jr: Microsurgical anatomy of the brainstem surface facing an acoustic neuroma. *Surg Neurol* 25:326–339, 1986.
34. Rhoton AL Jr: Microsurgical anatomy of decompression operations on the trigeminal nerve, in Rovit RL, Murali R, Jannetta PJ (eds): *Trigeminal Neuralgia*. Baltimore, Williams & Wilkins, 1990, pp 165–200.
35. Rhoton AL Jr: Microsurgical anatomy of acoustic neuromas, in Jackler RK (ed): *Otolaryngologic Clinics of North America*. Philadelphia, W.B. Saunders Co., 1992, pp 257–294.
36. Rhoton AL Jr: Instrumentation, in Apuzzo MLJ (ed): *Brain Surgery: Complication, Avoidance and Management*. New York, Churchill

Livingstone, 1993, pp 1647–1670.

37. Rhoton AL Jr: Microsurgical anatomy of acoustic neuromas, in Sekhar LN, Janecka IP (eds): *Surgery of Cranial Base Tumors*. New York, Raven Press, 1993, pp 687–713.
38. Rhoton AL Jr: Microsurgical anatomy of posterior fossa cranial nerves, in Barrow DL (ed): *Surgery of the Cranial Nerves of the Posterior Fossa: Neurosurgical Topics*. Park Ridge, AANS, 1993, pp 1–103.
39. Rhoton AL Jr, Buza R: Microsurgical anatomy of the jugular foramen. *J Neurosurg* 42:541–550, 1975.
40. Rhoton AL Jr, Kobayashi S, Hollingshead WH: Nervus intermedius. *J Neurosurg* 29:609–618, 1968.
41. Segal R, Gendell HM, Canfield D, Dujovny M, Jannetta PJ: Cardiovascular response to pulsatile pressure applied to ventrolateral medulla. *Surg Forum* 30:433–435, 1979.
42. Seoane ER, Rhoton AL Jr: Suprameatal extension of the retrosigmoid approach: Microsurgical anatomy. *Neurosurgery* 44:553–560, 1999.
43. Sunderland S: Neurovascular relationships and anomalies at the base of the brain. *J Neurol Neurosurg Psychiatry* 11:243–257, 1948.
44. Tarlov IM: Structure of the nerve root: Part II—Differentiation of sensory from motor roots: Observations on identification of function in roots of mixed cranial nerves. *Arch Neurol Psychiatry* 37:1338–1355, 1937.
45. Tarlov IM: Section of the cephalic third of the vagus-spinal accessory complex: Clinical and histologic results. *Arch Neurol Psychiatry* 47:141–148, 1942.
46. Watt JC, McKillop AN: Relation of arteries to roots of nerves in posterior cranial fossa in man. *Arch Surg* 30:336–345, 1935.